



**PATIENT**

Bingo Proffitt

**SPECIES**

Canine

**BREED**

JRT Mix

**SEX**

Neutered Male

**AGE**

15 Years 4 Months

**WEIGHT**

24.4 Pounds

**INTERPRETED BY**

Eric Lindquist, DMV,  
DABVP (CFM), Cert.  
IVUSS

**IMAGING PERFORMED BY**

Shari Reffi, CVT

**HOSPITAL NAME**

Legacy AH

**REFERRING VET**

Dr. Potenzzone

**INVOICE**

35371

**DATE**

1/12/26

**PRESENTING CLINICAL SIGNS**

History: Hepatopathy, enl. liver, anxiety, pu/pd. R/O Cushings vs meds vs age vs other. Current meds: Denamarin, Carporfen, Gabapentin , (torb for scan).

Abnormal PE/Chem/CBC/UA Results: ALT 194; ALP 1088; acth stim neg 3/25

**ULTRASONOGRAPHIC EXAMINATION OF THE ABDOMEN**

**Urinary System**

The **urinary bladder**, trigone, and pelvic urethra presented normal thicknesses and normal tone. The ureters were not visible which is normal. No uroliths or sediment were visualized and anechoic urine was present. No evidence of inflammatory or neoplastic changes was noted. Ureteral papillae were normal. The residual prostate was uniform, measuring 0.77 cm. The pelvic urethra was imaged 3.0 cm beyond the cystourethral junction.

The **kidneys** revealed largely normal size and structure, corticomedullary definition and ratio (cortex 1/3 of medulla) were essentially maintained with some mild age-related loss of curvilinear patterns regarding the capsule and C/M junction. The cortices presented largely uniform texture with some increased echogenicity expected for this age patient. Medullary structure differed distinctly from that of the cortex and no evidence of pelvic dilation was present. The left kidney measured 4.4 cm. The right kidney measured 4.62 cm.

**Adrenal Glands**

Both **adrenal glands** were visualized and recognized as having normal shape, size, position and echogenicity for this breed. The phrenic vasculature, glandular echogenicity and detail were unremarkable. Capsule, cortex, and medullary definition were normal for this age patient. The right adrenal gland measured 1.23 cm at the cranial pole and 0.59 cm at the caudal pole. The left adrenal gland measured 0.46 cm at the caudal pole and 0.43 cm at the cranial pole.

**Spleen**

The **spleen** presented a smooth homogeneous parenchyma hyperechoic to liver and renal cortical parenchyma. The capsule was smooth without noticeable expansion or deviation from within the spleen or adjacent pathology. The splenic vasculature demonstrated normal volume without signs of congestion or thrombosis. No sonographic evidence of acute or chronic inflammatory, neoplastic, or infarctual changes were noted. A hyperechoic lipid plaque was noted, measuring 0.8 cm.

**Liver**

The **liver** was uniformly swollen with minor, excessive gallbladder debris and over distension with dependent and suspended bile without evidence of overt mucocele formation. However, excessive sludge was present. The liver presented coarse architecture with mildly increased portal markings and subtle, mixed echogenic changes. This is consistent with vacuolar hepatopathy and some level of remodeling and history of inflammatory component. There was no overt suspicion of neoplasia. This is a moderate change.

**Gastrointestinal**



**PATIENT**

Bingo Proffitt

**SPECIES**

Canine

**BREED**

JRT Mix

**SEX**

Neutered Male

**AGE**

15 Years 4 Months

**WEIGHT**

24.4 Pounds

**INTERPRETED BY**

Eric Lindquist, DMV,  
DABVP (CFM), Cert.  
IUUSS

**IMAGING PERFORMED BY**

Shari Reffi, CVT

**HOSPITAL NAME**

Legacy AH

**REFERRING VET**

Dr. Potenzzone

**INVOICE**

35371

**DATE**

1/12/26

Examination of the **gastrointestinal tract** revealed a stomach and intestine free of stasis, of normal wall thickness, acceptable curvilinear mural detail, and peristaltic activity. Small and large intestine demonstrated normal luminal chyme and stool consistency respectively. No obstructive or overt infiltrative disease was noted. No associated abnormal lymphatic activity was noted.

**Pancreas**

The base and limbs of the **pancreas** were observed to be largely isoechoic to surrounding omental fat. Pancreatic duct and capsular contour were acceptably normal and parenchyma respected normal curvilinear patterns. No overt evidence of active inflammatory or neoplastic disease was noted.

**Other**

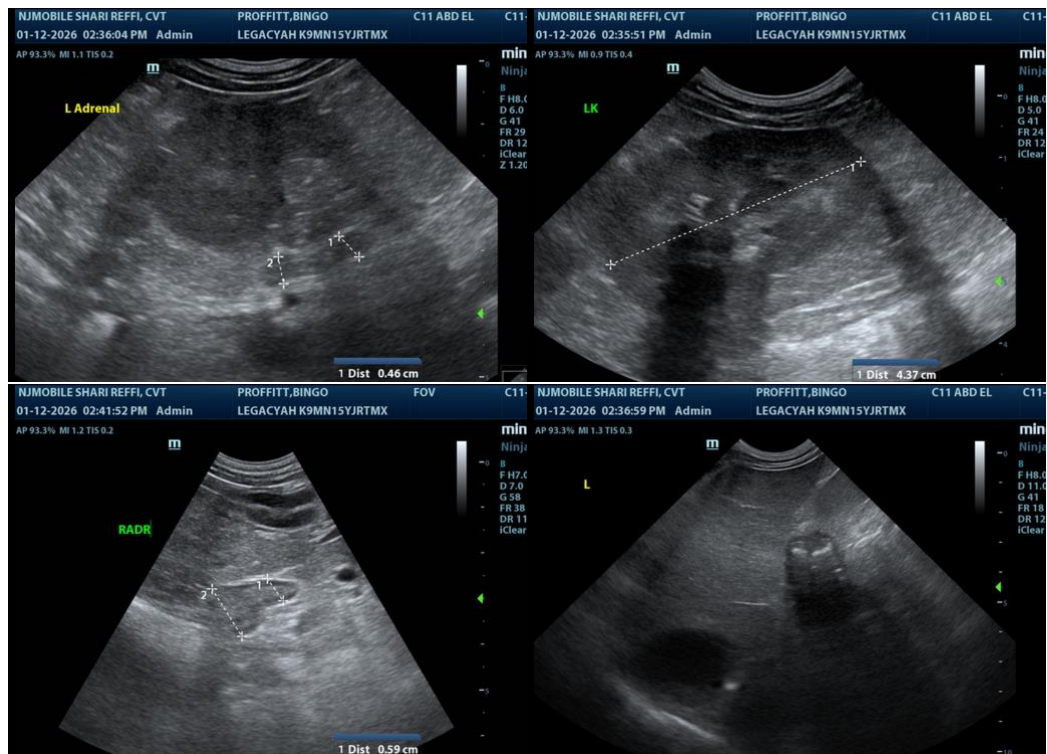
A rapid view of the **heart** revealed no evident pathology in the right auricle pr pericardium.

**ULTRASONOGRAPHIC FINDINGS**

- Lipid plaque in the spleen
- Benign hepatopathy
- Age-related changes otherwise

**INTERPRETATION OF THE FINDINGS & FURTHER RECOMMENDATIONS**

No evidence of significant clinical disease.





**PATIENT**

Bingo Proffitt

**SPECIES**

Canine

**BREED**

JRT Mix

**SEX**

Neutered Male

**AGE**

15 Years 4 Months

**WEIGHT**

24.4 Pounds

**INTERPRETED BY**

Eric Lindquist, DMV,  
DABVP (CFM), Cert.  
IVUSS

**IMAGING PERFORMED BY**

Shari Reffi, CVT

**HOSPITAL NAME**

Legacy AH

**REFERRING VET**

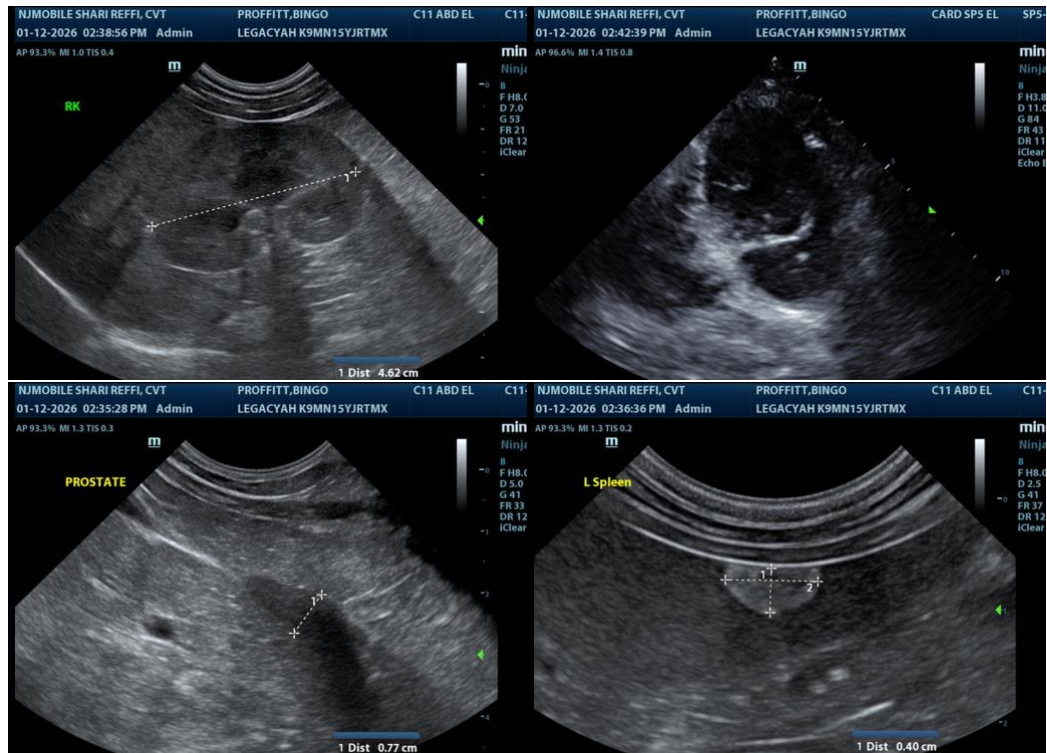
Dr. Potenzzone

**INVOICE**

35371

**DATE**

1/12/26



**The information and recommendations provided are based on the images presented by the referring veterinarian/sonographer. No evaluation can be communicated regarding pathology that was not visible in the image/video clips provided.**

Thank you for this referral. If the clinical or image interpretation does not parallel your findings or if I can be of any further assistance please contact me.

**Eric Lindquist**, DMV, DABVP(CFM), Cert. IVUSS,  
CEO, Owner, Founder -- SonoPath.com  
[info@SonoPath.com](mailto:info@SonoPath.com)