



PATIENT

Lexi Bloser

SPECIES

Canine

BREED

Black Mouth Cur

SEX

Spayed Female

AGE

12 Years

WEIGHT

26.7 kg

INTERPRETED BY

Eric Lindquist, DMV

DABVP, Cert. IVUSS

IMAGING PERFORMED BY

Dr. Laura de Cordon

HOSPITAL NAME

Mason Dixon Animal
Emergency Hospital

REFERRING VET

Dr. Laura de Cordon

INVOICE

44154

DATE

1/12/23

PRESENTING CLINICAL SIGNS

Several day history of not inappetence, vomiting, and lethargy. 6 pound weight loss in the last month. History of eating socks. No bowel movements for at least the last 3 days. Last meal was 2 days ago.

Abnormal PE/Chem/CBC/UA Results: Thrombocytosis. Cranial abdomen large soft tissue density. Plicated bowel pattern with radiopaque density in cranial small bowel on lateral and string like strands of foreign material in caudal bowel loops. BUN 35. SDMA 18. Phos 6.2. Chol 555. ALT 308. ALP 803. GGT 43. Tbil 0.4

ULTRASONOGRAPHIC EXAMINATION OF THE ABDOMEN

Urinary System

The **urinary bladder**, trigone, and pelvic urethra presented normal thicknesses and normal tone. The ureters were not visible which is normal. No uroliths or sediment were visualized and anechoic urine was present. No evidence of inflammatory or neoplastic changes were noted. Ureteral papillae were normal.

The **kidneys** revealed largely normal size and structure, corticomedullary definition and ratio (cortex 1/3 of medulla) were essentially maintained with some age-related loss of curvilinear patterns regarding the capsule and C/M junction. The cortices presented largely uniform texture with some increased echogenicity expected for his age patient. Medullary structure differed distinctly from that of the cortex and no evidence of pelvic dilation was present. The left kidney measures 6.0 cm. The right kidney measures 7.3 cm.

Adrenal Glands

The **left adrenal gland** was slightly enlarged and mildly heterogeneous, measuring up to 1.1 cm.

Spleen & liver

The **liver** revealed a left-sided parenchymal mass measuring 5.0 cm. The gallbladder was unremarkable. A large cranial abdominal mass was noted measuring 10+ cm. The mass appeared to be deriving from the liver. However, I cannot rule out the possibility of a connection to the spleen.

Gastrointestinal

The **stomach** in this patient revealed a large amount of gastric foreign matter continuing into the small intestine. Variable gastrointestinal thickening present. A large amount of stasis present. Intestinal plication noted owing to intestinal foreign body. The foreign matter within the stomach appeared to enter the gastroesophageal inlet. Regional inflammation noted around the upper GI tract.

Pancreas

The base and limbs of the **pancreas** were observed to be largely isoechoic to surrounding omental fat. Pancreatic duct and capsular contour were acceptably normal and parenchyma respected normal curvilinear patterns. No overt evidence of active inflammatory or neoplastic disease was noted.

ULTRASONOGRAPHIC FINDINGS

- Gastric and intestinal foreign bodies, possible attachment to the base of the tongue
- Significant reactive mesentery
- Hepatic mass/masses and separate cranial abdominal mass, possible splenic or hepatic origin



PATIENT

Lexi Bloser

SPECIES

Canine

BREED

Black Mouth Cur

SEX

Spayed Female

AGE

12 Years

WEIGHT

26.7 kg

INTERPRETED BY

Eric Lindquist, DMV

DABVP, Cert. IVUSS

IMAGING PERFORMED BY

Dr. Laura de Cordon

HOSPITAL NAME

Mason Dixon Animal
Emergency Hospital

REFERRING VET

Dr. Laura de Cordon

INVOICE

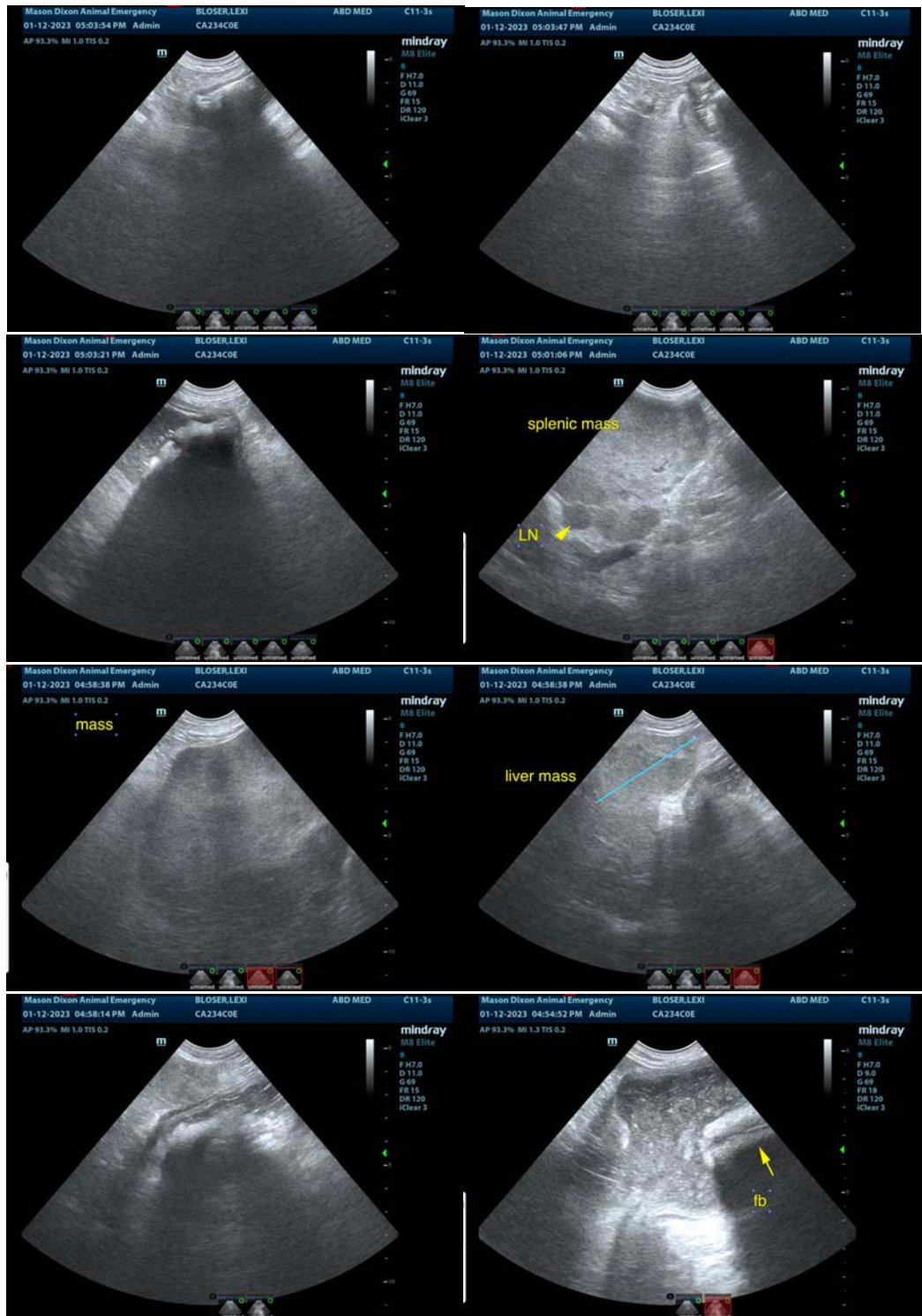
44154

DATE

1/12/23

INTERPRETATION OF THE FINDINGS & FURTHER RECOMMENDATIONS

At sedation, oral examination recommended to assess for attachment at the base of the tongue, followed by gastrotomy. Prognosis is poor.





PATIENT

Lexi Blaser

SPECIES

Canine

BREED

Black Mouth Cur

SEX

Spayed Female

AGE

12 Years

WEIGHT

26.7 kg

INTERPRETED BY

Eric Lindquist, DMV

DABVP, Cert. IVUSS

IMAGING PERFORMED BY

Dr. Laura de Cordon

HOSPITAL NAME

Mason Dixon Animal
Emergency Hospital

REFERRING VET

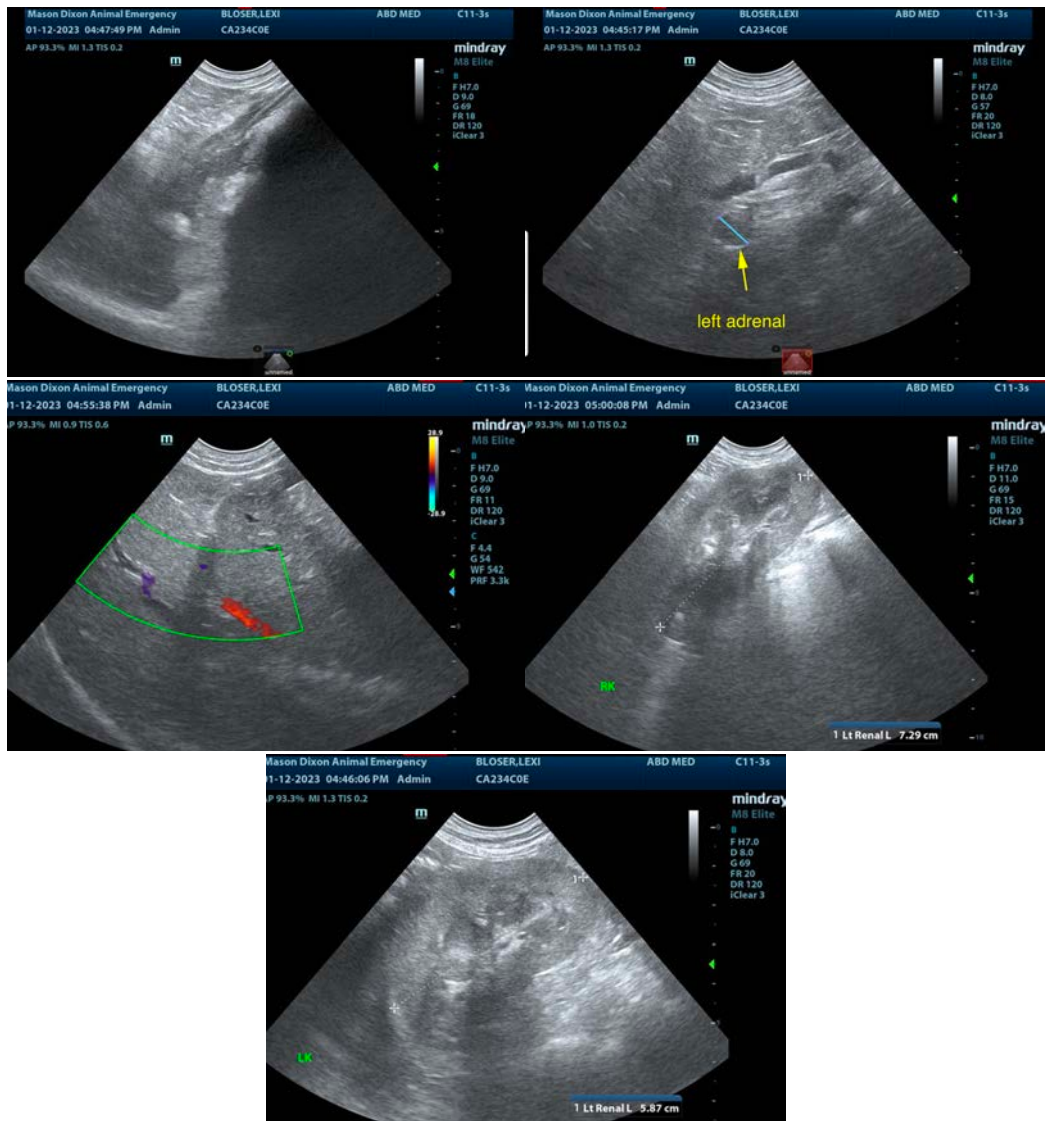
Dr. Laura de Cordon

INVOICE

44154

DATE

1/12/23



The information and recommendations provided are based on the images presented by the referring veterinarian/sonographer. No evaluation can be communicated regarding pathology that was not visible in the image/video clips provided.

Thank you for this referral. If the clinical or image interpretation does not parallel your findings or if I can be of any further assistance please contact me.

Eric Lindquist, DMV, DABVP, Cert. IVUSS, CEO of SonoPath.com

info@SonoPath.com