



PATIENT

Brownie Menell

SPECIES

Canine

BREED

Dachshund X

SEX

Neutered Male

AGE

15 Years 4 Months

WEIGHT

19.34

INTERPRETED BY

Eric Lindquist, DMV

DABVP, Cert. IVUSS

IMAGING PERFORMED BY

Dr. Ruth Loomis

HOSPITAL NAME

Brookwood AC

REFERRING VET

Dr. Ruth Loomis

INVOICE

44237

DATE

1/12/23

PRESENTING CLINICAL SIGNS

PU/PD

Abnormal PE/Chem/CBC/UA Results: USG 1.016 (checked last in November) Alkp 141 BUN 32

ULTRASONOGRAPHIC EXAMINATION OF THE ABDOMEN

Urinary System

The **bladder** in this patient was mildly thickened with slight echogenic mural changes. No calculi or masses were noted. Slight micropolypoid changes were noted. This is a frequent finding in older animals and may be linked to a history of chronic urinary tract infection or active urinary tract infection. Urinalysis would be recommended with culture if any evidence of inflammatory sediment is present. The region of the trigone and visible pelvic urethra were normal. The pelvic urethra was imaged 3.0 cm beyond the cystourethral junction.

The **kidneys** revealed largely normal size and structure, corticomedullary definition and ratio (cortex 1/3 of medulla) were essentially maintained with some age-related loss of curvilinear patterns regarding the capsule and C/M junction. The cortices presented largely uniform texture with some increased echogenicity expected for his age patient. Medullary structure differed distinctly from that of the cortex and no evidence of pelvic dilation was present. The left kidney measured 4.0 cm. The right kidney measured 4.0 cm.

Adrenal Glands

Both **adrenal glands** were visualized and recognized as having normal shape, size, position and echogenicity for this breed. The phrenic vasculature, glandular echogenicity and detail were unremarkable. Capsule, cortex, and medullary definition were normal for this age patient. The left adrenal gland measured 0.66 cm at the caudal pole and 0.55 cm at the cranial pole. The right adrenal gland measured 0.88 cm at the cranial pole and 0.63 cm at the caudal pole.

Spleen

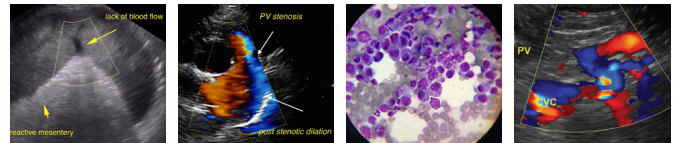
The **spleen** presented a smooth homogeneous parenchyma hyperechoic to liver and renal cortical parenchyma. The capsule was smooth without noticeable expansion or deviation from within the spleen or adjacent pathology. The splenic vasculature demonstrated normal volume without signs of congestion or thrombosis. No sonographic evidence of acute or chronic inflammatory, neoplastic, or infarctual changes were noted.

Liver

The **liver** images from right and left intercostal as well as subcostal views revealed subjectively normal liver size, contour, and structure. Some age-related parenchymal remodeling was noted but likely not clinically significant at this time. A 4.0 cm irregular, hyperechoic, mildly disruptive nodule or mass was noted in the left cranial liver. Vascular and biliary tracts were of normal volume and no evidence of congestion was noted. The gallbladder presented some dependent debris with essentially normal contour. The cystic and common bile ducts were normal.

Gastrointestinal

Examination of the **gastrointestinal tract** revealed a stomach and intestine free of stasis, of normal wall thickness, acceptable curvilinear mural detail, and peristaltic activity. Small and large intestine demonstrated normal luminal chyme and stool consistency respectively. No obstructive or overt infiltrative disease was noted. No associated abnormal lymphatic activity was noted.



PATIENT

Brownie Menell

SPECIES

Canine

BREED

Dachshund X

SEX

Neutered Male

AGE

15 Years 4 Months

WEIGHT

19.34

INTERPRETED BY

Eric Lindquist, DMV

DABVP, Cert. IVUSS

IMAGING PERFORMED BY

Dr. Ruth Loomis

HOSPITAL NAME

Brookwood AC

REFERRING VET

Dr. Ruth Loomis

INVOICE

44237

DATE

1/12/23

Pancreas

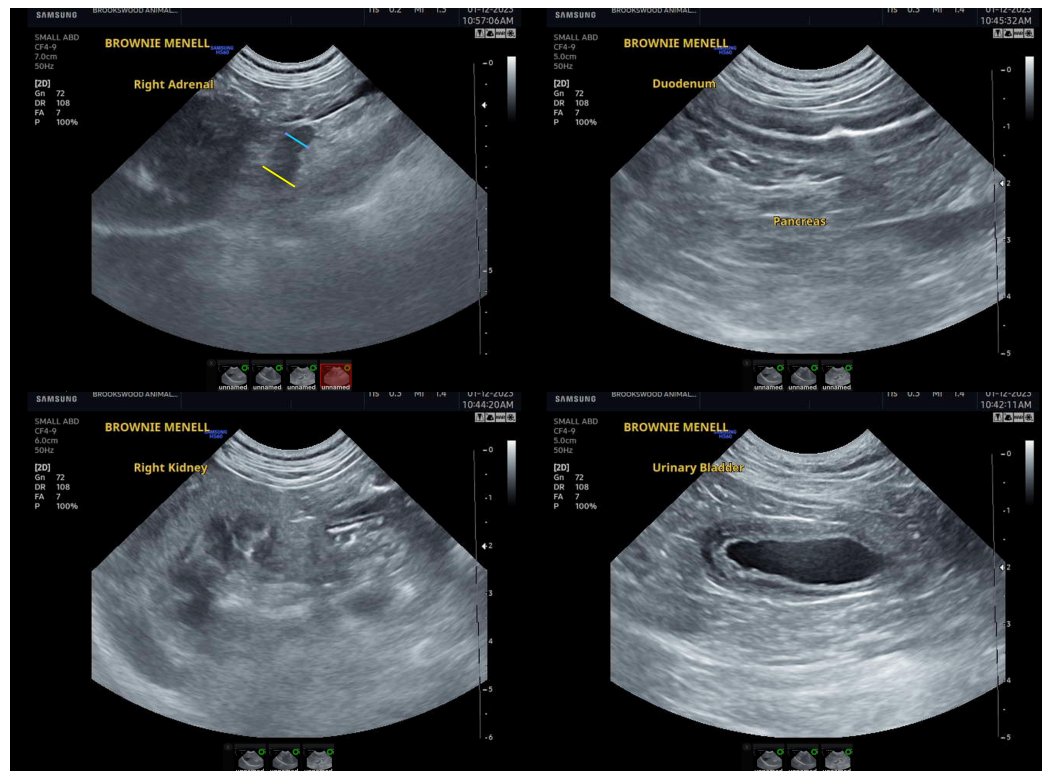
The base and limbs of the **pancreas** were observed to be largely isoechoic to surrounding omental fat. Some parenchymal remodeling, however, with mild deviation from curvilinear normalcy was observed. Pancreatic duct and capsular irregularities were present consistent with age related changes. If pain upon imaging (+ Murphy sign) was present or if the patient is focally painful in subxyphoid palpation then low-grade smoldering chronic pancreatitis should be suspected.

ULTRASONOGRAPHIC FINDINGS

- Geriatric abdomen with undefined hepatic nodule/mass

INTERPRETATION OF THE FINDINGS & FURTHER RECOMMENDATIONS

Technically the hepatic nodule is a mass, given its size. FNA indicated. Low-grade carcinoma versus hyperplasia are primary concerns. Geriatric abdomen otherwise. The kidneys do not appear end stage. Geriatric diet and full urinary workup indicated, given the azotemia. If any inflammatory sediment is present, coverage for UTI indicated.





PATIENT

Brownie Menell

SPECIES

Canine

BREED

Dachshund X

SEX

Neutered Male

AGE

15 Years 4 Months

WEIGHT

19.34

INTERPRETED BY

Eric Lindquist, DMV

DABVP, Cert. IVUSS

IMAGING PERFORMED BY

Dr. Ruth Loomis

HOSPITAL NAME

Brookwood AC

REFERRING VET

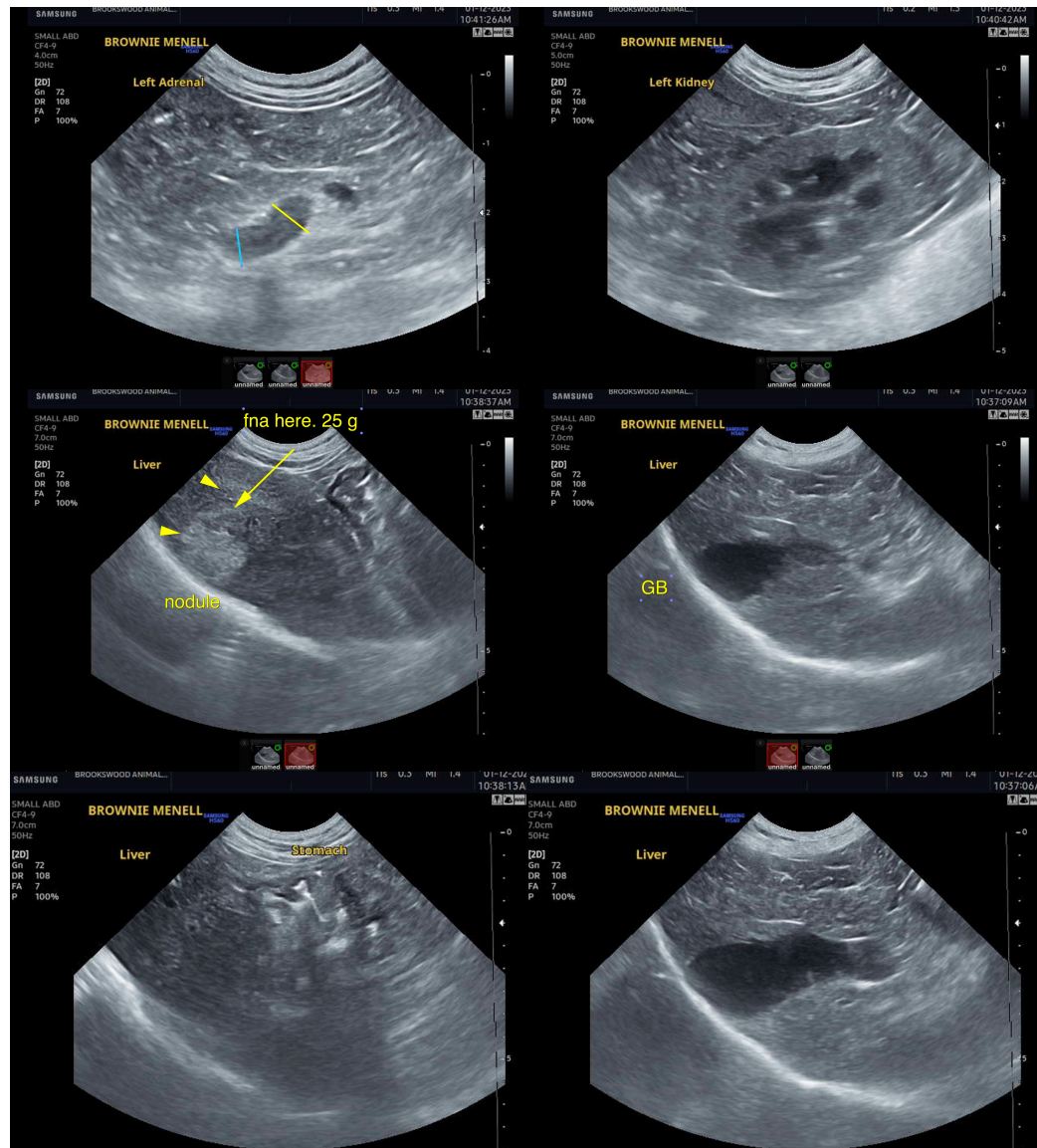
Dr. Ruth Loomis

INVOICE

44237

DATE

1/12/23



The information and recommendations provided are based on the images presented by the referring veterinarian/sonographer. No evaluation can be communicated regarding pathology that was not visible in the image/video clips provided.

Thank you for this referral. If the clinical or image interpretation does not parallel your findings or if I can be of any further assistance please contact me.

Eric Lindquist, DMV, DABVP, Cert. IVUSS, CEO of SonoPath.com

info@SonoPath.com