



**PATIENT PRESENTING CLINICAL SIGNS**

Ruby Nigro Trouble breathing- cardiac vs possible mass in lung; on gabapentin, prednisone, tramadol, lasix.  
Abnormal PE/Chem/CBC/UA Results: ALKP 1344, gluc 60, PSL 291

**SPECIES**

Canine

**BREED**

Pit Cross

**SEX**

Spayed Female

**AGE**

14 years

**WEIGHT**

62 lbs

**INTERPRETED BY**

Eric Lindquist, DMV  
DABVP, Cert. IVUSS

**IMAGING PERFORMED BY**

Diane McFadden, RVT

**HOSPITAL NAME**

Companion AH

**INVOICE**

95154

**DATE**

1/11/22

**ULTRASONOGRAPHIC EXAMINATION OF THE HEART**

The echocardiogram in this patient demonstrated normal **left atrial** size based on 3 separate methods of LA evaluation. The cranial and caudal **mitral** valve leaflets presented normal linear structure, extension in systole, and union in diastole with normal kinesis. The **left ventricle** presented thicknesses with linear contour and was not dilated nor restricted. The **myocardium** presented normal echogenicity without subjective evidence of significant fibrotic or ischemic disease. **Contractility** of the ventricular walls was adequate and in normal range for this patient evidenced by the fractional shortening measurement and subjective evaluation of the different regions of the myocardium. The **left ventricular outflow** tract demonstrated normal laminar flow and subjective structural integrity. The **right atrium** and auricle revealed normal size, structure and content. No evidence of masses was noted. **Tricuspid** valvular assessment demonstrated adequate linear morphology and kinesis. The **right ventricle** was of normal size (1/3 diameter of LV), chordae structure, myocardial echogenicity and thickness. **Pulmonary outflow** tract assessment revealed normal valve structure, laminar flow, and diameter (approx.1:1 pa/ao ratio). No visible **pericardial** or free pleura fluid was noted. The cranial **mediastinum and pericardial and extra-cardiac regions** were free of masses in the visible window. Occasional arrhythmia was noted in this patient. Rapid view of the liver revealed biliary calculi that were non-obstructive.

CANINE	MR	TR	LA/AO	LA/AO	FS	EF	EPSS
<b>CARDIAC PARAMETERS</b>	<b>VMAX</b> (m/s)	<b>VMAX</b> (m/s)	(Boon method)	(Heart Base; Swe)	(%)	(%)	(cm)
<b>NORMAL PARAMETER</b>	4.5-5.5	<2.7	1.3	<1.6	28-40	40-100	<0.6
<b>PATIENT</b>			1.13	1.18			0.1
CANINE	HR	AV	PV	BODY WEIGHT	LA	LVIDd	LVIDs
<b>CARDIAC PARAMETERS</b>	(BPM)	<b>VMAX</b> (m/s)	<b>MAX</b> (m/s)		2D short axis Base view (cm)	Avg; 2D and m-mode short axis (cm)	Avg; 2D and m-mode short axis (cm)
<b>NORMAL PARAMETER</b>	50-100	0.7-1.7	0.7-1.6				
<b>PATIENT</b>		1.6	0.9	65 lbs	4.3 max		

**ULTRASONOGRAPHIC FINDINGS**

Normal echocardiogram. No volume overload.  
Occasional arrhythmia.  
Biliary calculi.



**PATIENT**

Ruby Nigro

**INTERPRETATION OF THE FINDINGS & FURTHER RECOMMENDATIONS**

EKG is indicated. The heart is normal from a functional and structural standpoint. Respiratory signs are non-cardiogenic. Primary respiratory disease or pain related disease should be considered.

**SPECIES**

Canine

**BREED**

Pit Cross

**SEX**

Spayed Female

**AGE**

14 years

**WEIGHT**

62 lbs

**INTERPRETED BY**

Eric Lindquist, DMV  
DABVP, Cert. IVUSS

**IMAGING PERFORMED BY**

Diane McFadden, RVT

**HOSPITAL NAME**

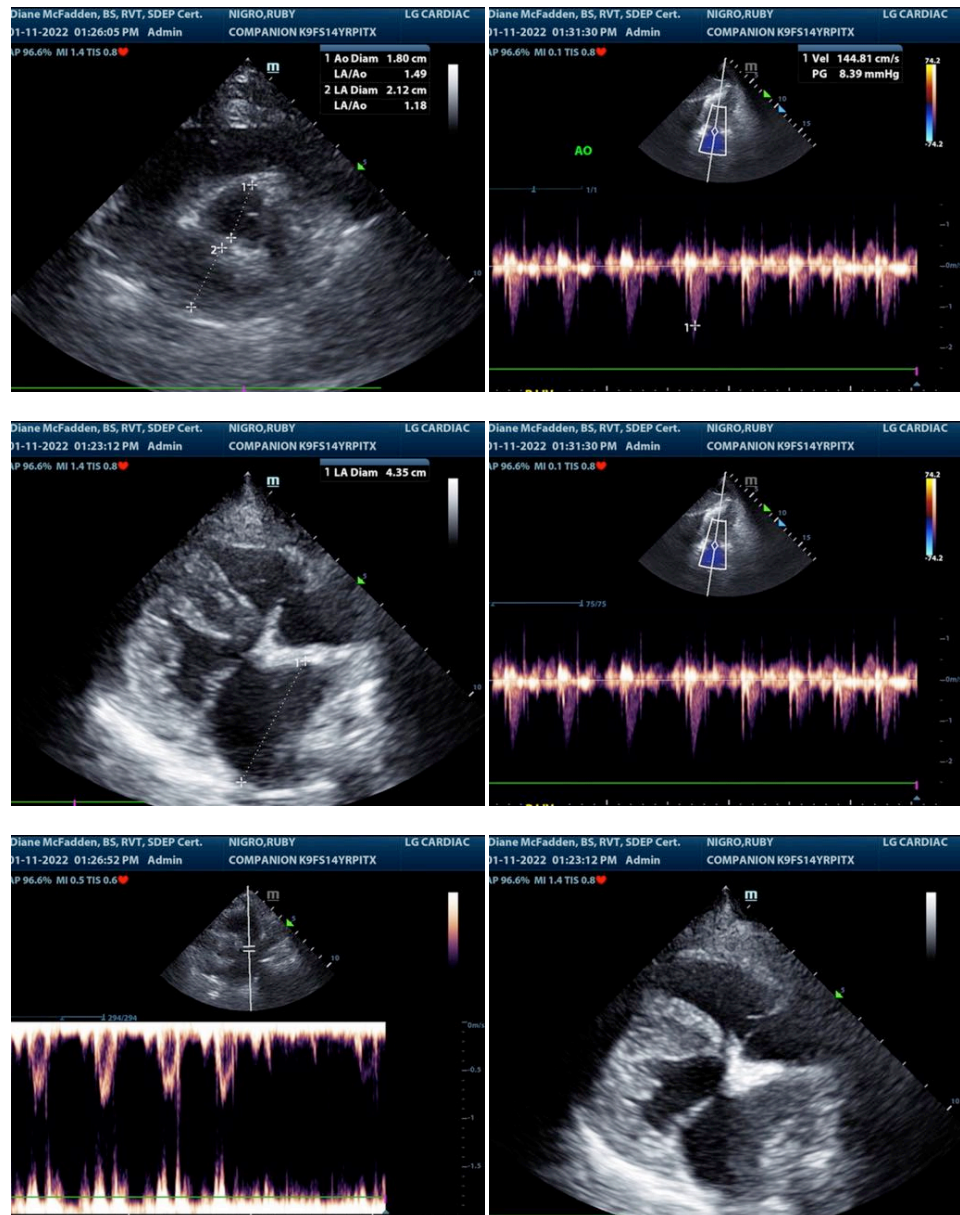
Companion AH

**INVOICE**

95154

**DATE**

1/11/22





**PATIENT**

Ruby Nigro

**SPECIES**

Canine

**BREED**

Pit Cross

**SEX**

Spayed Female

**AGE**

14 years

**WEIGHT**

62 lbs

**INTERPRETED BY**

Eric Lindquist, DMV  
DABVP, Cert. IVUSS

**IMAGING  
PERFORMED BY**

Diane McFadden, RVT

**HOSPITAL NAME**

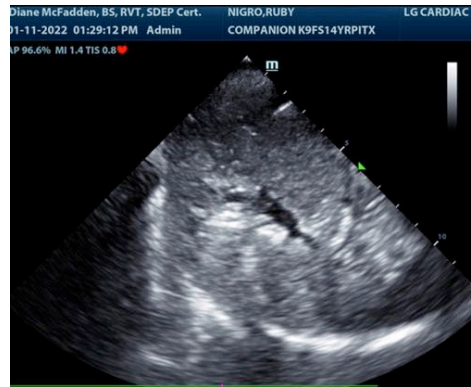
Companion AH

**INVOICE**

95154

**DATE**

1/11/22



The information and recommendations provided are based on the images presented by the referring veterinarian. No evaluation can be communicated regarding pathology that was not visible in the image/video clips provided.

Thank you for this referral. If the clinical or image interpretation does not parallel your findings or if I can be of any further assistance please contact me.

**Eric Lindquist**, DMV, DABVP, Cert. IVUSS, CEO of SonoPath.com  
Info@SonoPath.com