



**DATE PRESENTING CLINICAL SIGNS**

1/10/26

Patient History: CBC is normal - recommend checking resting cortisol to r/o atypical Addison's since no stress leukogram. ALT is mildly elevated - r/o secondary to patient's history of elevated ALT vs. newly elevated again; r/o primary vs. reactive hepatopathy. cPL is normal which rules out pancreatitis at this time. Reviewed radiology report and radiographs with owner. Normal thorax. Satisfactory emptying of the stomach without evidence of mechanical small intestinal obstruction or radiopaque foreign material. Distension of urinary bladder is likely due to voluntary retention rather than lower urinary tract obstruction - owner stated that patient typically holds her bladder for long periods of time (patient did urinate at time of admission).

**PATIENT**

Tinker San Augustin

**SPECIES**

Canine

Current Medications: N/A.

**BREED**

Bichon Frise

Labwork Results: Labwork submitted  
Date of Previous IntraPet Ultrasound: No previous.  
Sedation: Sedated with Dexdomitor.  
Stat Report: DVM requested.  
Imaging Performed by: Andi Parkinson, BS, RDMS.

**SEX**

Spayed Female

**ULTRASONOGRAPHIC EXAMINATION OF THE ABDOMEN**

**AGE**

2/14/23

**Urinary System**

The **urinary bladder**, trigone, and pelvic urethra presented normal thicknesses and normal tone. The ureters were not visible which is normal. No uroliths or sediment were visualized and anechoic urine was present. No evidence of inflammatory or neoplastic changes was noted. Ureteral papillae were normal.

**WEIGHT**

6.2 kg

The **kidneys** revealed normal size and structure, corticomedullary definition and ratio for this age. The cortices presented largely uniform texture with normal echogenic relationship to liver and spleen. Medullary structure differed distinctly from the cortex, and no evidence of pelvic dilation was present. The capsules were acceptably uniform without significant irregularities. The left kidney measured 4.2 cm. The right kidney measured 4.2 cm.

**INTERPRETED BY**

Eric Lindquist, DMV,  
DABVP (CFM), Cert.  
IVUSS

**Adrenal Glands**

**HOSPITAL NAME**

Mason Dixon AEH

Both **adrenal glands** were visualized and recognized as having normal shape, size, position and echogenicity for this breed. The phrenic vasculature, glandular echogenicity and detail were unremarkable. Capsule, cortex, and medullary definition were normal for this age patient. The right adrenal gland measured 1.15 cm at the cranial pole and 0.37 cm at the caudal pole. The left adrenal gland measured 1.6 cm x 0.34 cm at the cranial pole and 0.45 cm at the caudal pole.

**REFERRING VET**

Dr. Grove

**Spleen**

The **spleen** presented a smooth homogeneous parenchyma hyperechoic to liver and renal cortical parenchyma. The capsule was smooth without noticeable expansion or deviation from within the spleen or adjacent pathology. The splenic vasculature demonstrated normal volume without signs of congestion or thrombosis. No sonographic evidence of acute or chronic inflammatory, neoplastic, or infarctual changes were noted.

**INVOICE**

35344

**Liver**

The **liver** was subnormal in size with slight increased portal markings. The gallbladder revealed edematous wall, measuring 0.3 cm. No evidence of posthepatic obstruction.

### ***Gastrointestinal***

The **stomach** was overdistended with chyme, consistent with ileus. The pylorus was patent. Some hyperperistaltic small intestine was noted. The ileocecal junction was unremarkable. Some soft stool was noted in the colon.

### ***Pancreas***

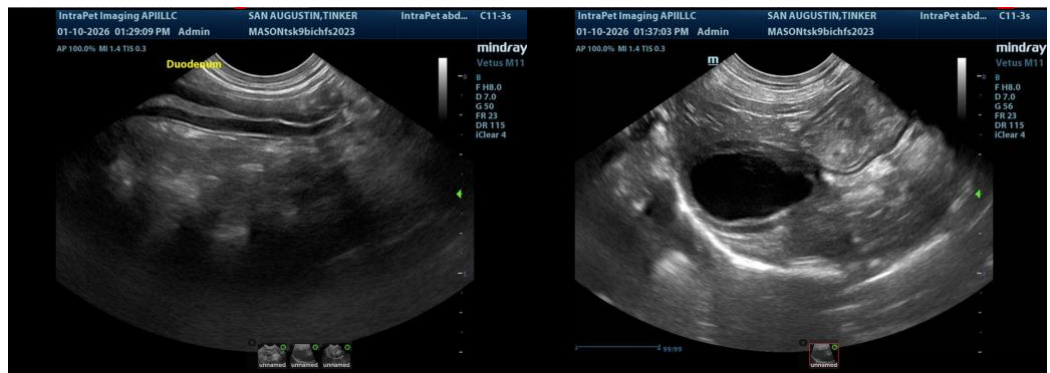
The right base of the **pancreas** revealed hyperechoic changes, consistent with remodeling. A history of pancreatitis is likely.

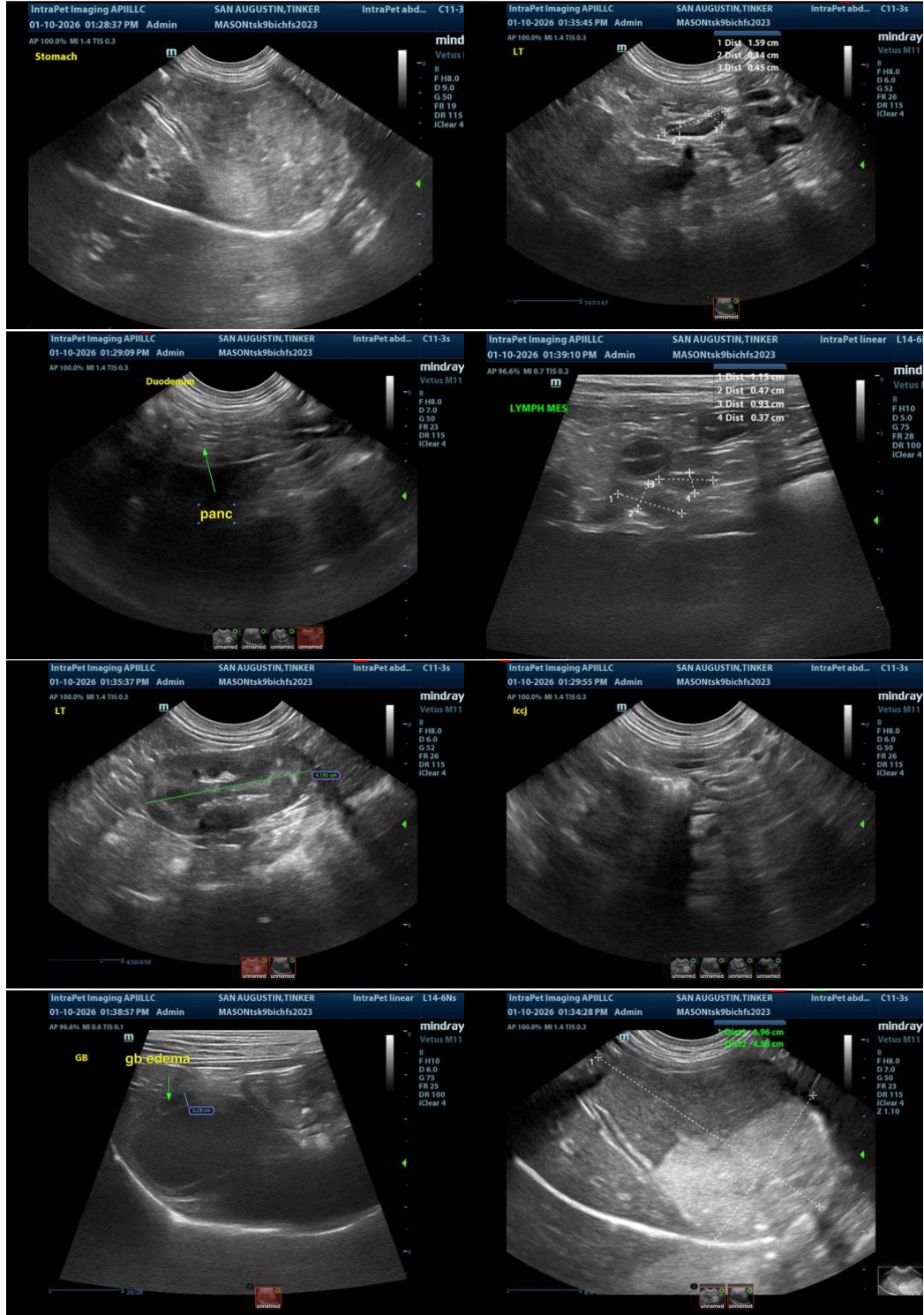
### **ULTRASONOGRAPHIC FINDINGS**

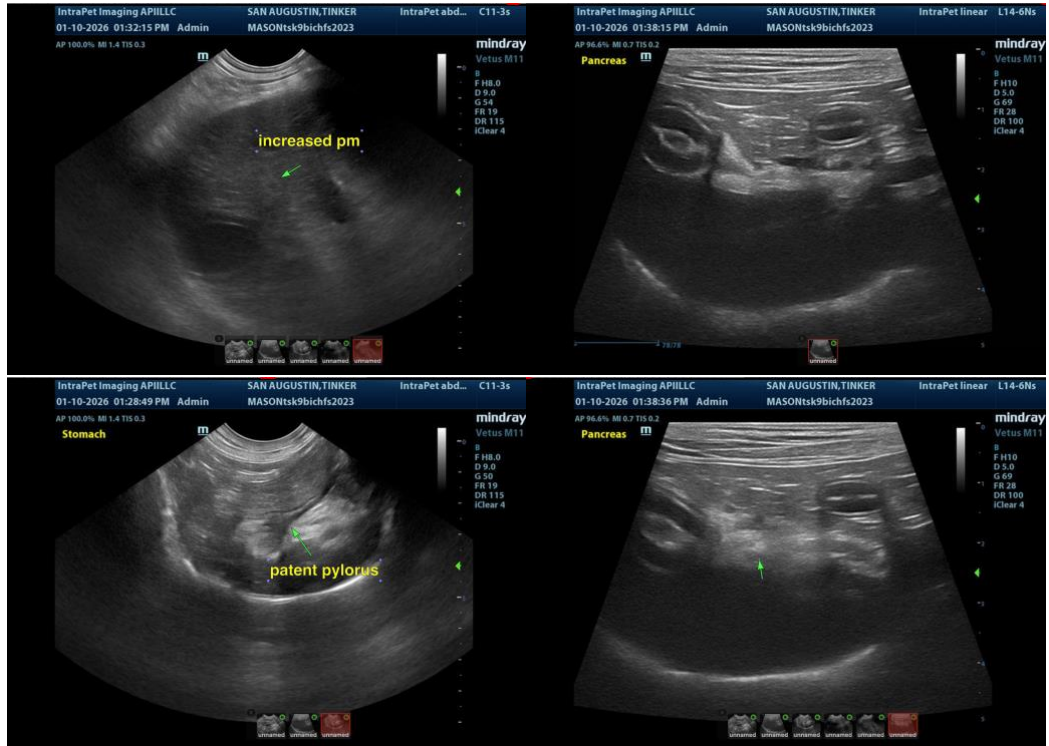
- Cholecystitis/choolangiohepatitis pattern
- Gastric overdistention
- Pancreatic remodeling

### **INTERPRETATION OF THE FINDINGS & FURTHER RECOMMENDATIONS**

Ultrasound guided cholecystocentesis and culture, as well as FNA of the liver, is indicated. Leptospirosis titers is indicated. No evidence or suspicion of neoplasia. The gastric overdistention is likely owing to metabolic ileus.







The information and recommendations provided are based on the images presented by the referring veterinarian/sonographer. No evaluation can be communicated regarding pathology that was not visible in the image/video clips provided.

Thank you for this referral. If the clinical or image interpretation does not parallel your findings or if I can be of any further assistance please contact me.

**Eric Lindquist**, DMV, DABVP(CFM), Cert. IVUSS,  
CEO, Owner, Founder -- SonoPath.com  
[info@SonoPath.com](mailto:info@SonoPath.com)