



PATIENT

Moses Sicoli

PRESENTING CLINICAL SIGNS

History: decreased appetite, vomiting, weight loss of 2 lbs in past year
Abnormal PE/Chem/CBC/UA Results: bw and exam WNL

SPECIES

Feline

ULTRASONOGRAPHIC EXAMINATION OF THE ABDOMEN

Urinary System

The **urinary bladder**, trigone, and pelvic urethra presented normal thicknesses and normal tone. The ureters were not visible which is normal. No uroliths or sediment were visualized and anechoic urine was present. No evidence of inflammatory or neoplastic changes was noted. Ureteral papillae were normal.

BREED

British Shorthair

SEX

Neutered male

The **kidneys** presented a relatively uniform cortical hyperechogenicity when compared to the renal medulla, spleen and liver. No overt masses were noted. Corticomedullary definition was nebulous and the ratio favored the cortex slightly. The ureters were not visible and assumed to be normal. These changes are most consistent with chronic interstitial nephritis yet infiltrative disease could not be entirely ruled out without biopsy though neoplasia is not suspected. The left kidney measured 4.81 cm. The right kidney measured 4.19 cm.

AGE

12 years

WEIGHT

10.9 lbs

Adrenal Glands

Both **adrenal glands** were visualized and recognized as having normal shape, size, position and echogenicity for this breed. The phrenic vasculature, glandular echogenicity and detail were unremarkable. Capsule, cortex, and medullary definition were normal for this age patient.

INTERPRETED BY

Eric Lindquist, DMV
DABVP, Cert. IVUSS

Spleen

The **spleen** was mildly enlarged with uniform, but subtly micronodular parenchyma, and undulating capsular contour. This is consistent with reactive spleen owing to immune stimulus or early infiltrative disease such as mast cell disease or lymphoma. 25-gauge FNA would be ideal if weight loss is an issue to differentiate early round cell neoplasia versus splenitis or reactive spleen all of which can present in this manner. The spleen measured 1.1 cm.

IMAGING PERFORMED BY

Dr. Roche

HOSPITAL NAME

Fredon AH

Liver

The **liver** images submitted revealed subjectively normal liver size, contour, and structure. Parenchymal echogenicity was naturally coarse and hypoechoic to the spleen. Vascular and biliary tracts were of normal volume with no evidence of congestion. The gallbladder presented acceptably thin walls with primarily anechoic content. The cystic and common bile ducts were normal. No pathological hepatic lymphadenopathy was evident. No overt structural evidence of inflammatory, infiltrative or regenerative pathology was evident.

REFERRING VET

Dr. Roche

INVOICE

42034

DATE

1/10/23



PATIENT

Gastrointestinal

Moses Sicoli

The **stomach** was mildly thickened with no loss of mural detail. The lumen was empty other than a minor amount of gas artifact. Muscularis hypertrophy was noted. Small intestinal thickening was noted without loss of mural detail.

SPECIES

Feline

Pancreas

BREED

British Shorthair

The base and limbs of the **pancreas** were observed to be largely isoechoic to surrounding omental fat. Pancreatic duct and capsular contour were acceptably normal and parenchyma respected normal curvilinear patterns. No overt evidence of active inflammatory or neoplastic disease was noted.

SEX

Neutered male

ULTRASONOGRAPHIC FINDINGS

Mild upper gastrointestinal thickening.

AGE

12 years

Minor splenic enlargement.

Chronic interstitial nephrosis, mild to moderate.

WEIGHT

10.9 lbs

INTERPRETATION OF THE FINDINGS & FURTHER RECOMMENDATIONS

Splenic FNA is indicated in this patient. This is likely underlying inflammatory bowel; however, emerging neoplasia cannot be completely ruled out, yet no neoplastic criteria was met with the GI tract at this time. Splenic FNA is indicated. Maldigestion panel, three view chest radiographs and full CNS examination is recommended to examine for occult disease that could be responsible for the weight loss. Evaluation for competitive eating environments should also be considered.

INTERPRETED BY

Eric Lindquist, DMV
DABVP, Cert. IVUSS

IMAGING PERFORMED BY

Dr. Roche

HOSPITAL NAME

Fredon AH

REFERRING VET

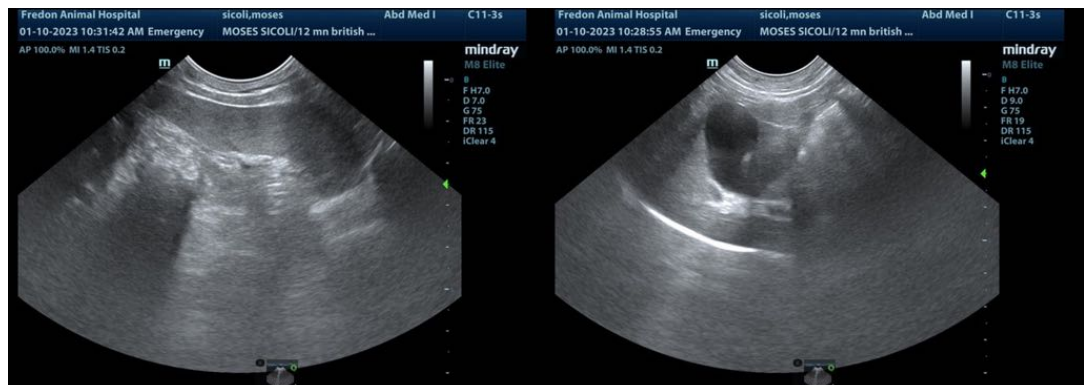
Dr. Roche

INVOICE

42034

DATE

1/10/23





PATIENT

Moses Sicoli

SPECIES

Feline

BREED

British Shorthair

SEX

Neutered male

AGE

12 years

WEIGHT

10.9 lbs

INTERPRETED BY

Eric Lindquist, DMV
DABVP, Cert. IVUSS

IMAGING PERFORMED BY

Dr. Roche

HOSPITAL NAME

Fredon AH

REFERRING VET

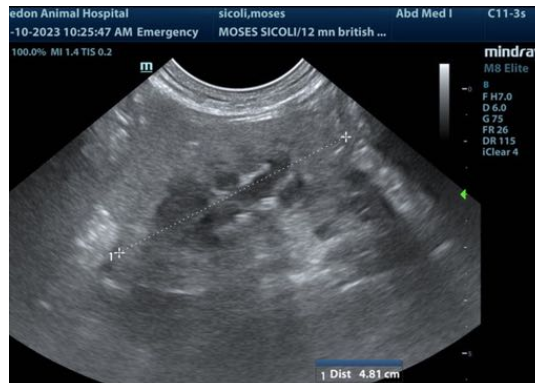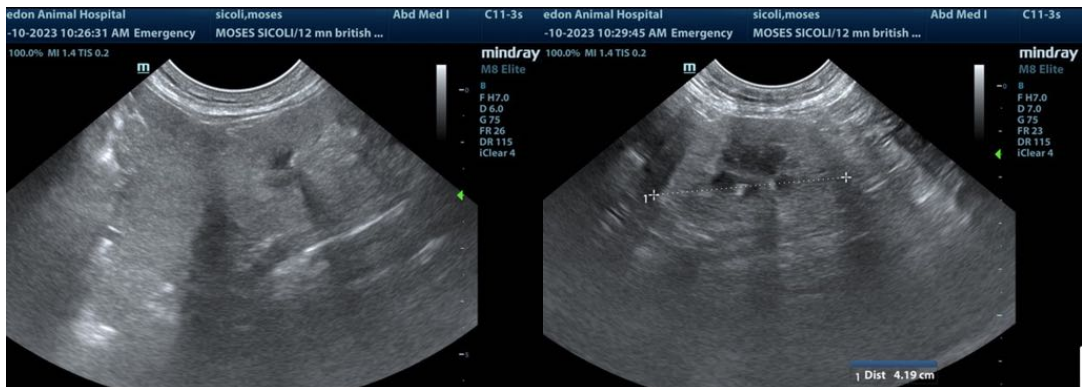
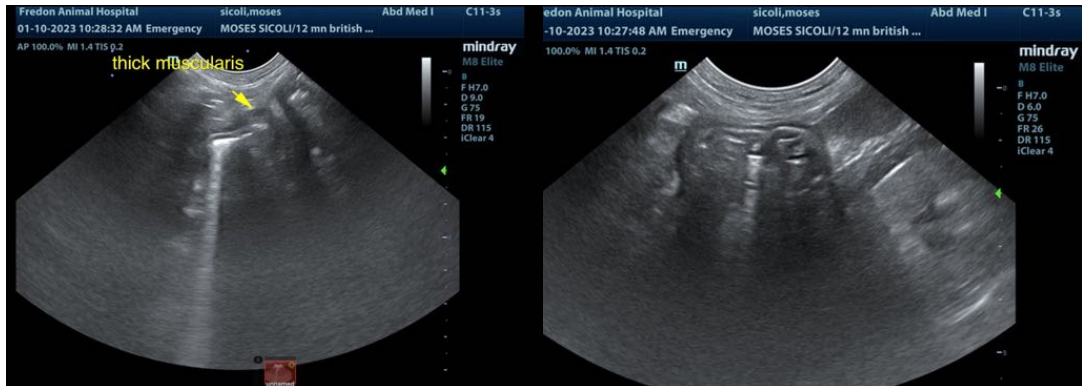
Dr. Roche

INVOICE

42034

DATE

1/10/23



The information and recommendations provided are based on the images presented by the referring veterinarian/sonographer. No evaluation can be communicated regarding pathology that was not visible in the image/video clips provided.

Thank you for this referral. If the clinical or image interpretation does not parallel your findings or if I can be of any further assistance please contact me.

Eric Lindquist, DMV, DABVP, Cert. IVUSS, CEO of SonoPath.com
info@SonoPath.com