

PATIENT

PRESENTING CLINICAL SIGNS

Leilah Cutia

History: Hx of chronic paraplegia and chronic urine retention w/ urinary tract infections

SPECIES

ULTRASONOGRAPHIC EXAMINATION OF THE ABDOMEN

Canine

Urinary System

BREED

The **urinary bladder**, trigone, and pelvic urethra presented normal thicknesses and normal tone. The ureters were not visible which is normal. No uroliths or sediment were visualized and anechoic urine was present. No evidence of inflammatory or neoplastic changes was noted. Ureteral papillae were normal.

Pug Mix

SEX

The **kidneys** revealed normal size and structure, corticomedullary definition and ratio for this age. The cortices presented largely uniform texture with normal echogenic relationship to liver and spleen. Medullary structure differed distinctly from the cortex and no evidence of pelvic dilation was present. The capsules were acceptably uniform without significant irregularities. The left kidney revealed a cortical infarct at the dorsal cortex. The left kidney measured 4.5 cm. Blood flow to the kidneys were unremarkable.

Spayed female

AGE

12 years

WEIGHT

Adrenal Glands

25 lbs

The left **adrenal gland** was visualized and recognized as having normal shape, size, position and echogenicity for this breed. The phrenic vasculature, glandular echogenicity and detail were unremarkable. Capsule, cortex, and medullary definition were normal for this age patient. The left adrenal gland measured 0.4 cm. The right adrenal gland measured not visualized.

INTERPRETED BY

Eric Lindquist, DMV
DABVP, Cert. IVUSS

IMAGING PERFORMED BY

Tyler Totman LVT

Spleen

HOSPITAL NAME

Adana VC

The **spleen** presented a smooth homogeneous parenchyma hyperechoic to liver and renal cortical parenchyma. The capsule was smooth without noticeable expansion or deviation from within the spleen or adjacent pathology. The splenic vasculature demonstrated normal volume without signs of congestion or thrombosis. No sonographic evidence of acute or chronic inflammatory, neoplastic, or infarctual changes was noted.

REFERRING VET

Dr. Wildenstein

Liver

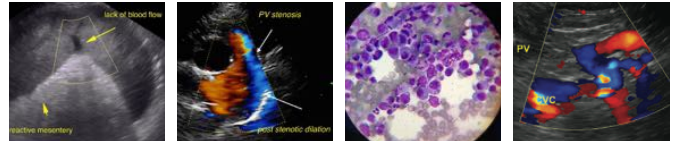
INVOICE

42053

The **liver** images from right and left intercostal as well as subcostal views revealed subjectively normal liver contour and structure. The liver was mildly subnormal in size. Some age-related parenchymal remodeling was noted but likely not clinically significant at this time. Vascular and biliary tracts were of normal volume and no evidence of congestion was noted. The gallbladder presented some dependent debris with essentially normal contour. The cystic and common bile ducts were normal. No overt evidence of active inflammatory, infiltrative or regenerative pathology was noted but should be paired with current or past LE elevations regarding any clinical significance to this presentation. The hepatic lymph nodes were unremarkable.

DATE

1/10/23



PATIENT

Leilah Cutia

SPECIES

Canine

BREED

Pug Mix

SEX

Spayed female

AGE

12 years

WEIGHT

25 lbs

INTERPRETED BY

Eric Lindquist, DMV
DABVP, Cert. IVUSS

IMAGING PERFORMED BY

Tyler Totman LVT

HOSPITAL NAME

Adana VC

REFERRING VET

Dr. Wildenstein

INVOICE

42053

DATE

1/10/23

Gastrointestinal

Examination of the **gastrointestinal tract** revealed a stomach and intestine free of stasis, of normal wall thickness, acceptable curvilinear mural detail, and peristaltic activity. Small and large intestine demonstrated normal luminal chyme and stool consistency respectively. No obstructive or overt infiltrative disease was noted. No associated abnormal lymphatic activity was noted.

Pancreas

The base and limbs of the **pancreas** were observed to be largely isoechoic to surrounding omental fat. Pancreatic duct and capsular contour were acceptably normal and parenchyma respected normal curvilinear patterns. No overt evidence of active inflammatory or neoplastic disease was noted.

Free Abdomen

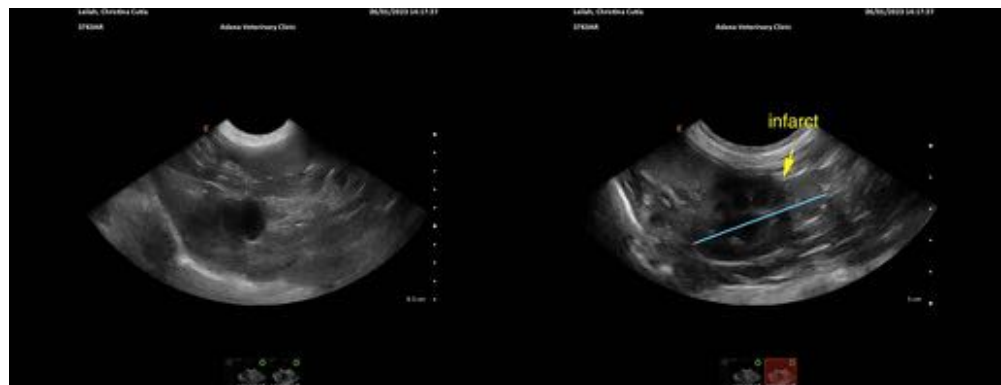
The iliac trifurcation was unremarkable and the urethra was not visualized.

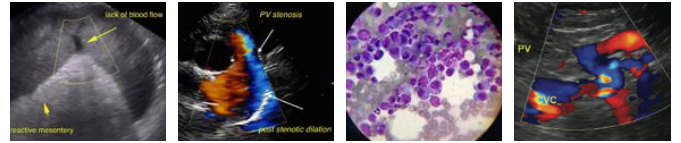
ULTRASONOGRAPHIC FINDINGS

Structurally normal lower urinary tract with left renal infarct with mild degenerative changes.
Mild degenerative hepatic changes.

INTERPRETATION OF THE FINDINGS & FURTHER RECOMMENDATIONS

Further imaging of the pelvic urethra, right adrenal gland and right kidney is warranted. From a clinical perspective assessment of the vaginal vestibule for recessed vulva or urine pooling is indicated.





PATIENT

Leilah Cutia

SPECIES

Canine

BREED

Pug Mix

SEX

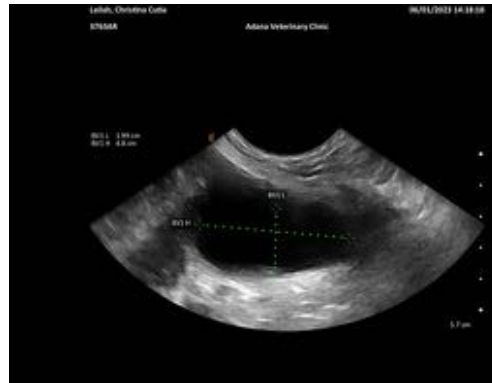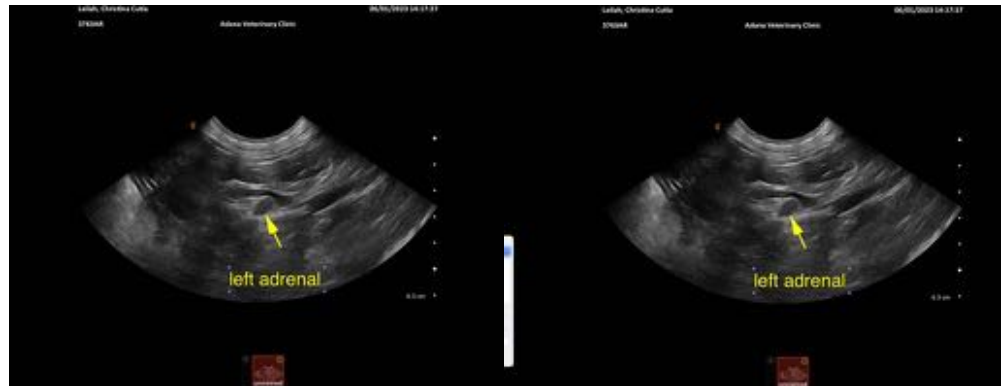
Spayed female

AGE

12 years

WEIGHT

25 lbs



INTERPRETED BY

Eric Lindquist, DMV
DABVP, Cert. IVUSS

IMAGING PERFORMED BY

Tyler Totman LVT

HOSPITAL NAME

Adana VC

REFERRING VET

Dr. Wildenstein

INVOICE

42053

DATE

1/10/23

The information and recommendations provided are based on the images presented by the referring veterinarian/sonographer. No evaluation can be communicated regarding pathology that was not visible in the image/video clips provided.

Thank you for this referral. If the clinical or image interpretation does not parallel your findings or if I can be of any further assistance please contact me.

Eric Lindquist, DMV, DABVP, Cert. IVUSS, CEO of SonoPath.com
info@SonoPath.com