



**PATIENT**

Gunner Savino

**PRESENTING CLINICAL SIGNS**

History: diluted urine : 1.020 / elevated alp: 540. no clinical symptoms.

**SPECIES**

Canine

**ULTRASONOGRAPHIC EXAMINATION OF THE ABDOMEN**

**Urinary System**

The **urinary bladder**, trigone, and pelvic urethra presented normal thicknesses and normal tone. The ureters were not visible which is normal. No uroliths or sediment were visualized and anechoic urine was present. No evidence of inflammatory or neoplastic changes was noted. Ureteral papillae were normal.

**BREED**

Cockapoo

The **kidneys** revealed largely normal size and structure, corticomedullary definition and ratio (cortex 1/3 of medulla) were essentially maintained with some age-related loss of curvilinear patterns regarding the capsule and C/M junction. The cortices presented largely uniform texture with some increased echogenicity expected for his age patient. Medullary structure differed distinctly from that of the cortex and no evidence of pelvic dilatation was present. Slight pinpoint mineralization was noted in both kidneys. The left kidney measured 5.0 cm. The right kidney measured 5.0 cm.

**SEX**

Neutered male

**AGE**

11 years

**Adrenal Glands**

The **adrenal glands** are not visualized. The regions of the adrenal glands were imaged with no evidence of pathology. There were no obvious masses.

**WEIGHT**

35.5 lbs

**INTERPRETED BY**

Eric Lindquist, DMV  
DABVP, Cert. IVUSS

**Spleen**

The **spleen** in this patient was mildly enlarged with uniform parenchyma and was folded upon itself. This is a positional variant and is not pathological. There was no evidence of significant disease.

**IMAGING PERFORMED BY**

Dr. Han

**Liver**

The **liver** was uniformly swollen with minor, excessive gallbladder debris and over distension with dependent and suspended bile without evidence of overt mucocele formation. However, excessive sludge was present. The liver presented coarse architecture with mildly increased portal markings and subtle, mixed echogenic changes. This is consistent with vacuolar hepatopathy and some level of remodeling and history of inflammatory component. There was no overt suspicion of neoplasia.

**HOSPITAL NAME**

Tenafly VC

**REFERRING VET**

Dr. Han

**Gastrointestinal**

Examination of the **gastrointestinal tract** revealed a stomach and intestine free of stasis, of normal wall thickness, acceptable curvilinear mural detail, and peristaltic activity. Small and large intestine demonstrated normal luminal chyme and stool consistency respectively. No obstructive or overt infiltrative disease was noted. No associated abnormal lymphatic activity was noted.

**INVOICE**

42051

**DATE**

1/10/23

**Pancreas**



**PATIENT**

Gunner Savino

The base and limbs of the **pancreas** were observed to be largely isoechoic to surrounding omental fat. Pancreatic duct and capsular contour were acceptably normal and parenchyma respected normal curvilinear patterns. No overt evidence of active inflammatory or neoplastic disease was noted.

**SPECIES**

Canine

**ULTRASONOGRAPHIC FINDINGS**

Structurally unremarkable abdomen.

**BREED**

Cockapoo

Vacuolar hepatopathy pattern.

**SEX**

Neutered male

**INTERPRETATION OF THE FINDINGS & FURTHER RECOMMENDATIONS**

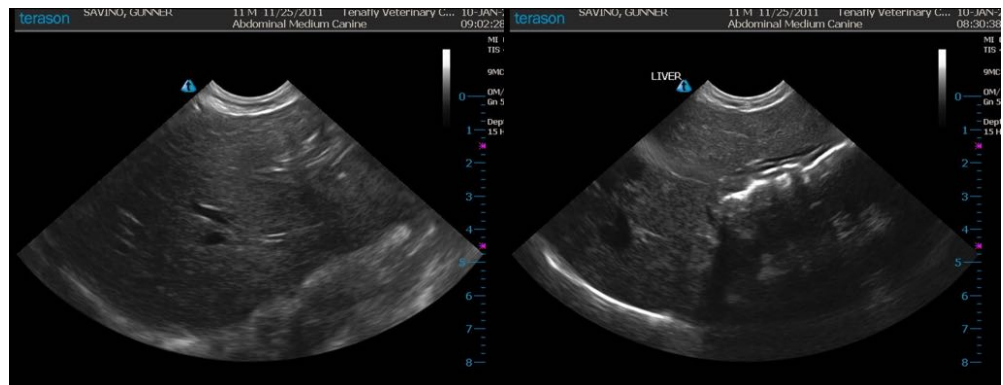
There was no evidence of significant disease.

**AGE**

11 years

**WEIGHT**

35.5 lbs

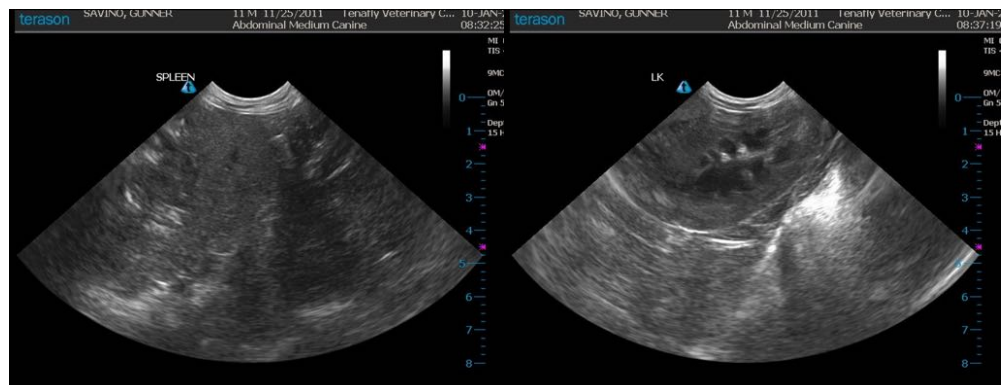


**INTERPRETED BY**

Eric Lindquist, DMV  
DABVP, Cert. IVUSS

**IMAGING PERFORMED BY**

Dr. Han



**HOSPITAL NAME**

Tenafly VC

**REFERRING VET**

Dr. Han

**INVOICE**

42051

**DATE**

1/10/23



**PATIENT**

Gunner Savino

**SPECIES**

Canine

**BREED**

Cockapoo

**SEX**

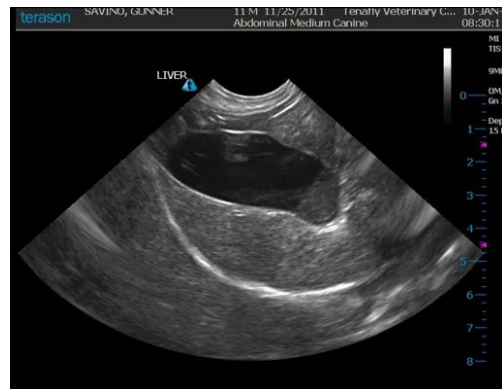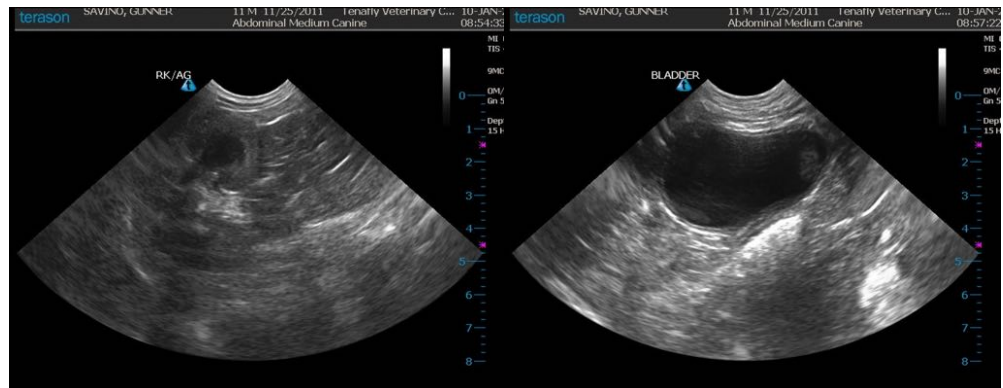
Neutered male

**AGE**

11 years

**WEIGHT**

35.5 lbs



**INTERPRETED BY**

Eric Lindquist, DMV  
DABVP, Cert. IVUSS

**IMAGING PERFORMED BY**

Dr. Han

**HOSPITAL NAME**

Tenafly VC

**REFERRING VET**

Dr. Han

**INVOICE**

42051

**DATE**

1/10/23

The information and recommendations provided are based on the images presented by the referring veterinarian/sonographer. No evaluation can be communicated regarding pathology that was not visible in the image/video clips provided.

Thank you for this referral. If the clinical or image interpretation does not parallel your findings or if I can be of any further assistance please contact me.

**Eric Lindquist**, DMV, DABVP, Cert. IVUSS, CEO of SonoPath.com  
info@SonoPath.com