



**PATIENT PRESENTING CLINICAL SIGNS**

Toby Spray History: normal diet EN cc--vomiting/diarrhea bw nwl but pli very high at 980 b12/folate and k9ibd assay pending

**SPECIES**

Canine

**ULTRASONOGRAPHIC EXAMINATION OF THE ABDOMEN**

**BREED**

Yorkie

**Urinary System**

The **urinary bladder**, trigone, and pelvic urethra presented normal thicknesses and normal tone. The ureters were not visible which is normal. No uroliths or sediment were visualized and anechoic urine was present. No evidence of inflammatory or neoplastic changes was noted. Ureteral papillae were normal.

**SEX**

Neutered male

**AGE**

13 years

The **kidneys** revealed normal size and structure, corticomedullary definition and ratio for this age. The cortices presented largely uniform texture with normal echogenic relationship to liver and spleen. Medullary structure differed distinctly from the cortex and no evidence of pelvic dilation was present. The capsules were acceptably uniform without significant irregularities. The right kidney measured 3.77 cm. The left kidney measured 3.74 cm.

**WEIGHT**

13.1 lbs

**Adrenal Glands**

The right **adrenal gland** appeared slightly enlarged and swollen. No evidence of focal capsular expansion or invasion into the phrenic veins was noted. No overt suspicion of neoplasia was noted. This is considered likely a hyperplastic change associated with stress or adrenal endocrinopathy (PDH). If isosthenuria is persistently present and the patient morphologically suggests Cushing's disease then ACTH testing would be indicated. The right adrenal gland measured 2.0 x 1.2 cm at the cranial pole and 0.8 cm at the caudal pole. The left adrenal gland was normal in size and contour and measured 0.6 cm.

**INTERPRETED BY**

Eric Lindquist, DMV DABVP, Cert. IVUSS

**IMAGING PERFORMED BY**

Dr. Barnea

**Spleen**

**HOSPITAL NAME**

Tenaflly VC

The **spleen** presented a smooth homogeneous parenchyma hyperechoic to liver and renal cortical parenchyma. The capsule was smooth without noticeable expansion or deviation from within the spleen or adjacent pathology. The splenic vasculature demonstrated normal volume without signs of congestion or thrombosis. No sonographic evidence of acute or chronic inflammatory, neoplastic, or infarctual changes was noted.

**REFERRING VET**

Dr. Han

**Liver**

**INVOICE**

95066

The **liver** images from right and left intercostal as well as subcostal views revealed subjectively normal liver size, contour, and structure. Some age-related parenchymal remodeling was noted but likely not clinically significant at this time. Vascular and biliary tracts were of normal volume and no evidence of congestion was noted. The gallbladder presented some dependent debris with essentially normal contour. The cystic and common bile ducts were normal. No overt evidence of active inflammatory, infiltrative or regenerative pathology was noted but should be paired with current or past LE elevations regarding any clinical significance to this presentation. The hepatic lymph nodes were unremarkable.

**DATE**

1/10/22



**PATIENT**

**Gastrointestinal**

Toby Spray

Examination of the **gastrointestinal tract** revealed a stomach and intestine free of stasis, of normal wall thickness, acceptable curvilinear mural detail, and peristaltic activity. Small and large intestine demonstrated normal luminal chyme and stool consistency respectively. No obstructive or overt infiltrative disease was noted. No associated abnormal lymphatic activity was noted.

**SPECIES**

Canine

**BREED**

Yorkie

**SEX**

Neutered male

**Pancreas**

The base and limbs of the **pancreas** were observed to be largely isoechoic to surrounding omental fat. Some parenchymal remodeling, however, with mild deviation from curvilinear normalcy was observed. Pancreatic duct and capsular irregularities were present consistent with age related changes. If pain upon imaging (+ Murphy sign) was present or if the patient is focally painful in subxiphoid palpation then low-grade smoldering chronic pancreatitis should be suspected.

**AGE**

13 years

**ULTRASONOGRAPHIC FINDINGS**

Pancreatic remodeling.

Bilateral adrenal hypertrophy.

**WEIGHT**

13.1 lbs

**INTERPRETATION OF THE FINDINGS & FURTHER RECOMMENDATIONS**

There was no evidence of significant active disease other than possible low-grade pancreatic inflammation. A clinical trial of the following may prove effective.

**INTERPRETED BY**

Eric Lindquist, DMV  
DABVP, Cert. IVUSS

**Helicobacter/Gastritis protocol**

A clinical trial of **Zithromax** (Dogs: 5-10 mg/kg p.o. q24h. May increase dosing interval to q48h after 3-5 days of treatment), **Metronidazole** (10-20 mg/kg p.o. b.i.d.), **Sucralfate** (0.5-2 g/dog PO) and **Omeprazole** (1 mg/kg p.o. s.i.d.) over the next 3 weeks along with a **novel-protein or hydrolyzed diet** with slurry feeding b.i.d./t.i.d. over the next 2-4 days and then increase to canned diet bid. Dry food should be avoided over the next 4 weeks. A recheck sonogram to assess GI improvement or progression would be ideal in 4 weeks.

**IMAGING PERFORMED BY**

Dr. Barnea

**HOSPITAL NAME**

Tenaflly VC

**REFERRING VET**

Dr. Han

**INVOICE**

95066

**DATE**

1/10/22



**PATIENT**

Toby Spray

**SPECIES**

Canine

**BREED**

Yorkie

**SEX**

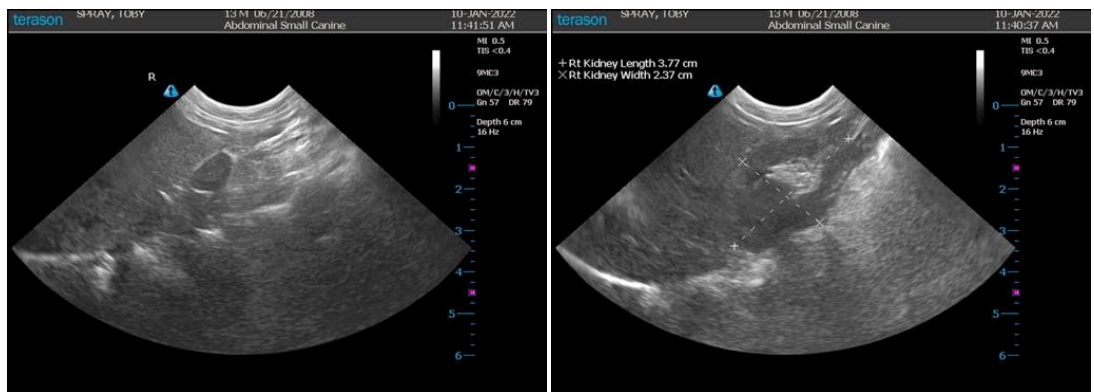
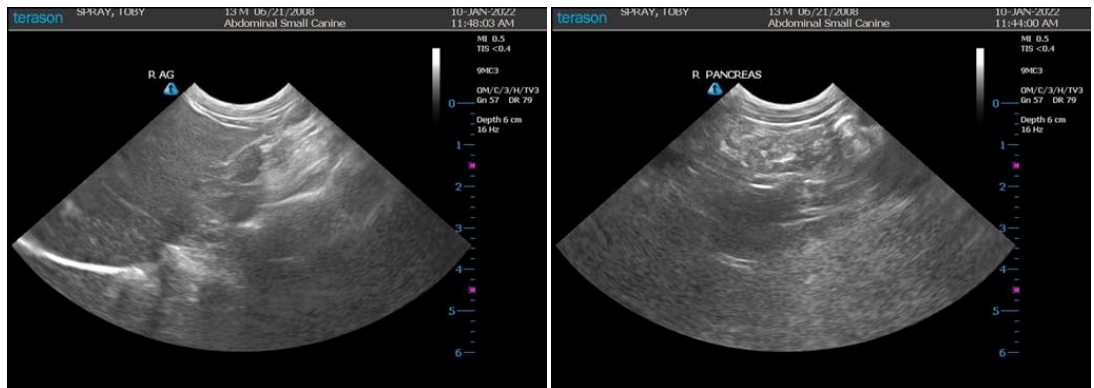
Neutered male

**AGE**

13 years

**WEIGHT**

13.1 lbs



**INTERPRETED BY**

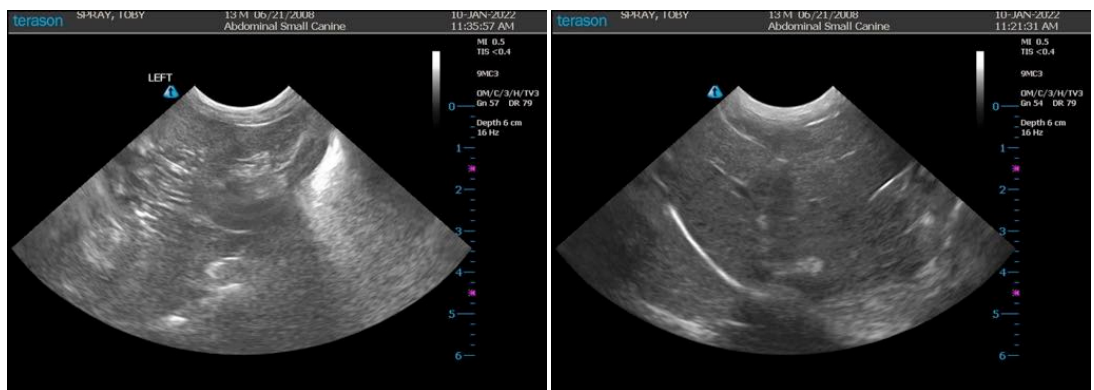
Eric Lindquist, DMV  
DABVP, Cert. IVUSS

**IMAGING PERFORMED BY**

Dr. Barnea

**HOSPITAL NAME**

Tenaflly VC



**REFERRING VET**

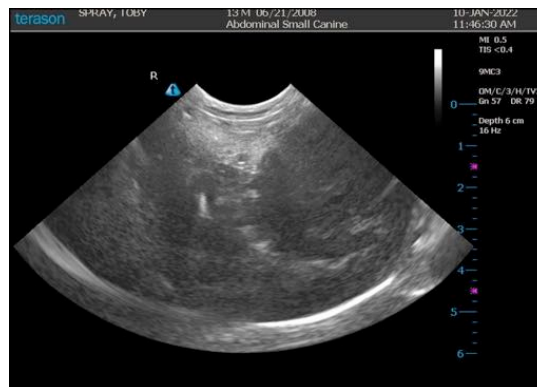Dr. Han

**INVOICE**

95066

**DATE**

1/10/22





**PATIENT**

Toby Spray

**SPECIES**

Canine

**BREED**

Yorkie

**SEX**

Neutered male

**AGE**

13 years

**WEIGHT**

13.1 lbs

**INTERPRETED BY**

Eric Lindquist, DMV  
DABVP, Cert. IVUSS

**IMAGING  
PERFORMED BY**

Dr. Barnea

**HOSPITAL NAME**

Tenaflly VC

**REFERRING VET**

Dr. Han

**INVOICE**

95066

**DATE**

1/10/22

The information and recommendations provided are based on the images presented by the referring veterinarian. No evaluation can be communicated regarding pathology that was not visible in the image/video clips provided.

Thank you for this referral. If the clinical or image interpretation does not parallel your findings or if I can be of any further assistance please contact me.

**Eric Lindquist**, DMV, DABVP, Cert. IVUSS, CEO of SonoPath.com  
info@SonoPath.com