SonoPath
Clinical Sonography & Telecytology

EDUCATIONAL TELECONSULTATION SERVICES™

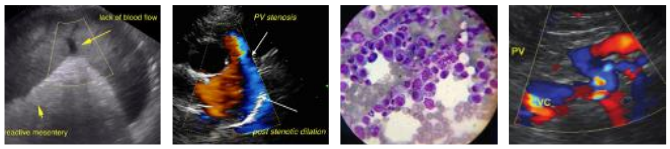

SonoPath.com
1-800-838-4268 info@sonopath.com

PATIENT

Mimie Bordanero

SPECIES

Feline

BREED

DSH

SEX

Spayed Female

AGE

12 Years

WEIGHT

9.9 Lbs.

INTERPRETED BY

Eric Lindquist, DMV
DABVP, Cert. IVUSS

IMAGING PERFORMED BY

Diane McFadden

HOSPITAL NAME

Butler VH

REFERRING VET

Dr. Garro

INVOICE

13347

DATE

1/10/22

PRESENTING CLINICAL SIGNS

History: neutrophilia, ascites, new arrhythmia today; BP 60 today. On baytril, metronidazole, mirtazapine

Abnormal PE/Chem/CBC/UA Results: WBC 24.2, neutrophils 19.8, toxic neutrophils on slide review; UA: protein 3+, USPG 1.066

ULTRASONOGRAPHIC EXAMINATION OF THE HEART & ABDOMEN

FELINE CARDIAC PARAMETERS	**BODY WEIGHT** (kg)	**HR** (BPM)	**IVSd** (cm)	**LVIDd** (cm)	**LVWd** (cm)	**FS** (%)	**EF** (%)
NORMAL PARAMETER	------	150-240	0.3-0.6	1.0-2.1	0.25-0.6	35-67	80-100
PATIENT	--	2.04	0.35	1.58	0.33	39	73
FELINE CARDIAC PARAMETERS	**LA/AO** (Boon)	**LA/AO HEART BASE** (Sisson)	**LA** 2D 4-chamber long axis AS to FW (Sisson) (cm)		**LVOT VEL.** (m/s)	**RVOT VEL.** (m/s)	**IVRT** (m/)
NORMAL PARAMETER	<1.5	0.88-1.79	0.7-1.7		<1.6	<1.3	40-60
PATIENT	1.43	1.4	--		1.01	--	NM

Adapted from June Boon,Veterinary Echocardiography,1998
Sisson D et al. JVIM 1991; 5: 232, Jacobs et al. Am J Vet Res 1985; 46:1705

Cardiac Presentation

The echocardiogram in this patient demonstrated normal **left atrial** size based on 3 separate LA measurements. The cranial and caudal **mitral** valve leaflets presented normal linear structure and kinetics. The **left ventricle** presented normal thicknesses with linear contour and was not dilated nor restricted. The **myocardium** presented normal echogenicity without subjective evidence of significant fibrotic or ischemic disease. **Contractility** of the ventricular walls was adequate and in normal range for this patient evidenced by the fractional shortening measurement and subjective evaluation of the different regions and angles of the myocardium. The **left ventricular outflow** tract demonstrated normal laminar flow and subjective structural integrity. The **right atrium** and auricle revealed normal size, structure and content. No evidence of masses was noted or chamber overload. **Tricuspid** valvular assessment demonstrated adequate linear morphology and kinetics. The **right ventricle** was of normal size (1/3 diameter of LV), chordae structure, myocardial echogenicity and thickness. **Pulmonic** tract assessment revealed normal valve structure, laminar flow, and diameter (approx.1:1 pa/ao ratio). No visible **pericardial** or free pleura fluid was noted or extra cardiac pathology in the visible planes. The cranial **mediastinum and pericardial regions** were free of masses in the visible window.

Urinary System

The **urinary bladder** revealed slight ventral and dorsal wall thickening yet no evidence of calculi. Anechoic urine was present.

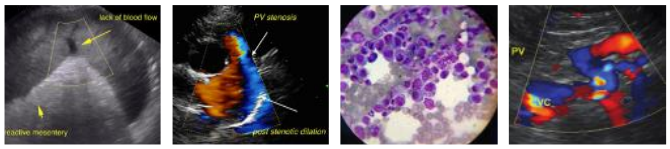

SonoPath.com
1-800-838-4268 info@sonopath.com

PATIENT

Mimie Bordanero

SPECIES

Feline

BREED

DSH

SEX

Spayed Female

AGE

12 Years

WEIGHT

9.9 Lbs.

INTERPRETED BY

Eric Lindquist, DMV
DABVP, Cert. IVUSS

IMAGING PERFORMED BY

Diane McFadden

HOSPITAL NAME

Butler VH

REFERRING VET

Dr. Garro

INVOICE

13347

DATE

1/10/22

The **left kidney** revealed normal size and structure, corticomedullary definition and ratio for this age. The cortices presented largely uniform texture with normal echogenic relationship to liver and spleen. Medullary structure differed distinctly from the cortex and no evidence of pelvic dilation was present. The capsules were acceptably uniform without significant irregularities. The left kidney measured 3.5 cm.

The **right kidney** was irregular and thickening with cortical infarcts and mineralization. Reactive surrounding mesentery was noted. This change is consistent with acute nephritis or infiltrative event. The right kidney measured 4.01 cm.

Adrenal Glands

Both **adrenal glands** were visualized and recognized as having normal shape, size, position and echogenicity for this breed. The phrenic vasculature, glandular echogenicity and detail were unremarkable. Capsule, cortex, and medullary definition were normal for this age patient. The left adrenal gland measured 0.34 cm. The right adrenal gland measured

Spleen

The **spleen** measured the upper limits of normal at 0.98 cm with uniform parenchyma.

Liver

The **liver** was mildly enlarged with coarse architecture, nonspecific. The gallbladder and common bile duct were unremarkable. No evidence of posthepatic obstruction.

Gastrointestinal

Coalescing omentum was noted around the **upper gastrointestinal tract** which presented variable thickening. The small intestine and colon were unremarkable.

Pancreas

Nodular omental changes noted around **pancreas**.

Free Abdomen

A large amount of **ascites** was noted in this patient. Undifferentiated hypoechoic omental masses were present, measuring up to 2 cm. This may be deriving from the pancreas or elsewhere.

ULTRASONOGRAPHIC FINDINGS

- Lymphomatosis/carcinomatosis type presentation
- Normal echocardiogram

INTERPRETATION OF THE FINDINGS & FURTHER RECOMMENDATIONS

FIP, minor potential. FNA of the spleen +/- hypoechoic areas in the omentum or simple abdominocentesis and cytospin (to assess for neoplastic cells) all indicated for a definitive diagnosis.

SonoPath

Clinical Sonography & Telecytology

EDUCATIONAL TELECONSULTATION SERVICES™

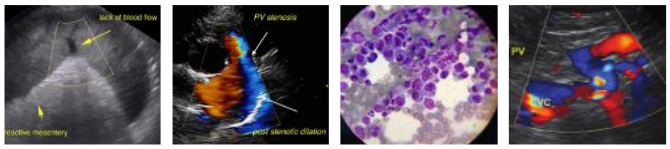

SonoPath.com™
1-800-838-4268 info@sonopath.com

PATIENT

Mimie Bordanero

SPECIES

Feline

BREED

DSH

SEX

Spayed Female

AGE

12 Years

WEIGHT

9.9 Lbs.

INTERPRETED BY

Eric Lindquist, DMV
DABVP, Cert. IVUSS

IMAGING PERFORMED BY

Diane McFadden

HOSPITAL NAME

Butler VH

REFERRING VET

Dr. Garro

INVOICE

13347

DATE

1/10/22

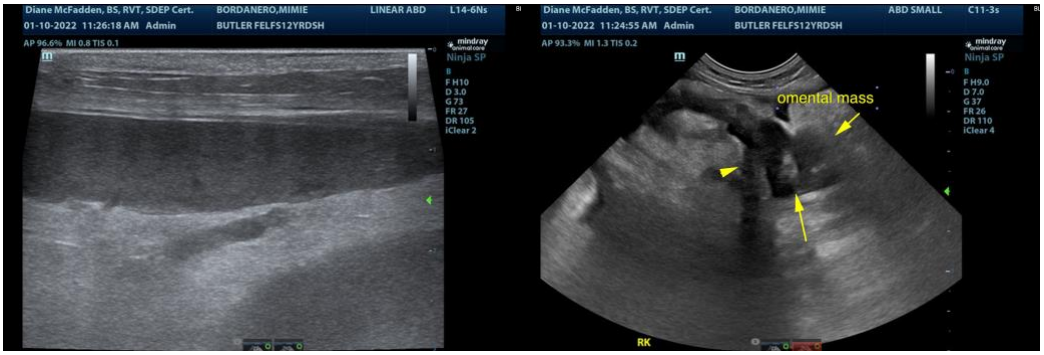

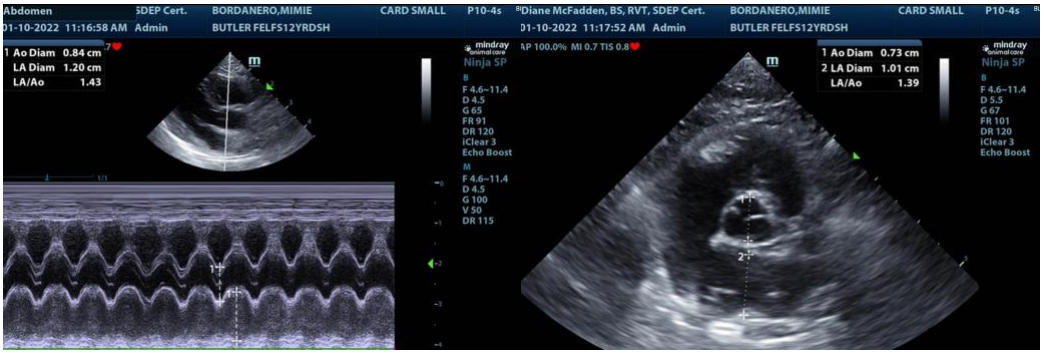

SonoPath

Clinical Sonography & Telecytology

EDUCATIONAL TELECONSULTATION SERVICES™

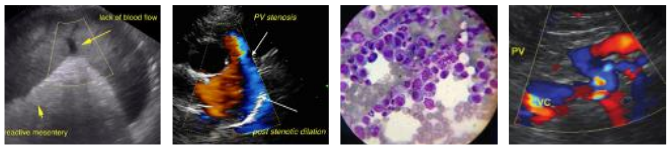

SonoPath.com

1-800-838-4268 info@sonopath.com

PATIENT

Mimie Bordanero

SPECIES

Feline

BREED

DSH

SEX

Spayed Female

AGE

12 Years

WEIGHT

9.9 Lbs.

INTERPRETED BY

Eric Lindquist, DMV
DABVP, Cert. IVUSS

IMAGING PERFORMED BY

Diane McFadden

HOSPITAL NAME

Butler VH

REFERRING VET

Dr. Garro

INVOICE

13347

DATE

1/10/22

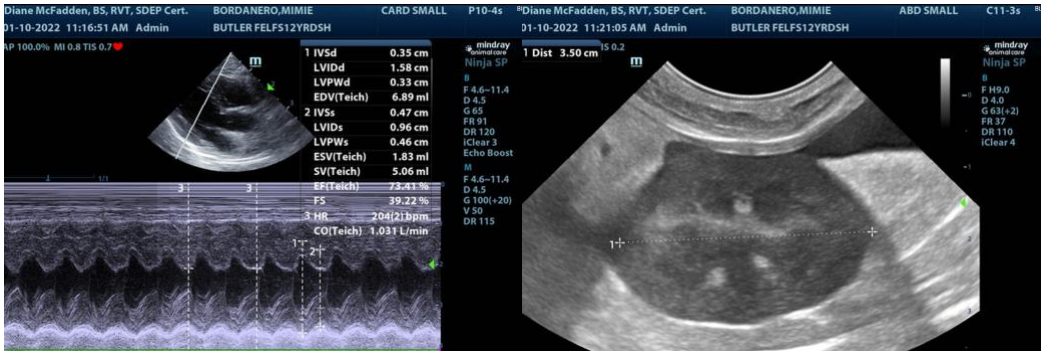

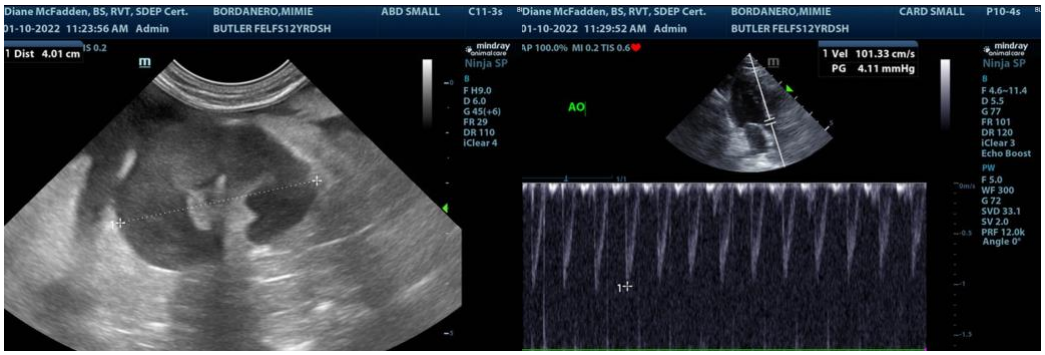

The information and recommendations provided are based on the images presented by the referring veterinarian. No evaluation can be communicated regarding pathology that was not visible in the image/video clips provided.

Thank you for this referral. If the clinical or image interpretation does not parallel your findings or if I can be of any further assistance please contact me.

Eric Lindquist, DMV, DABVP, Cert. IVUSS, CEO of SonoPath.com
info@SonoPath.com