SonoPath
Clinical Sonography & Telecytology

EDUCATIONAL TELECONSULTATION SERVICES™

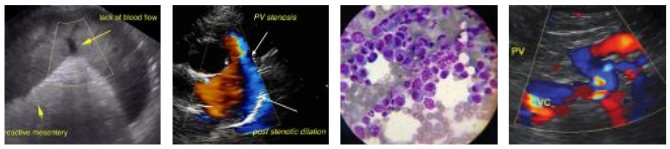

SonoPath.com
1-800-838-4268 info@sonopath.com

PATIENT

Bryce Eastwood

SPECIES

Canine

BREED

Cocker Spaniel

SEX

Neutered Male

AGE

5 Years

WEIGHT

20.1 Lbs.

INTERPRETED BY

Eric Lindquist, DMV
DABVP, Cert. IVUSS

IMAGING PERFORMED BY

Couser

HOSPITAL NAME

Willamette VH

REFERRING VET

Couser

INVOICE

13337

DATE

1/10/22

PRESENTING CLINICAL SIGNS

History: Hospitalized for vomiting 1/7-1/8. Initial workup (1/7/22): CBC-WBC 17.61, NEUTS 14.95, HCT 49.6% CHEM10/LYTES/LAC- WNL CPL-normal Abd rads (1/7/22) Radiologist report: FINDINGS: There is adequate abdominal detail. The stomach contains a moderate volume of air and is otherwise empty. There is gas and fluid in the colon and small intestines. There is no intestinal dilation and there are no foreign bodies within the digestive tract. There is a thin metallic wire fragment in the cranial abdomen, not associated with bowel. The spleen, liver, kidneys, urinary bladder, retroperitoneal space, area of the pancreas, are normal as are included skeletal and caudal thoracic structures. CONCLUSIONS: There is no evidence of obstruction. There is impression of enteritis and colitis. Small metallic wire fragment is considered incidental. RECOMMENDATIONS: Consider initiating symptomatic therapy. Supportive care including fluid therapy may be warranted. Persistent vomiting or anorexia may justify abdominal ultrasound. ** Hosp on IVF & GI support overnight. Recheck fasted abd rads (1/8/22) - rad report: FINDINGS: Abdominal serosal detail is good. The stomach is moderately distended and filled with gas, fluid and heterogenous ingesta. The previously described metallic wire is still present and appears to be at least partially migrated outside the gastrointestinal tract. Small intestinal structures are gas and fluid filled without evidence of pathologic bowel dilation or plication. The cecum contains gas. The colon contains gas and formed feces and is normal in diameter and position. The liver, spleen, kidneys and urinary bladder exhibit no gross abnormalities such as severe organomegaly, large mass lesions, or opaque calculi within the significant limits of overlying GI tract in this patient. The last pair of ribs is dysplastic and the first lumbar vertebra has developed as an asymmetric lumbosacral transitional vertebra. CONCLUSIONS: A definitive cause for the regurgitation is still not identified. There is no evidence of gastrointestinal obstruction in this examination. The heterogenous material in the stomach is nonspecific and could reflect normal ingesta foreign material. The mild to moderate gastric distention could reflect gastritis. Migrating metallic wires are incidental in most of the cases, however sometimes reported in conjunction with clinical signs. There are thoracolumbar and lumbosacral transitional vertebrae present, this is considered incidental at this point in time. RECOMMENDATIONS: If the clinical signs persist, abdominal ultrasound would be recommended for further evaluation of the gastrointestinal tract and pancreas. If not available recheck 3 view abdominal radiographs followed by a complete upper GI barium study would be recommended for further evaluation. Barium may be therapeutic as well as diagnostic. If not already performed, CBC, serum chemistry and urinalysis are recommended. ** Pet discharged 1/8/22 on GI supportive meds. Returned today 1/9 for recurrence of vomiting and new melena. CBC - EPOC: pH 7.35, rest wnl Chem17 - all wnl. CBC: Overall unremarkable. decreased MCHC 31.6, Retic-HGB 19.2, mild elevated MONO 1.4, rest wnl. 3 view abdominal rads: stomach appears empty, gas in pylorus, small intestines empty. No sign of FB or obstructive pattern. metallic wire appears to be in same position as previous. Exam unremarkable aside from mild bradycardia and regurgitation noted during exam. Normothermic.

Abnormal PE/Chem/CBC/UA Results: See above.

ULTRASONOGRAPHIC EXAMINATION OF THE ABDOMEN

Urinary System

The **urinary bladder**, trigone, and pelvic urethra presented normal thicknesses and normal tone. The ureters were not visible which is normal. No uroliths or sediment were visualized, and anechoic urine was present. No evidence of inflammatory or neoplastic changes were noted. Ureteral papillae were normal.

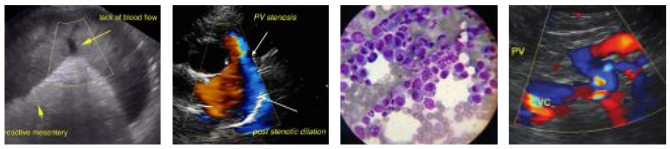

SonoPath.com
1-800-838-4268 info@sonopath.com

PATIENT
Bryce Eastwood

SPECIES
Canine

BREED
Cocker Spaniel

SEX
Neutered Male

AGE
5 Years

WEIGHT
20.1 Lbs.

INTERPRETED BY
Eric Lindquist, DMV
DABVP, Cert. IVUSS

IMAGING PERFORMED BY
Couser

HOSPITAL NAME
Willamette VH

REFERRING VET
Couser

INVOICE
13337

DATE
1/10/22

The **kidneys** revealed normal size and structure, corticomedullary definition and ratio for this age. The cortices presented largely uniform texture with normal echogenic relationship to liver and spleen. Medullary structure differed distinctly from the cortex and no evidence of pelvic dilation was present. The capsules were acceptably uniform without significant irregularities. The left kidney measured 5 cm. The right kidney measured 5 cm.

Adrenal Glands

The **left adrenal gland** was visualized and recognized as having normal shape, size, position and echogenicity for this breed. The phrenic vasculature, glandular echogenicity and detail were unremarkable. Capsule, cortex, and medullary definition were normal for this age patient. The left adrenal gland measured 0.4 cm.

The **right adrenal gland** was not visualized.

Spleen

The **spleen** presented a smooth homogeneous parenchyma hyperechoic to liver and renal cortical parenchyma. The capsule was smooth without noticeable expansion or deviation from within the spleen or adjacent pathology. The splenic vasculature demonstrated normal volume without signs of congestion or thrombosis. No sonographic evidence of acute or chronic inflammatory, neoplastic, or infarctual changes were noted. Cranial folding of the spleen was noted.

Liver

The **liver** revealed mild increased portal markings. The **gallbladder** in this patient revealed striating bile, regional inflammation of the apex and the neck of the gallbladder. The gallbladder measured 5 cm x 4 cm.

Gastrointestinal

The **stomach** was overdistended, however no overt obstruction was noted. Some retention of ingesta was noted in the stomach. The small intestine and colon were unremarkable.

Pancreas

The base and limbs of the **pancreas** were observed to be largely isoechoic to surrounding omental fat. Pancreatic duct and capsular contour were acceptably normal and parenchyma respected normal curvilinear patterns. No overt evidence of active inflammatory or neoplastic disease was noted.

ULTRASONOGRAPHIC FINDINGS

- Overdistended stomach
- Chronic cholangitis liver pattern
- Mildly inflamed gallbladder mucocele
- Splenic fold

INTERPRETATION OF THE FINDINGS & FURTHER RECOMMENDATIONS

Cholecystectomy warranted with inspection of the pyloric outflow; however, the stasis is likely secondary to mildly inflamed mucocele. Metallic wire inspection at surgery indicated, however, it is not visible on the sonogram. Gallbladder motility study could be considered to confirm necessity for cholecystectomy, however, all criteria for gallbladder mucocele is present, even though no liver enzymes are reported to be elevated. This can occur in a small percentage of clinical mucocele cases

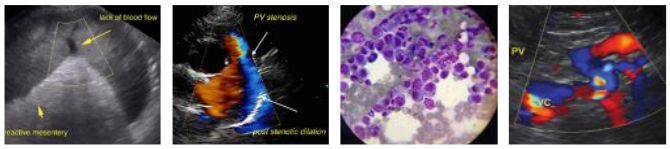

SonoPath.com
1-800-838-4268 info@sonopath.com

PATIENT

Bryce Eastwood

SPECIES

Canine

BREED

Cocker Spaniel

SEX

Neutered Male

AGE

5 Years

WEIGHT

20.1 Lbs.

INTERPRETED BY

Eric Lindquist, DMV
DABVP, Cert. IVUSS

IMAGING PERFORMED BY

Couser

HOSPITAL NAME

Willamette VH

REFERRING VET

Couser

INVOICE

13337

DATE

1/10/22

and given the breed predisposition.

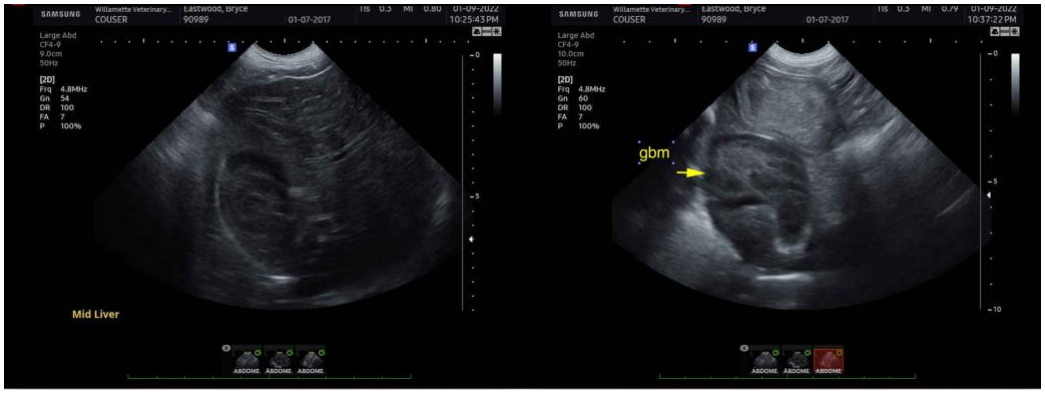

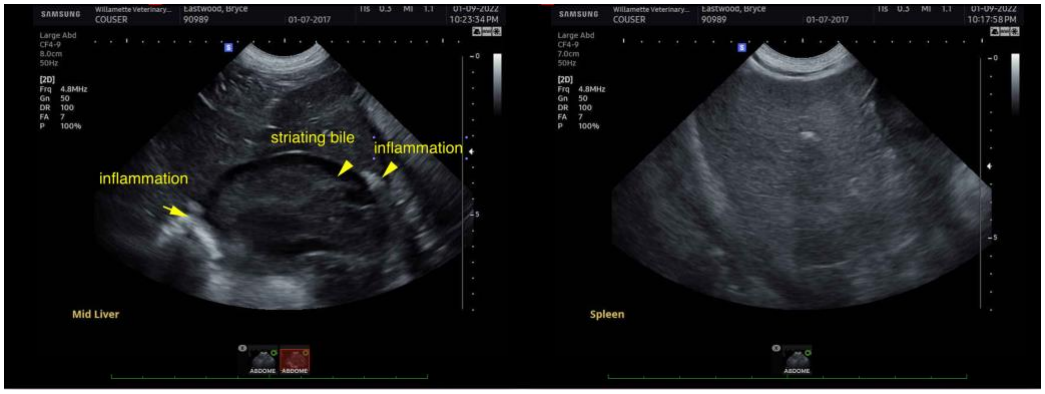

The information and recommendations provided are based on the images presented by the referring veterinarian. No evaluation can be communicated regarding pathology that was not visible in the image/video clips provided.

Thank you for this referral. If the clinical or image interpretation does not parallel your findings or if I can be of any further assistance please contact me.

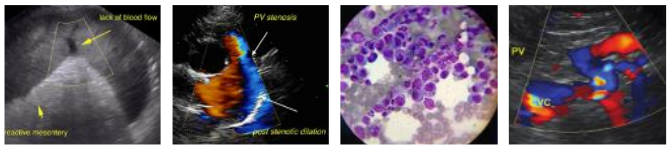

PATIENT

Bryce Eastwood

SPECIES

Canine

BREED

Cocker Spaniel

SEX

Neutered Male

AGE

5 Years

WEIGHT

20.1 Lbs.

INTERPRETED BY

Eric Lindquist, DMV DABVP, Cert. IVUSS

IMAGING PERFORMED BY

Couser

HOSPITAL NAME

Willamette VH

REFERRING VET

Couser

INVOICE

13337

DATE

1/10/22

Eric Lindquist, DMV, DABVP, Cert. IVUSS, CEO of SonoPath.com
info@SonoPath.com

Gallbladder Mucoceles

http://www.sonopath.com/GBMucocele

http://www.sonopath.com/GBMucoceleSurvey

http://www.sonopath.com/SxBiliaryDisease

Description: A gallbladder mucocele occurs when the gallbladder becomes overly distended with an excessive accumulation of mucus secondary to cystic mucosal hyperplasia. Previously, pathologists noted this finding at necropsy and considered it an incidental or age-related lesion. In the last decade, however, it has become evident that not all gallbladder mucoceles remain clinically silent and that they can in fact be associated with extrahepatic bile duct obstruction (EHBDO), cholecystitis, and gallbladder wall rupture. Approximately 50% of mucoceles may result in necrosis and rupture, typically at the neck or fundic region of the gallbladder. The etiology of these mucoceles remains unknown, but researchers suspect that it is related to disordered cholestasis and/or lipid metabolism. Suggested causes include: primary or secondary gallbladder motility disorder; dyslipidemia/hypercholesterolemia; extrahepatic bile duct obstruction; and primary or secondary disorders of mucus-producing cells, such as cystic mucosal hyperplasia of the gallbladder wall. Clinical correlation is also seen with cholangitis, cholecystitis, cholelithiasis, biliary obstruction from cholelithiasis or neoplasia, and pancreatitis. Abnormal adrenal hormones may also play a causal role in altering gallbladder mucus secretion. Hypothyroid dogs are three times more likely to develop a mucocele, and Cushinoid dogs are twenty-nine times more likely to do so. Vacuolar hepatopathy frequently co-occurs with mucoceles; practitioners are therefore advised to investigate underlying disorders associated with vacuolar hepatopathy. Bacterial infection of the gallbladder has been associated with increased mucin production in dogs; this condition may also become pathological and lead to excessive mucus accumulation. In humans, hypercortisolism is related to chronic cholecystitis and changes the biochemical composition of bile. The latter, however, was not substantiated by two studies evaluating bile composition, bacterial infection, and sludge formation during a three-month period of exogenous administration of hydrocortisone administration in dogs. There is a marked increase in the prevalence of mucocele formation in dogs with naturally occurring hyperadrenocorticism, but a definitive correlational mechanism has yet not been ascertained.

Mucoceles are most commonly seen in middle-aged to older dogs (median age of 10 years); however, researchers have reported mucocele development in dogs as young as 3 years old. Certain breeds—Miniature Schnauzers, Shetland Sheepdogs, Cocker Spaniels, Shih-tzus, Pugs, Bichon Frisés, Schipperkes, West Highland White Terriers, and Scottish Terriers—appear to be overrepresented among canine patients. Significant predisposition to mucocele formation in Shelties prompted an investigation that uncovered a specific genetic mutation in the ABCB4 gene, which functions in the translocation of phosphatidylcholine across hepatocyte cell membranes. In

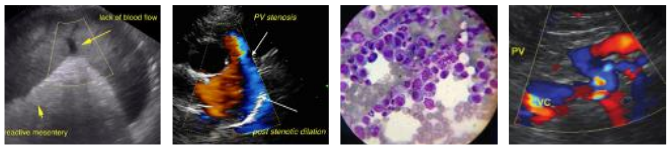

PATIENT
Bryce Eastwood

SPECIES
Canine

BREED
Cocker Spaniel

SEX
Neutered Male

AGE
5 Years

WEIGHT
20.1 Lbs.

INTERPRETED BY
Eric Lindquist, DMV DABVP, Cert. IVUSS

IMAGING PERFORMED BY
Couser

HOSPITAL NAME
Willamette VH

REFERRING VET
Couser

INVOICE
13337

DATE
1/10/22

the future, we may be able to screen young Shelties for this mutation, which would allow us to monitor gallbladder mucocele development with ultrasound over time and thereby offer early dietary and medical management, or even surgical intervention as needed. Felines are less commonly affected.

Clinical Signs: According to several retrospective studies, the most common clinical signs include vomiting (87%), abdominal pain (87%), anorexia (78%), lethargy, icterus (57%), and fever (26%). The average duration of illness is 5 days. Focal pain upon examining the gallbladder is common and referred to as a positive Murphy sign. Patients may also be asymptomatic, despite biochemical abnormalities, even in the face of ultrasonographic evidence of a mucocele. Patients with fully formed mucoceles are at risk of further complications, such as gallbladder rupture, peritonitis, sepsis, and related coagulopathies, and should be considered for surgical intervention.

Diagnostics: Biochemical analyses may indicate leukocytosis, with or without a left shift, and most commonly reveal elevated hepatic enzymes (SAP 100%, GGT 86%, ALT 77%, AST 60%) and bilirubin (63%). Ultrasonographic findings may include: a distended gallbladder with centrally suspended luminal content and a hypoechoic intraluminal rim; a thickened gallbladder wall; intraluminal stellate; echogenic striations (the “kiwi fruit sign”); and/or the presence of non-dependent intraluminal contents or sludge. (Note: The presence of the “kiwi fuit sign” is not essential for the diagnosis of a gall bladder mucocele, as many mucocele variations do not demonstrate a complete stellate pattern.) A hypoechoic ring seen around the gallbladder may indicate wall edema or early rupture. Presence of free fluid, as well as localized, echogenic hepatic parenchyma and intra-abdominal fat, are also consistent with bile leakage and peritonitis. Pain is often noted upon interrogation of the area. Dilation of the common bile duct may also be present.

Since there exists an association between hypercholesterolemia/hyperlipidemia and gallbladder mucoceles, patients that exhibit both should be screened for hypothyroidism, adrenal hyperplasia syndromes (Cushing’s disease and sex hormone dysregulation), diabetes mellitus, pancreatitis, exogenous exposure to glucocorticoids, and necroinflammatory liver disease.

Treatment: Surgical intervention is recommended due to the significant risk of peritonitis and sepsis associated with rupture, and since medical management on its own may not be effective. Candidates for surgery must be adequately stabilized prior to surgery, and a coagulation panel should be assessed beforehand. Use of ursodeoxycholic acid (Actigall) is not recommended if any sonographic aspects of wall inflammation or emergent perforation are present. Percutaneous centesis of the gallbladder is also not advised in the presence of a mucocele. Some studies that have investigated a relatively small number of dogs have found medical therapy with Actigall and SAMe to be somewhat effective at a very early subclinical stage. Yet, there are no definitive guidelines for ascertaining whether certain sonographic or laboratory findings permit the differentiation of a clinically significant mucocele versus a non-clinical, stable mucocele that may become clinically significant in the future. For this reason, each patient must be assessed individually. It may be the case that very dramatic mucoceles do not cause any overt clinical signs, whereas other patients may have minor mucoceles that lead to significant clinical signs and necessitate urgent cholecystectomy to avoid the onset of bile peritonitis due to rupture. It is generally advised that dogs with clinical signs, elevated liver enzymes, elevated WBC counts, and sonographic evidence of a mucocele be treated surgically. However, if a clinically silent mucocele

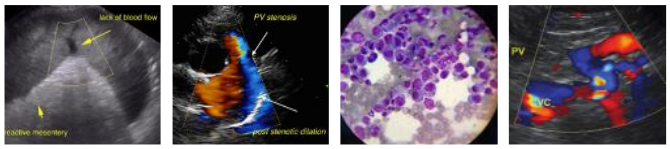

PATIENT

Bryce Eastwood

SPECIES

Canine

BREED

Cocker Spaniel

SEX

Neutered Male

AGE

5 Years

WEIGHT

20.1 Lbs.

INTERPRETED BY

Eric Lindquist, DMV
DABVP, Cert. IVUSS

IMAGING PERFORMED BY

Couser

HOSPITAL NAME

Willamette VH

REFERRING VET

Couser

INVOICE

13337

DATE

1/10/22

is found incidentally on ultrasound, careful observation and monitoring is reasonable, provided there are no underlying diseases that may promote degradation (e.g., hyperadrenocorticism). Owners should be instructed to carefully monitor their pets for the development of clinical signs that may signal progression of the disease.

Antibiotic therapy directed towards gram-negative, enteric bacteria (i.e., *E. coli, Klebsiella, Enterobacter*, etc.) and anaerobic bacteria is indicated, and will likely be necessary for several weeks following surgery. Culture and sensitivity results should guide long-term treatment. Cholecystectomy with a possible bile duct transposition is the procedure of choice. The bile duct is often flushed to remove sludge and debris to help avoid post-surgical obstruction. Cholecystotomy for removing gallbladder contents is not advised as studies have shown that mucocele concretions have reformed in several dogs treated in this manner. At the time of surgery, one should obtain liver biopsies as well as submit cultures and sensitivity of the gallbladder contents. Liver biopsies may show normal tissue, cholangiohepatitis, biliary hyperplasia, vacuolar hepatopathy, or mild to moderate portal hepatitis/fibrosis with bile duct proliferation. Ultrasound-guided cholecystocentesis is not recommended in dogs with mature mucoceles due to the risk of gallbladder rupture and seeding the abdomen with bacteria. Rupture of the gallbladder constitutes a surgical emergency and carries a worse prognosis for survival. Several investigators have noted that, upon surgical exploration of asymptomatic mucocele patients, there is evidence of prior localized peritonitis and fibrosis, likely resulting from tears in the gallbladder's neck, which lead to minute amounts of bile leakage.

Conclusion: Possible etiological explanations for gallbladder mucoceles are quite varied, and underlying diseases must be treated. The treatment of choice is cholecystectomy, with surgical intervention especially recommended for patients with clinical signs or significantly elevated liver enzymes so as to avoid gallbladder rupture and subsequent peritonitis.

References:

Aguirre AL, Center SA, Randolph JF, et al. Gallbladder disease in Shetland Sheepdogs: 38 cases (1995-2005). *J Am Vet Med Assoc* 2007;231(1):79-88.

Besso JG, Wrigley RH, Gliatto JM, Webster CR. Ultrasonographic appearance and clinical findings in 14 dogs with gallbladder mucocele. *Vet Radiol Ultrasound* 2000;41(3):261-71.

Cornejo L, Webster CRL. Canine gallbladder mucoceles. *Compend Contin Educ Vet* 2005;27:912-30.

Crews LJ, Feeney DA, Jessen CR, et al. Clinical, ultrasonographic, and laboratory findings associated with gallbladder disease and rupture in dogs: 45 cases (1997-2007). *J Am Vet Med Assoc* 2009;234(3):359-66.

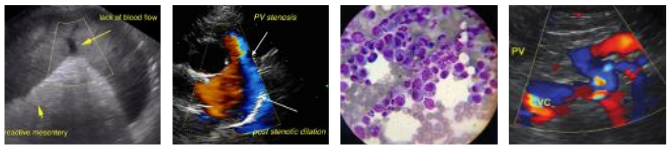

PATIENT

Bryce Eastwood

SPECIES

Canine

BREED

Cocker Spaniel

SEX

Neutered Male

AGE

5 Years

WEIGHT

20.1 Lbs.

INTERPRETED BY

Eric Lindquist, DMV
DABVP, Cert. IVUSS

IMAGING PERFORMED BY

Couser

HOSPITAL NAME

Willamette VH

REFERRING VET

Couser

INVOICE

13337

DATE

1/10/22

Kook PH, Schellenberg S, Grest P, et al. Microbiologic evaluation of gallbladder bile of healthy dogs and dogs with iatrogenic hypercortisolism: a pilot study. *J Vet Intern Med* 2010;24(1):224-28.

Kook PH, Schellenberg S, Rentsch KM, et al. Effects of iatrogenic hypercortisolism on gallbladder sludge formation and biochemical bile consitituents in dogs. *Vet J* 2012;191(2):225-30.

Malek S, Sinclair E, Hosgood G, et al. Clinical findings and prognostic factors for dogs undergoing cholecystectomy for gallbladder mucocele. *Vet Surg* 2013;42(4):418-26.

Mealey KL, Minch JD, White SN, et al. An insertion mutation in ABCB4 is associated with gallbladder mucocele formation in dogs. *Comp Hepatol* 2010;9:6.

Mehler SJ, Bennett RA. Canine Extrahepatic Biliary Tract Disease and Surgery. *Compend Contin Educ Vet* 2006;28(4):302-15.

Pike FS, Berg J, King NW, et al. Gallbladder mucocele in dogs: 30 cases (2000-2002). *J Am Vet Med Assoc* 2004;224(10):1615-22.

Walter R, Dunn ME, d'Anjou MA, L'Écuyer M. Nonsurgical resolution of gallbladder mucocele in two dogs. *J Am Vet Med Assoc* 2008;232(11):1688-93.

Worley DR, Hottinger HA, Lawrence HJ. Surgical management of gallbladder mucoceles in dogs: 22 cases (1999-2003). *J Am Vet Med Assoc* 2004;225(9):1418-22.