

**DATE**

1/10/22

**PRESENTING CLINICAL SIGNS**

History: Weight loss 12.12 lbs in August. Now 8.15 lbs. Not eating or drinking as much.

Current Medications: Mirtazapine 7.5 mg 1/2 tablet every 72 hours.

Lab Results: Attached separately.

**PATIENT**

Blessing Wolff

Date of Previous IntraPet Ultrasound: No previous IntraPet scans.

Sedation: Not required to complete full diagnostic ultrasound.

Stat Report: Not requested.

Imaging Performed By: Rachel Brillhart, RDMS.

**SPECIES**

Feline

**ULTRASONOGRAPHIC EXAMINATION OF THE ABDOMEN****Urinary System**

The **urinary bladder**, trigone, and pelvic urethra presented normal thicknesses and normal tone. The ureters were not visible which is normal. No uroliths or sediment were visualized and anechoic urine was present. No evidence of inflammatory or neoplastic changes was noted. Ureteral papillae were normal.

**BREED**

Domestic Shorthair

**SEX**

Spayed Female

The **kidneys** revealed largely normal size and structure, corticomedullary definition and ratio (cortex 1/3 of medulla) were essentially maintained with some age-related loss of curvilinear patterns regarding the capsule and C/M junction. The cortices presented largely uniform texture with some increased echogenicity expected for this age patient. Medullary structure differed distinctly from that of the cortex and no evidence of pelvic dilation was present. The right kidney measured 3.98 cm. The left kidney measured 3.57 cm.

**AGE**

7/11

**Adrenal Glands**

Both **adrenal glands** were visualized and recognized as having normal shape, size, position and echogenicity for this breed. The phrenic vasculature, glandular echogenicity and detail were unremarkable. Capsule, cortex, and medullary definition were normal for this age patient. The left adrenal gland measured 0.51 cm. The right adrenal gland measured 0.49 cm.

**WEIGHT**

8.15 lbs

**INTERPRETED BY**

Eric Lindquist, DMV  
DABVP, Cert. IVUSS

**Spleen**

The **spleen** presented a smooth homogeneous parenchyma hyperechoic to liver and renal cortical parenchyma. The capsule was smooth without noticeable expansion or deviation from within the spleen or adjacent pathology. The splenic vasculature demonstrated normal volume without signs of congestion or thrombosis. No sonographic evidence of acute or chronic inflammatory, neoplastic, or infarctual changes was noted.

**HOSPITAL NAME**

Glen Burnie AH

**REFERRING VET**

Dr. Shah

**Liver**

The **liver** is diffusely hyperechoic to the falciform fat. The liver also revealed coarse architecture. The gallbladder and common bile duct were normal. There was no evidence of post hepatic obstruction. Minor biliary gallbladder debris was noted.

**INVOICE**

95088

**Gastrointestinal**

The **gastrointestinal** presentation revealed mild uniform prominence of the gastric mucosa as well as areas of "ropey" small intestinal wall. The muscularis layer was hypertrophied inverting the normal ratio (1:3). The intestinal submucosa was slightly irregular, thickened and hyperechoic suggestive of low grade, chronic inflammation. No evidence of obstruction was present. Chronic inflammatory bowel disease is probable with a low possibility of an early neoplastic event such as lymphoma or, less likely, dry form FIP can at times be found on biopsy of these presentations. Full thickness tissue biopsies via open laparotomy, ideally guided by intraoperative ultrasound in order to obtain the most representative mural sample, would be necessary to rule more significant disease than IBD.

### **Pancreas**

The base and limbs of the **pancreas** were observed to be largely isoechoic to surrounding omental fat. Pancreatic duct and capsular contour were acceptably normal and parenchyma respected normal curvilinear patterns. No overt evidence of active inflammatory or neoplastic disease was noted.

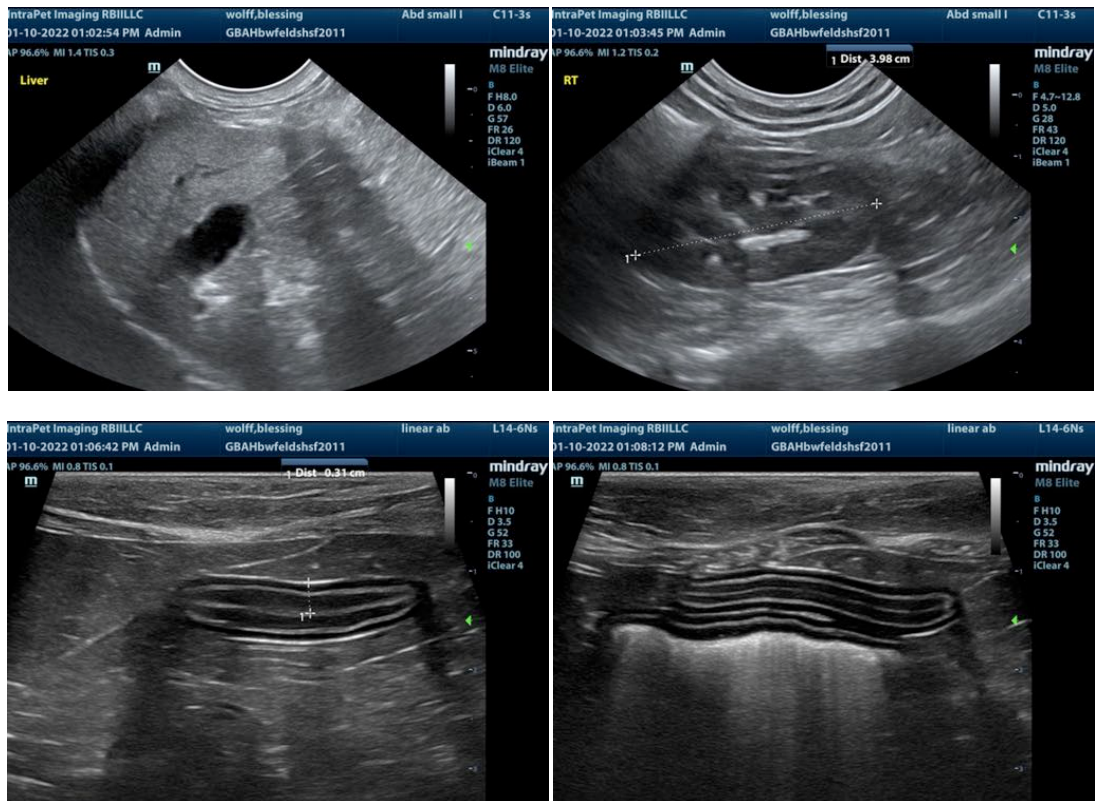
### **ULTRASONOGRAPHIC FINDINGS**

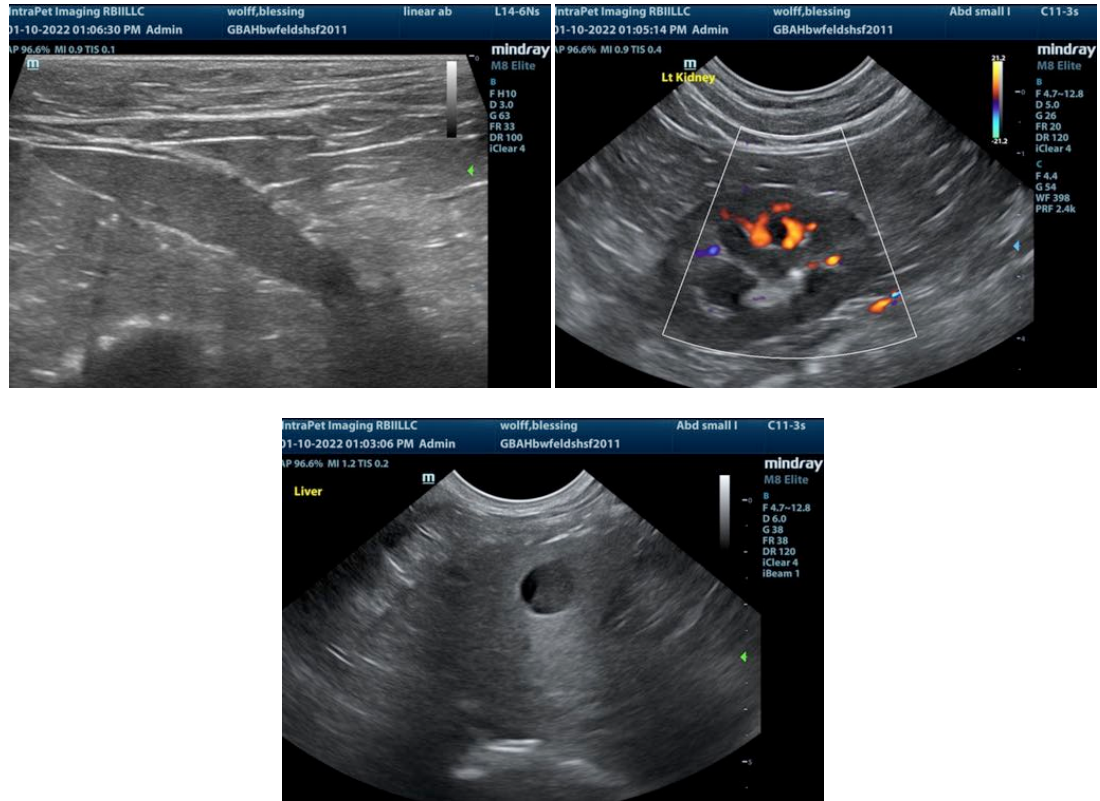
Hepatic lipidosis pattern with minor remodeling.

Mild IBD gastrointestinal pattern. This is most consistent with idiopathic muscularis hypertrophy, likely associated with history of inflammatory bowel.

### **INTERPRETATION OF THE FINDINGS & FURTHER RECOMMENDATIONS**

Ultrasound-guided FNA of the liver is warranted to ensure that the lipidosis is present without more significant disease.





The information and recommendations provided are based on the images presented by the referring veterinarian. No evaluation can be communicated regarding pathology that was not visible in the image/video clips provided.

Thank you for this referral. If the clinical or image interpretation does not parallel your findings or if I can be of any further assistance please contact me.

**Eric Lindquist**, DMV, DABVP, Cert. IVUSS, CEO of SonoPath.com  
Eric.Lindquist@SonoPath.com