

**DATE**

1/10/22

PRESENTING CLINICAL SIGNS

History: Elevated ALKP with normal ALT/GGT.

Current Medications: Gabapentin 300mg (1 tablet PO every 8-12 hours); Rimadyl 100mg (1 tablet PO BID).

Lab results: Attached separately.

PATIENT

Blanco Royer

Date of Previous IntraPet Ultrasound: No previous IntraPet scans.

Sedation: IV Buprenorphine.

Stat Report: Not requested.

SPECIES

Canine

Imaging Performed By: Rachel Brillhart, RDMS.

BREED

Belgian Malinois

ULTRASONOGRAPHIC EXAMINATION OF THE ABDOMEN**Urinary System**

The **urinary bladder**, trigone, and pelvic urethra presented normal thicknesses and normal tone. The ureters were not visible which is normal. No uroliths or sediment were visualized and anechoic urine was present. No evidence of inflammatory or neoplastic changes was noted. Ureteral papillae were normal.

SEX

Neutered male

The **kidneys** revealed normal size and structure, corticomedullary definition and ratio for this age. The cortices presented largely uniform texture with normal echogenic relationship to liver and spleen. Medullary structure differed distinctly from the cortex and no evidence of pelvic dilation was present. The capsules were acceptably uniform without significant irregularities. An anechoic cyst was noted in the cranial pole of the right kidney. The right kidney measured 8.21 cm. The left kidney measured 8.3 cm.

AGE

11/8/07

WEIGHT

104 lbs

Adrenal Glands

Both **adrenal glands** were visualized and recognized as having largely normal shape, size, position and acceptable echogenicity for this age group and breed. Some heterogeneity was noted within the adrenal parenchyma without concerning capsular distortion. These changes are likely age related but should be monitored by sonogram should the patient be suspected of having adrenal disease. The right adrenal gland measured 3.22 x 0.97 cm at the caudal pole and 1.07 cm at the cranial pole. The left adrenal gland measured 2.67 x 0.74 cm at the caudal pole and 0.7 cm at the cranial pole.

INTERPRETED BYEric Lindquist, DMV
DABVP, Cert. IVUSS**HOSPITAL NAME**

Lake Shore AH

Spleen

The **spleen** was slightly enlarged with multi-focal, moderately disruptive, hypoechoic nodular changes. The largest of which measured 2.29 x 1.86 cm.

REFERRING VET

Dr. Anderson

Liver

The **liver** images from right and left intercostal as well as subcostal views revealed subjectively normal liver size, contour, and structure. Heterogenous parenchymal changes were noted. Vascular and biliary tracts were of normal volume and no evidence of congestion was noted. The gallbladder presented some dependent debris with essentially normal contour. The cystic and common bile ducts were normal. No overt evidence of active inflammatory, infiltrative or regenerative pathology was noted but should be paired with current or past LE elevations regarding any clinical significance to this presentation. The hepatic lymph nodes were unremarkable.

INVOICE

95090

Gastrointestinal

Examination of the **gastrointestinal tract** revealed a stomach and intestine free of stasis, of normal wall thickness, acceptable curvilinear mural detail, and peristaltic activity. Small and large intestine demonstrated

normal luminal chyme and stool consistency respectively. No obstructive or overt infiltrative disease was noted. No associated abnormal lymphatic activity was noted.

Pancreas

The **pancreas** was enlarged in the right limb and measured 2.3 cm and was coarse with hypoechoic parenchyma. The pancreatic contour was undulating.

Heart

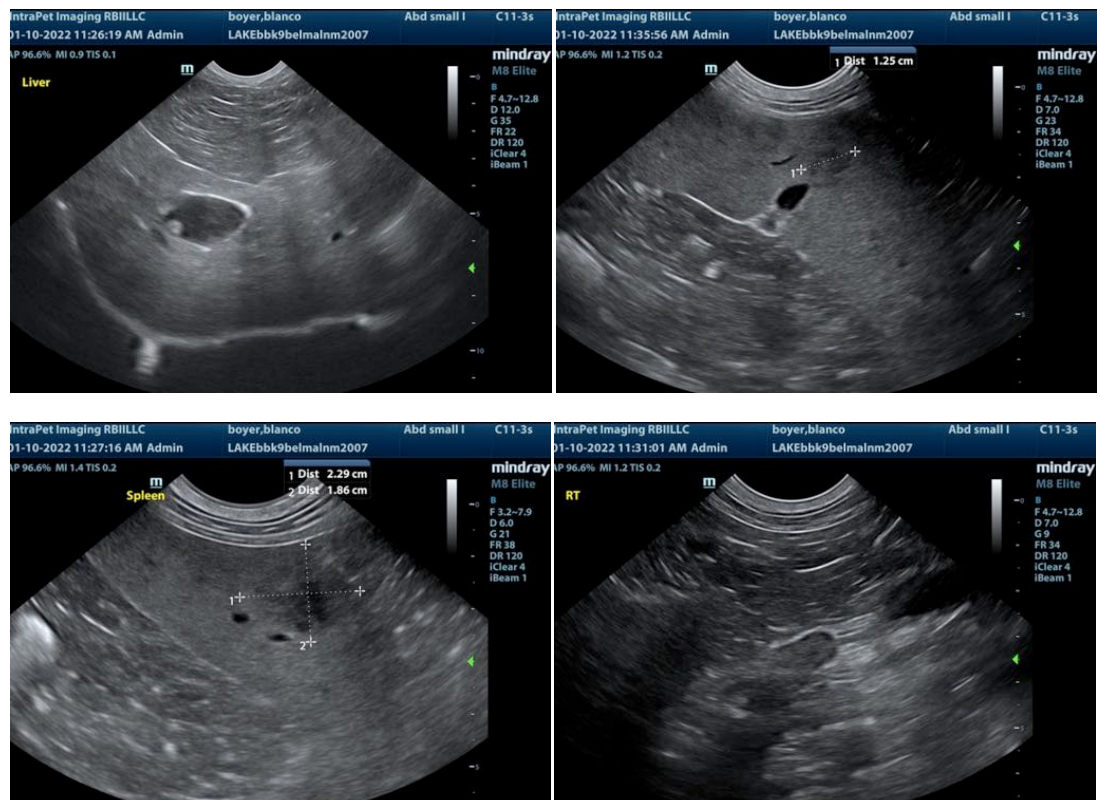
Rapid view of the heart revealed no evidence of pathology.

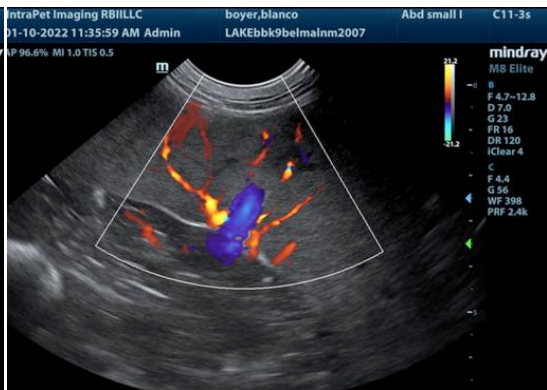
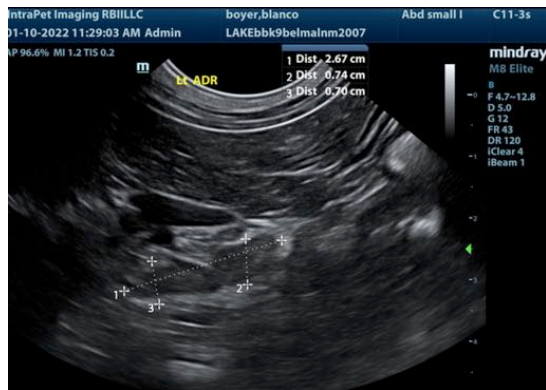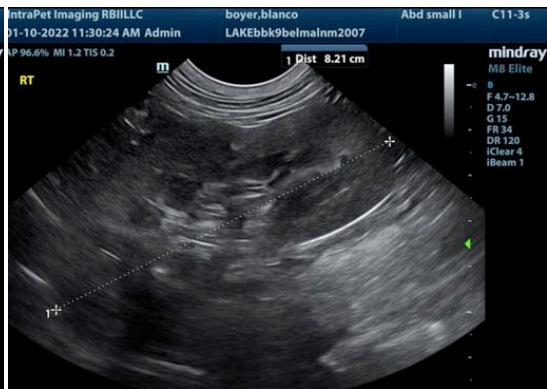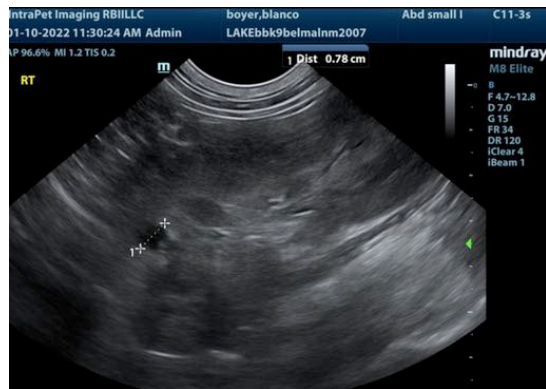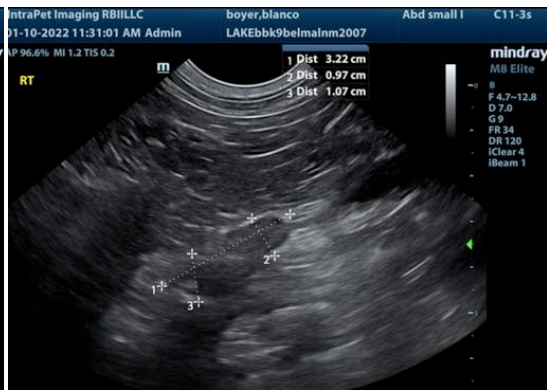
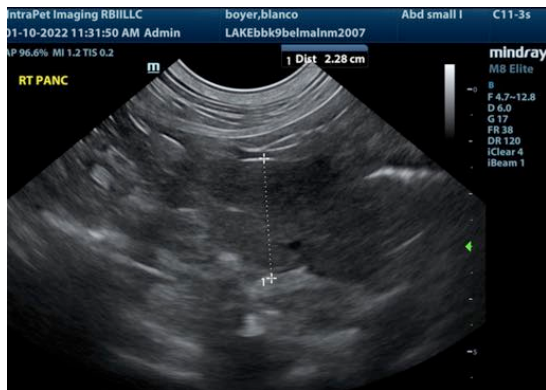
ULTRASONOGRAPHIC FINDINGS

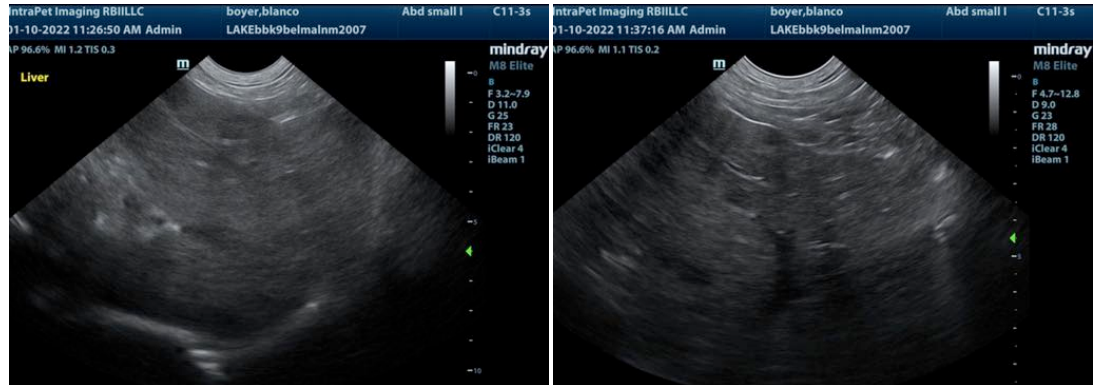
Undefined nodular splenic changes. Emerging round cell neoplasia, pronounced nodular hyperplasia or hemangiosarcoma are possible.
Heterogenous hepatic changes.
Prominent pancreas.
Otherwise, geriatric abdomen.

INTERPRETATION OF THE FINDINGS & FURTHER RECOMMENDATIONS

Ultrasound-guided 25-gauge FNA of the spleen and liver is recommended or direct splenectomy given the breed predisposition to splenic pathology. The changes may be benign; however, there are particular nodules in the spleen that are concerning.







The information and recommendations provided are based on the images presented by the referring veterinarian. No evaluation can be communicated regarding pathology that was not visible in the image/video clips provided.

Thank you for this referral. If the clinical or image interpretation does not parallel your findings or if I can be of any further assistance please contact me.

Eric Lindquist, DMV, DABVP, Cert. IVUSS, CEO of SonoPath.com
Eric.Lindquist@SonoPath.com