

PATIENT

Lucy Iacono

SPECIES

Canine

BREED

Jack Russell Terrier

SEX

Spayed Female

AGE

9 Years 1 Month

WEIGHT

14.6 pounds

INTERPRETED BY

Camden Rouben DVM,
DACVIM (Cardiology)

IMAGING PERFORMED BY

Vincent Ravancho CVT

HOSPITAL NAME

Sova Animal Hospital

REFERRING VET

Dr. Dodson

INVOICE

15466

DATE

04/24/26

PRESENTING CLINICAL SIGNS

Grade II/VI L systolic Heart murmur, pre-op echo. Has Uroliths - needs cystotomy.

Abnormal PE/Chem/CBC/UA Results: U/A - Hematuria, WBCs, >100 Cocci, culture pending.

ULTRASONOGRAPHIC EXAMINATION OF THE HEART

CANINE CARDIAC PARAMETERS	MR VMAX (m/s)	TR VMAX (m/s)	LA/AO (M-Mode)	LA/AO (Heart Base; Swe)	FS (%)	EF (%)	EPSS (cm)
NORMAL PARAMETER	4.5-5.5	<2.7	1.3	Up to 1.6	28-40	40-100	<0.6
PATIENT	5.76	--	1.19	0.96	41.94	74.67	0.33
CANINE CARDIAC PARAMETERS	HR (BPM)	AV VMAX (m/s)	PV MAX (m/s)	BODY WEIGHT (kg)	LAD LA MAX 4 Chamber	LVIDd Avg; 2D and m-mode short axis (cm)	LVIDs Avg; 2D and m-mode short axis (cm)
NORMAL PARAMETER	50-100	0.7-1.7	0.7-1.6				
PATIENT	NM	1.78	1.04	6.64	2.85	2.84	1.65

Cardiac Presentation

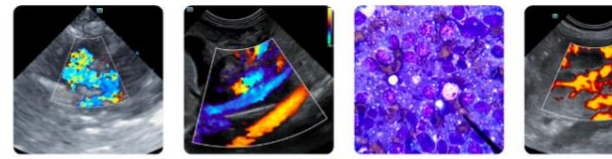
The mitral valve leaflets are mildly thickened with mild mitral regurgitation posteriorly directed. Left atrial size is subjectively normal. The left ventricular internal dimensions during diastole are at the high end of normal limits. The systolic function is preserved in the face of mitral regurgitation. There's normal right atrial size without tricuspid regurgitation. There's no prolapse of the tricuspid valve leaflets. No evidence of pulmonary hypertension based off of the tricuspid regurgitant velocities. The right ventricle subjectively appears normal in structure and function. The aortic and pulmonic valves have normal morphology and the corresponding outflow velocities are within normal limits. There's no evidence of pulmonic or aortic insufficiency. The aorta appears normal. The pulmonary artery and associated branches appear normal. There's no evidence of pleural effusion, pericardial effusion, or intracardiac masses.

ULTRASONOGRAPHIC FINDINGS

- Based off the images provided, this patient has degenerative valve disease ACVIM stage B1 affecting the mitral valve.

INTERPRETATION OF THE FINDINGS & FURTHER RECOMMENDATIONS

There are no cardiac medications indicated at this time. Since this can be a progressive condition, serial monitoring is recommended. A blood pressure assessment is recommended in this patient. A recheck echocardiogram is recommended in six months. A sooner recheck is recommended if the



PATIENT

Lucy Iacono

patient develops cardiovascular clinical signs, such as increase in a resting respiratory rate effort greater than 30 to 45 breaths per minute when resting or sleeping. If breathing rates are increasing, then thoracic radiographs are recommended.

SPECIES

Canine

If the heart murmur worsens in intensity, a sooner recheck is recommended as well. Elective anesthetic procedures should be well tolerated. Standard perioperative fluid rates should remain judicious.

BREED

Jack Russell Terrier

Medications like dexmedetomidine and other alpha-2 agonists are best avoided. Ketamine is also best avoided. If needed, anticholinergics can be used in the case of a clinically significant bradyarrhythmia.

SEX

Spayed Female

Activity restriction is not warranted in this patient.

AGE

9 Years 1 Month

WEIGHT

14.6 pounds

INTERPRETED BY

Camden Rouben DVM, DACVIM (Cardiology)

IMAGING PERFORMED BY

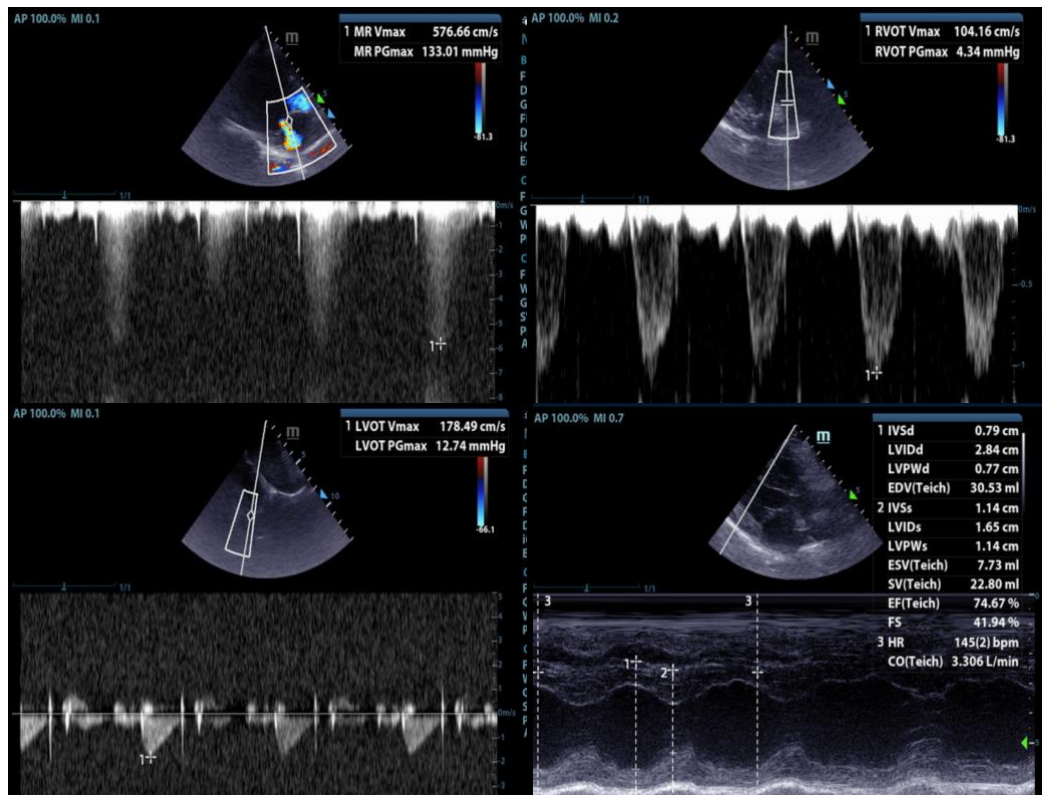
Vincent Ravancho CVT

HOSPITAL NAME

Sova Animal Hospital

REFERRING VET

Dr. Dodson



INVOICE

15466

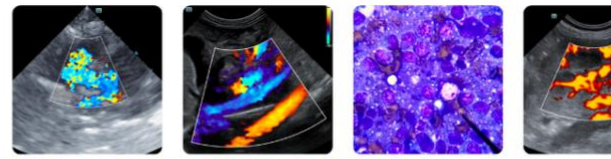
The information and recommendations provided are based on the images presented by the referring veterinarian/sonographer. No evaluation can be communicated regarding pathology that was not visible in the image/video clips provided.

DATE

04/24/26

Thank you for this referral. If the clinical or image interpretation does not parallel your findings or if I can be of any further assistance please contact me.

Camden Rouben DVM, DACVIM (Cardiology)



PATIENT

info@SonoPath.com

Lucy Iacono

SPECIES

Canine

BREED

Jack Russell Terrier

SEX

Spayed Female

AGE

9 Years 1 Month

WEIGHT

14.6 pounds

INTERPRETED BY

Camden Rouben DVM,
DACVIM (Cardiology)

**IMAGING
PERFORMED BY**

Vincent Ravancho CVT

HOSPITAL NAME

Sova Animal Hospital

REFERRING VET

Dr. Dodson

INVOICE

15466

DATE

04/24/26