

PATIENT

Harley Marion

SPECIES

Feline

BREED

DSH

SEX

Neutered Male

AGE

14 Years 7 Months

WEIGHT

12.1 pounds

INTERPRETED BY

Camden Rouben,
DVM, DACVIM
(Cardiology)

IMAGING PERFORMED BY

Kathleen Byrnes

HOSPITAL NAME

Harmony Heights
Animal Hospital

REFERRING VET

Dr. Sechrist

INVOICE

14630

DATE

03/26/26

PRESENTING CLINICAL SIGNS

- La/AO 1.4-2.1, MR, P on topical Plavix- Owner cannot medicate. No symptoms.

ULTRASONOGRAPHIC EXAMINATION OF THE HEART

| FELINE CARDIAC PARAMETERS | BODY WEIGHT (lbs) | HR (BPM) | IVSd (cm) | LVIDd (cm) | LVWd (cm) | FS (%) | EF (%) |
|--|-------------------|---------------------------|----------------------|-----------------|-----------------|-----------|--------|
| NORMAL PARAMETER | ----- | 150-240 | 0.3-0.6 | 1.0-2.1 | 0.25-0.6 | 35-67 | 80-100 |
| PATIENT | 12.1 | 199 | 6.0 mm | 1.52 | 7.8 mm | 52.89 | 86.85 |
| FELINE CARDIAC PARAMETERS | LA/AO (M-mode) | LA/AO HEART BASE (Sisson) | LAD LA MAX 4 Chamber | LVOT VEL. (m/s) | RVOT VEL. (m/s) | IVRT (m/) | |
| NORMAL PARAMETER | <1.5 | 1.6 | 0.7-1.7 | <1.6 | <1.3 | 40-60 | |
| PATIENT | 2.11 | 1.7 | 6.0 mm | 1.57 | 1.1 | NM | |
| Adapted from June Boon, Veterinary Echocardiography, 1998 Sisson D et al. JVIM 1991; 5: 232, Jacobs et al. Am J Vet Res 1985; 46:1705 | | | | | | | |

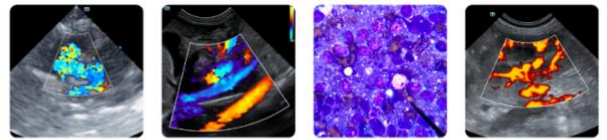
Cardiac Presentation

The mitral valve leaflets are normal and there is mild eccentric mitral regurgitation. There is no prolapse of the mitral valve leaflets. The left atrial size is equivocal to mildly increased. The left ventricular systolic function appears preserved. The left ventricular diastolic dimensions are subjectively within normal limits. There is evidence of systolic anterior motion of the mitral valve. There is a kissing lesion at the level of the systolic anterior motion in the left ventricular myocardium and appears hyperechoic in some regions. The left ventricular walls measure hypertrophy. There is normal right atrial size without evidence of tricuspid regurgitation. There is no prolapse of the tricuspid valve leaflets. No evidence of pulmonary hypertension on the images provided. Right ventricle appears normal in structure and function subjectively. The aortic and pulmonic valves have normal morphology and the corresponding outflow velocities are within normal limits. There is no evidence of pulmonic or aortic insufficiency. The aortic appears normal. The pulmonary artery and associated branches appear normal. There is no evidence of pleural effusion, paracardial effusion, or intracardiac masses based off of the images provided.

ULTRASONOGRAPHIC FINDINGS

- Based off of the images provided, this patient continues to have hypertrophic obstructive cardiomyopathy phenotype with mitral regurgitation and equivocal to mild left atrial enlargement, ACVIM stage B2.

INTERPRETATION OF THE FINDINGS & FURTHER RECOMMENDATIONS



PATIENT

Harley Marion

Based off of the images and the interpretation, this patient has static evidence of left ventricular concentric hypertrophy classified as stage B2. If not already performed, it is recommended to ensure that the patient's blood pressure is normal and that the patient is euthyroid.

SPECIES

Feline

Clopidogrel therapy at 18.75 mg by mouth every 24 hours is recommended. Oral therapy is reported to be more effective than transdermal therapies to help reduce the risk of blood clot. Since this can be a progressive condition, serial monitoring is recommended. It is recommended to recheck echocardiogram as performed in six months or sooner if the patient develops cardiovascular clinical signs. Recommend obtaining a blood pressure on the patient and ensure it is less than 160 mm of mercury systolic. If the blood pressure is elevated, recommend following ACVIM guidelines for systemic hypertension and treating if indicated.

BREED

DSH

SEX

Neutered Male

AGE

14 Years 7 Months

WEIGHT

12.1 pounds

INTERPRETED BY

Camden Rouben,
DVM, DACVIM
(Cardiology)

IMAGING PERFORMED BY

Kathleen Byrnes

HOSPITAL NAME

Harmony Heights
Animal Hospital

REFERRING VET

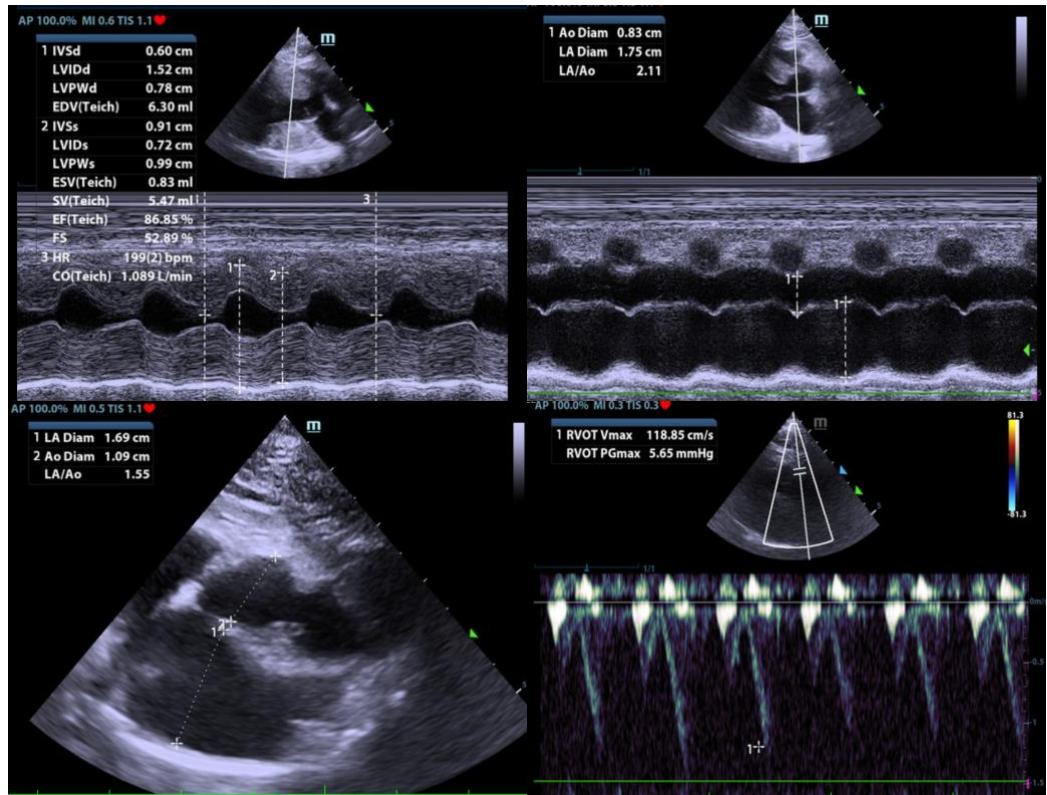
Dr. Sechrist

INVOICE

14630

DATE

03/26/26

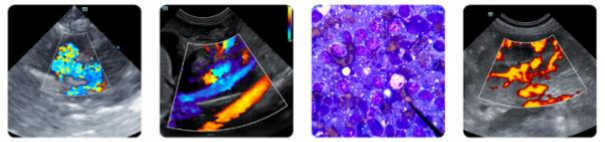


The information and recommendations provided are based on the images presented by the referring veterinarian/sonographer. No evaluation can be communicated regarding pathology that was not visible in the image/video clips provided.

Thank you for this referral. If the clinical or image interpretation does not parallel your findings or if I can be of any further assistance please contact me.

Camden Rouben, DVM, DACVIM (Cardiology)

info@SonoPath.com



PATIENT

Harley Marion

SPECIES

Feline

BREED

DSH

SEX

Neutered Male

AGE

14 Years 7 Months

WEIGHT

12.1 pounds

INTERPRETED BY

Camden Rouben,
DVM, DACVIM
(Cardiology)

**IMAGING
PERFORMED BY**

Kathleen Byrnes

HOSPITAL NAME

Harmony Heights
Animal Hospital

REFERRING VET

Dr. Sechrist

INVOICE

14630

DATE

03/26/26