



**PATIENT**

Nessi Becerra

**SPECIES**

Canine

**BREED**

Pitbull Mix

**SEX**

Spayed Female

**AGE**

11 Years 2 Months

**WEIGHT**

74.6 Pounds

**INTERPRETED BY**

Camden Rouben DVM,  
DACVIM (Cardiology)

**IMAGING PERFORMED BY**

Rebecca Hamilton

**HOSPITAL NAME**

Englewood VC

**REFERRING VET**

Dr. Ezik

**INVOICE**

35096

**DATE**

12/26/25

**PRESENTING CLINICAL SIGNS**

History: Newly diagnosed grade 2 HM

**ULTRASONOGRAPHIC EXAMINATION OF THE HEART**

<b>CANINE CARDIAC PARAMETERS</b>	<b>MR VMAX (m/s)</b>	<b>TR VMAX (m/s)</b>	<b>LA/AO (M-Mode)</b>	<b>LA/AO (Heart Base; Swe)</b>	<b>FS (%)</b>	<b>EF (%)</b>	<b>EPSS (cm)</b>
<b>NORMAL PARAMETER</b>	4.5-5.5	<2.7	1.3	Up to 1.6	28-40	40-100	<0.6
<b>PATIENT</b>	5.54	--	1.41	1.27	34.27	63.4	NM
<b>CANINE CARDIAC PARAMETERS</b>	<b>HR (BPM)</b>	<b>AV VMAX (m/s)</b>	<b>PV MAX (m/s)</b>	<b>BODY WEIGHT (kg)</b>	<b>LAD LA MAX 4 Chamber</b>	<b>LVIDd Avg; 2D and m-mode short axis (cm)</b>	<b>LVIDs Avg; 2D and m-mode short axis (cm)</b>
<b>NORMAL PARAMETER</b>	50-100	0.7-1.7	0.7-1.6				
<b>PATIENT</b>	117	1.51	1.1	33.9	--	4.48	2.95

**Cardiac Presentation**

The mitral valve leaflets are mildly thickened with mild mitral regurgitation posteriorly directed. There is no prolapse of the mitral valve leaflet. The left atrial size is normal. Left ventricular internal dimensions during diastole are within normal limits and systolic function is preserved in the face of mitral regurgitation. There is normal right atrial size without tricuspid regurgitation. There is no prolapse of the tricuspid valve leaflets. The right ventricle subjectively appears normal in structure and function. The aortic and pulmonic valves have normal morphology and the corresponding outflow velocities are within normal limits. There is no evidence of pulmonic or aortic insufficiency. The aorta appears normal. The pulmonary artery and associated branches appear normal. There is no evidence of pleural effusion, pericardial effusion, or intracardiac masses.

**ULTRASONOGRAPHIC FINDINGS**

- Based on the images provided, this patient has evidence of degenerative valve disease, ACVIM stage B-1

**INTERPRETATION OF THE FINDINGS & FURTHER RECOMMENDATIONS**

The patient has evidence of degenerative valve disease ACVIM stage B1 and no cardiac medications are indicated at this time. Since this can be a progressive condition, serial monitoring is recommended. A recheck echocardiogram is recommended in 9-12 months. A sooner recheck is recommended if the patient develops cardiovascular clinical signs or the heart murmur is worsening in intensity. Elective



**PATIENT**

anesthetic procedures should be well tolerated.

Nessi Becerra

If not already doing so, the resting respiratory rate should be monitored to be < 35-40 breathes/minute when the patient is resting or sleeping. If the breathing rates are increasing, then chest xrays are recommended.

**SPECIES**

Canine

Recommend obtaining a blood pressure on the patient to ensure it is <160mmHg systolic.

**BREED**

Pitbull Mix

Standard perioperative fluid rates should be well-tolerated. Medications like dexmedetomidine and other alpha 2 agonists are best avoided. Ketamine is also best avoided. Anticholinergics can be used in the case of a clinically significant bradyarrhythmia.

**SEX**

Spayed Female

Activity restriction is not warranted in this patient.

**AGE**

11 Years 2 Months

**WEIGHT**

74.6 Pounds

**INTERPRETED BY**

Camden Rouben DVM,  
 DACVIM (Cardiology)

**IMAGING PERFORMED BY**

Rebecca Hamilton

**HOSPITAL NAME**

Englewood VC

**REFERRING VET**

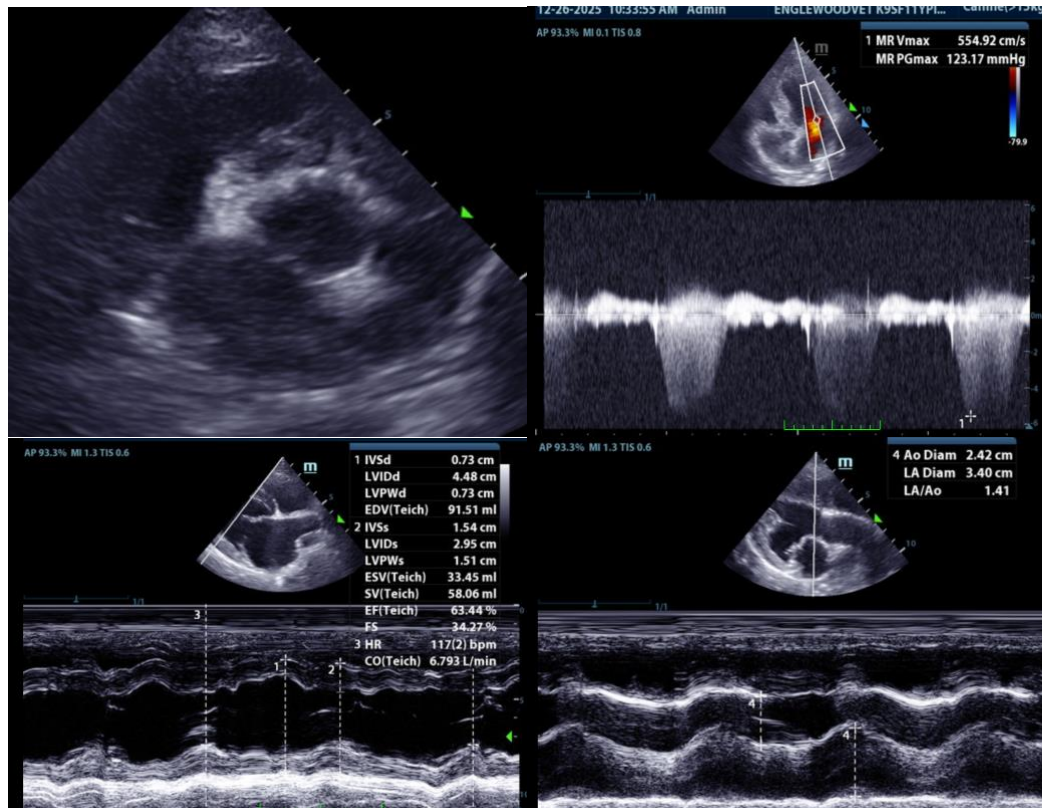
Dr. Ezik

**INVOICE**

35096

**DATE**

12/26/25



**The information and recommendations provided are based on the images presented by the referring veterinarian/sonographer. No evaluation can be communicated regarding pathology that was not visible in the image/video clips provided.**

Thank you for this referral. If the clinical or image interpretation does not parallel your findings or if I can be of any further assistance please contact me.

Camden Rouben DVM, DACVIM (Cardiology)



**PATIENT**

[info@SonoPath.com](mailto:info@SonoPath.com)

Nessi Becerra

**SPECIES**

Canine

**BREED**

Pitbull Mix

**SEX**

Spayed Female

**AGE**

11 Years 2 Months

**WEIGHT**

74.6 Pounds

**INTERPRETED BY**

Camden Rouben DVM,  
DACVIM (Cardiology)

**IMAGING  
PERFORMED BY**

Rebecca Hamilton

**HOSPITAL NAME**

Englewood VC

**REFERRING VET**

Dr. Ezik

**INVOICE**

35096

**DATE**

12/26/25