



PATIENT

Monty Boylan

SPECIES

Feline

BREED

DSH

SEX

Neutered Male

AGE

1.5 Years

WEIGHT

7.1

INTERPRETED BY

Camden Rouben, DVM,
DACVIM (Cardiology)

IMAGING PERFORMED BY

Sarah Burns, DVM

HOSPITAL NAME

Wilvet Salem

REFERRING VET

Sarah Burns, DVM

INVOICE

35610

DATE

1/29/26

PRESENTING CLINICAL SIGNS

Decreased eating and drinking noticed yesterday. P was seen at rDVM today around 4:30pm, noticed pale gums and told to head to ER.

Abnormal PE/Chem/CBC/UA Results: Cardiovascular- normal rate and rhythm. No Murmur but muffled heart sounds. Respiratory/Thorax- Dyspneic with marked abdominal effort, muffled lung sounds but subjectively normal bronchovesicular noises. No coughing/sneezing. CBC: HCT 66.5 (H), Retic 76.8 (H), WBC 13.52 (N), Neut 10.01 (N), Lymph 2.81 (N), Mono 0.57 (N), Plt 100 (L)- clumping noted on direct smear Chem: Gluc 162 (H), remainder WNL EPOC: pH 7.213 (L), Lactate 5.09 (H), Gluc 150 (H), HCT 58 (H) Feline ProBNP (pleural fluid): > 1500 pmol/L (H, consistent with CHF) AFAST: no ff in the abdomen, subjectively normal abdomen TFAST: moderate pleural fluid in the right hemithorax, scant pleural fluid in the left hemithorax.

ULTRASONOGRAPHIC EXAMINATION OF THE HEART

FELINE CARDIAC PARAMETERS	BODY WEIGHT (kg)	HR (BPM)	IVSd (mm)	LVIDd (cm)	LVWd (mm)	FS (%)	EF (%)
NORMAL PARAMETER	-----	150-240		1.0-2.1		35-67	80-100
PATIENT	3.2	NM	9.3 mm	--	9.0 mm	28.2	--
FELINE CARDIAC PARAMETERS	LA/AO (M-mode)	LA/AO HEART BASE (Sisson)	LAD LA MAX 4 Chamber	LVOT VEL. (m/s)	RVOT VEL. (m/s)	IVRT (m/)	
NORMAL PARAMETER	<1.5	1.6		<1.6	<1.3	40-60	
PATIENT	--	1.56	15 mm	--	0.8	NM	
Adapted from June Boon, Veterinary Echocardiography, 1998 Sisson D et al. JVIM 1991; 5: 232, Jacobs et al. Am J Vet Res 1985; 46:1705							

Cardiac Presentation

The left atrial size is within normal limits based on two separate evaluations. The mitral valve leaflets are normal. There is no evidence of mitral regurgitation. There is no evidence of systolic anterior motion of the mitral valve, and no evidence of left ventricular outflow tract obstruction. There is concentric hypertrophy of the left ventricle. The right atrial size appears normal. There is no evidence of tricuspid valve regurgitation. The right ventricle appears to have preserved systolic function, subjectively. The pulmonic outflow velocities appear within normal limits. There is scant pleural effusion in the image. There is no evidence of abdominal effusion, pericardial effusion, or B-lines. There are no intracardiac masses.



PATIENT

Monty Boylan

SPECIES

Feline

BREED

DSH

SEX

Neutered Male

AGE

1.5 Years

WEIGHT

7.1

INTERPRETED BY

Camden Rouben, DVM,
DACVIM (Cardiology)

IMAGING PERFORMED BY

Sarah Burns, DVM

HOSPITAL NAME

Wilvet Salem

REFERRING VET

Sarah Burns, DVM

INVOICE

35610

DATE

1/29/26

ULTRASONOGRAPHIC FINDINGS

- The patient has evidence of a left ventricular concentric hypertrophy, classified as hypertrophic cardiomyopathy phenotype, suspected stage B-1 due to the normal left atrial size.

INTERPRETATION OF THE FINDINGS & FURTHER RECOMMENDATIONS

It is unclear whether this patient has received a thoracocentesis or any sort of diuretic therapy, which could alter the diagnosis and the sizes of the patient's heart.

It is strongly recommended that this patient's blood pressure be assessed, to make sure that it is normal. I would strongly recommend getting a peripheral NT proBNP, to make sure that it is also elevated. FIP should be ruled out as a differential.

If this patient already had a thoracocentesis and had been given diuretics previously, and it resulted in improvement of the patient's clinical signs, then the diuretic therapy should be continued.

This patient should be referred to a veterinary cardiologist for a more thorough echocardiogram to rule out congenital heart defects, given the patient's age.

The patient should be monitored for worsening clinical signs, such as increased resting respiratory rates and effort. If not already doing so, the owners should be monitoring the patient's respiratory rate, and if it is >40 br/p/m, then thoracic radiographs should be performed. In general, this patient should have 3 view thoracic radiographs performed.

If no therapy or interventions have been performed in this patient, it is reasonable that this patient do a week-long trial of furosemide therapy and then be rechecked by the primary veterinarian or veterinary cardiologist in one week's time. Diuretic therapy would involve furosemide at a dose of 1-2 mg/kg, by mouth, twice per day. Success of the therapy would be resolution of the overall clinical signs. At the recheck, a renal panel, evaluating the blood, and an echocardiogram should be performed.



PATIENT

Monty Boylan

SPECIES

Feline

BREED

DSH

SEX

Neutered Male

AGE

1.5 Years

WEIGHT

7.1

INTERPRETED BY

Camden Rouben, DVM,
DACVIM (Cardiology)

IMAGING PERFORMED BY

Sarah Burns, DVM

HOSPITAL NAME

Wilvet Salem

REFERRING VET

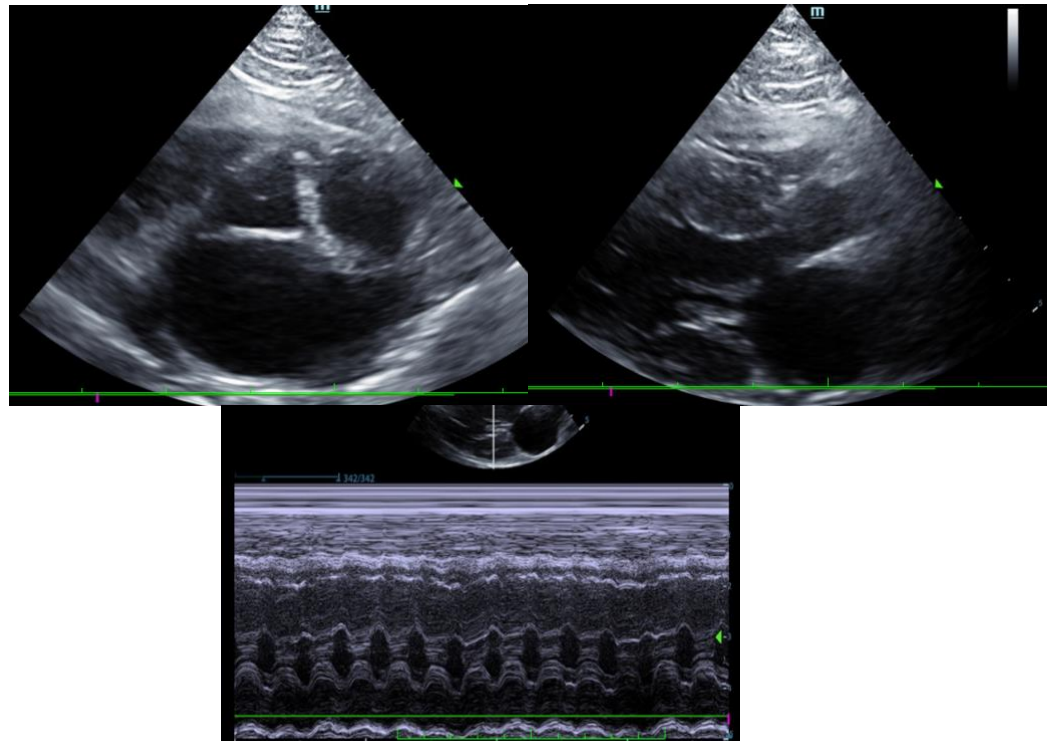
Sarah Burns, DVM

INVOICE

35610

DATE

1/29/26



The information and recommendations provided are based on the images presented by the referring veterinarian/sonographer. No evaluation can be communicated regarding pathology that was not visible in the image/video clips provided.

Thank you for this referral. If the clinical or image interpretation does not parallel your findings or if I can be of any further assistance please contact me.

Camden Rouben DVM, DACVIM (Cardiology)

info@SonoPath.com