

**PATIENT**

Manny Brandt

**SPECIES**

Feline

**BREED**

DSH

**SEX**

Neutered Male

**AGE**

2017

**WEIGHT**

10

**INTERPRETED BY**

Camden Rouben, DVM,  
 DACVIM (Cardiology)

**IMAGING PERFORMED BY**

Rebekah Jakum, CVT,  
 ARDMS/RVT

**HOSPITAL NAME**

North Saucon AH

**REFERRING VET**

Dr. Betz

**INVOICE**

35616

**DATE**

1/29/26

**PRESENTING CLINICAL SIGNS**

- Heart murmur noted at annual exam, elevated ALT, new behavior - aggression to housemate
- Medication: Prozac

**ULTRASONOGRAPHIC EXAMINATION OF THE HEART**

FELINE CARDIAC PARAMETERS	BODY WEIGHT (kg)	HR (BPM)	IVSd (mm)	LVIDd (cm)	LVWd (mm)	FS (%)	EF (%)
NORMAL PARAMETER	-----	150-240		1.0-2.1		35-67	80-100
PATIENT	4.54	NM	4.4 mm	1.54	5.2 mm	62.9	--
FELINE CARDIAC PARAMETERS	LA/AO (M-mode)	LA/AO HEART BASE (Sisson)	LAD LA MAX 4 Chamber		LVOT VEL. (m/s)	RVOT VEL. (m/s)	IVRT (m/)
NORMAL PARAMETER	<1.5	1.6			<1.6	<1.3	40-60
PATIENT	--	1.21	10.00 mm		1.08	1.2	NM

Adapted from June Boon, Veterinary Echocardiography, 1998  
 Sisson D et al. JVIM 1991; 5: 232, Jacobs et al. Am J Vet Res 1985; 46:1705

LVIDs: 0.57

**Cardiac Presentation**

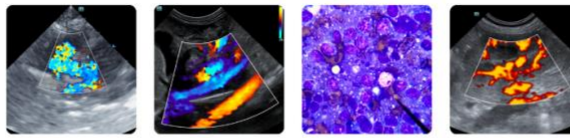
Based on the images provided, the mitral valve leaflets are normal. The left atrial size is normal. There is no evidence of systolic anterior motion of the mitral valve and no evidence of a left ventricular outflow tract obstruction. Left ventricular systolic and diastolic function is within normal limits. There is no evidence of left ventricular concentric hypertrophy. There is normal right atrial size without evidence of tricuspid regurgitation. There is no evidence of pulmonary hypertension on the images provided. The right ventricle appears normal in structure and function. The aortic and pulmonic valves have normal morphology and the corresponding outflow velocities are within normal limits. There is no evidence of pulmonic or aortic insufficiency. The aorta appears normal. The pulmonary artery appears normal. There is no evidence of pleural effusion, pericardial effusion, or intracardiac masses.

**ULTRASONOGRAPHIC FINDINGS**

- The images show a clinically healthy cardiac structure and function.

**INTERPRETATION OF THE FINDINGS & FURTHER RECOMMENDATIONS**

No cardiac medications are warranted at this time. There are no rechecks warranted at this time, unless the heart murmur worsens or the patient develops cardiovascular clinical signs.



**PATIENT**

Manny Brandt

**SPECIES**

Feline

**BREED**

DSH

**SEX**

Neutered Male

**AGE**

2017

**WEIGHT**

10

**INTERPRETED BY**

Camden Rouben, DVM,  
 DACVIM (Cardiology)

**IMAGING PERFORMED BY**

Rebekah Jakum, CVT,  
 ARDMS/RVT

**HOSPITAL NAME**

North Saucon AH

**REFERRING VET**

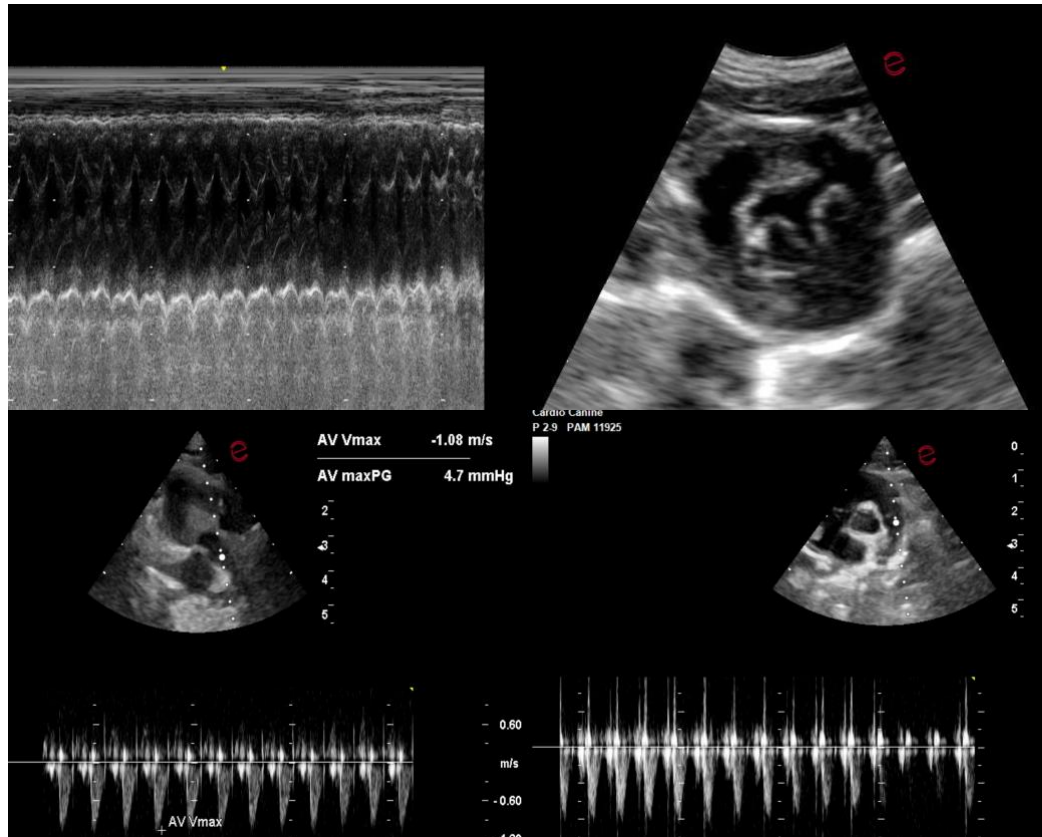
Dr. Betz

**INVOICE**

35616

**DATE**

1/29/26



The information and recommendations provided are based on the images presented by the referring veterinarian/sonographer. No evaluation can be communicated regarding pathology that was not visible in the image/video clips provided.

Thank you for this referral. If the clinical or image interpretation does not parallel your findings or if I can be of any further assistance please contact me.

Camden Rouben DVM, DACVIM (Cardiology)

[info@SonoPath.com](mailto:info@SonoPath.com)