

**DATE PRESENTING CLINICAL SIGNS**

8/28/21

Limping FR leg, swollen, febrile, pancreatitis.

**INTERPRETED BY CYTOLOGY SUBMISSION**

L.D. McGill, DVM,  
Ph.D, DACVP

Pleural effusion (cytospin)

**PATIENT OBSERVATIONS**

Bandit Crum

Pleural effusion: Submitted are 4 excellent videos of excellent collections of cells from the pleural effusion in Bandit. The cellularity consists of large numbers of neutrophils, some of which are degenerate. There are prominent collections of macrophages with foamy vacuolated cytoplasm. Some of these macrophages are phagocytosing degenerate cells. There are rare lymphocytes. Malignant characteristics are not identified.

**SPECIES INTERPRETATION OF THE FINDINGS & FURTHER RECOMMENDATIONS**

Feline

Pleural effusion - Pyogranulomatous inflammation with large numbers of neutrophils.

**BREED COMMENTS**

DSH

The changes support a severe chronic inflammatory process. This could be the result of inflammation secondarily from the pancreas or other locations. This could also be secondary to feline infectious peritonitis. I was unable to identify bacteria and thus sepsis does not appear to be the process. I did not identify any malignant characteristics. This reaction is a severe inflammatory process and treatment for inflammation and possibly infection in other locations may be beneficial. Some of this fluid may be submitted to the lab for feline coronavirus PCR. A guarded prognosis is definitely warranted.

**SEX**

Male Neutered

**AGE**

10 years

**WEIGHT**

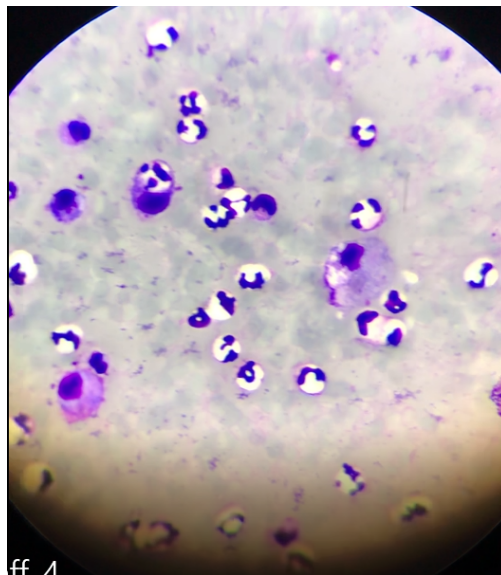
12 lbs

**HOSPITAL NAME**

Rockaway Animal  
Hospital

**REFERRING VET**

Dr. Maniar

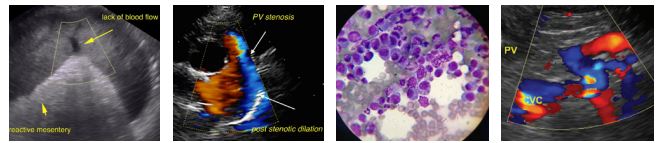


ff 4

Image shows a representative collection of cells from the pleural effusion in Bandit. Note the neutrophils and macrophages with one small macrophage phagocytosing a neutrophil.

**INVOICE NUMBER**

9080



DATE

8/28/21

INTERPRETED BY

L.D. McGill, DVM,  
Ph.D, DACVP

**The information and recommendations provided are based on the images presented by the referring veterinarian. No evaluation can be communicated regarding pathology that was not visible in the image/video clips provided.**

PATIENT

Bandit Crum

Thank you for this referral. If the clinical or image interpretation does not parallel your findings or if I can be of any further assistance please contact me.

SPECIES

Feline

**L.D. McGill, DVM, Ph.D., DACVP**

8288 Top of the World Drive  
Cottonwood Heights, UT 84121

ldmcgill.vetpath@gmail.com

BREED

cell: 801-865-1220

DSH

SEX

Male Neutered

AGE

10 years

WEIGHT

12 lbs

HOSPITAL NAME

Rockaway Animal  
Hospital

REFERRING VET

Dr. Maniar

INVOICE NUMBER

9080