



**PATIENT**

Salem Luterzo

**SPECIES**

Feline

**BREED**

Domestic Shorthair

**SEX**

Neutered male

**AGE**

12 years

**WEIGHT**

11.3 lbs

**INTERPRETED BY**

Dr Brittany Sinclair,  
BVSc(hons), DACVECC

**IMAGING PERFORMED BY**

Kelly Vazquez, CVT

**HOSPITAL NAME**

Ringwood AH

**REFERRING VET**

Dr. Wilkes

**INVOICE**

42788

**DATE**

2/14/23

**PRESENTING CLINICAL SIGNS**

History: Decreased appetite, lethargy, vomiting, and anemia on blood work. Possible abdominal mass seen on radiographs. Current meds: Liquitinic iron supplement, mirtazapine, Convenia injection.  
Abnormal PE/Chem/CBC/UA Results: Globulins 8.5, TP 11, K 3.4. HCT 12.6%, RBC 3.08, HGB 3.2, PLTs 146, EOS 0.15. U/A: pH 6.5, 2+ protein, 30-50 RBCs, USG 1.025.

**ULTRASONOGRAPHIC EXAMINATION OF THE ABDOMEN**

**Urinary System**

The urinary bladder, trigone, and visible pelvic urethra were of normal thickness. The ureters were not visible which is normal. There was normal wall layering with no masses, uroliths or abnormal thickening visualized. Urine was anechoic. No evidence of inflammatory or neoplastic changes were noted.

The kidneys were both normal size and structure, with smooth capsule and normal corticomedullary definition and ratio (cortex 1/3 of medulla). Medullary structure differed distinctly from that of the cortex. No evidence of pelvic dilation was present. The right kidney measured 3.97 cm. The left kidney measured 3.74 cm.

**Adrenal Glands**

Both adrenal glands were visualized and recognized as having normal shape, size, position and echogenicity for this breed. The phrenic vasculature, glandular echogenicity and detail were unremarkable. Capsule, cortex, and medullary definition were normal for this age patient. The left adrenal gland measured 0.89 cm in length and 0.37 cm at the cranial pole and 0.37 cm at the caudal pole. The right adrenal gland measured 0.83 cm in length and 0.4 cm at the cranial pole and 0.4 cm at the caudal pole.

**Spleen**

The spleen was mildly enlarged with a smooth homogeneous parenchyma hyperechoic to liver and renal cortical parenchyma and smooth capsule, with normal splenic vasculature with no signs of congestion or thrombosis. No sonographic evidence of acute or chronic inflammatory, neoplastic, or infarct changes were noted.

**Liver**

The liver is subjectively normal in size with normal contours and structure. The parenchyma is slightly heterogenous with a coarse appearance with a solitary hypoechoic nodule visualized. Vascular and biliary tracts are of normal volume with no evidence of congestion. No pathological hepatic lymphadenopathy observed. Gallbladder is moderately distended with normal wall thickness and anechoic contents. Common bile duct is non-distended and tapers normally

**Gastrointestinal**

The stomach contains minimal luminal contents. It measures at a normal thickness of with some variability due to the presence of rugal folds. The distinction of the gastric wall layers is adequate and



**PATIENT**

Salem Luterzo

**SPECIES**

Feline

**BREED**

Domestic Shorthair

**SEX**

Neutered male

**AGE**

12 years

**WEIGHT**

11.3 lbs

**INTERPRETED BY**

Dr Brittany Sinclair,  
BVSc(hons), DACVECC

**IMAGING PERFORMED BY**

Kelly Vazquez, CVT

**HOSPITAL NAME**

Ringwood AH

**REFERRING VET**

Dr. Wilkes

**INVOICE**

42788

**DATE**

2/14/23

there is no impression of reduced peristaltic activity. No masses or focal lesions were observed. The visualized areas of duodenum, jejunum and ileum have a relatively uniform diameter with minimal fluid distension. Wall thickness is normal. Bowel loops follow a curvilinear path with distinct wall layering maintaining the typical 1:3 muscularis:mucosa layer ratio. Visualized peristalsis appears appropriate. There were no focal lesions consistent with obstruction or a mass effect observed. The ileocecal junction was visualized and exhibited normal intact wall layering and is subjectively of normal thickness. Sections of colon are visualized with formed fecal material and gas shadowing distally. There is no observed focal or generalized colon wall thickening or loss of layering.

***Pancreas***

The base and limbs of the pancreas were observed to be largely isoechoic to surrounding omental fat. Pancreatic duct and capsular contour and parenchyma were normal. No overt evidence of active inflammatory or neoplastic disease was noted.

***Lymph Nodes***

No clinically significant lymphadenopathy or abnormalities noted.

***Free Abdomen***

Focal area of mixed echogenic mottled tissue in caudal cranial to urinary bladder abutting tail of spleen most consistent with inflamed adipose tissue.

**ULTRASONOGRAPHIC FINDINGS**

**Primary Findings**

1. Caudal abdominal steatitis
2. Mild splenomegaly
3. Coarse liver parenchyma with nodule

**INTERPRETATION OF THE FINDINGS & FURTHER RECOMMENDATIONS**

This patient's anemia is severe and warrants further investigation including pathology review, reticulocyte count, infectious disease anemia panel, thoracic radiographs to rule out thoracic neoplasia. Ultimately bone marrow aspirate may be required for attempted definitive diagnosis. Blood transfusion is indicated with a hemoglobin less than 5.0g/dL.

Appearance of caudal abdominal fat is most consistent with focal steatitis. FNA of the tissue is recommended for further characterization and investigate for neoplastic or infectious organisms. Focal abscess, granuloma, soft tissue sarcoma, lymphoma, among other things remain possibilities. Steatitis is more commonly associated with underlying neoplasia in older cats, but may be a sterile or septic inflammatory process. Biopsy is often required for definitive diagnosis and may be both diagnostic and curative if excision is performed. Dietary steatitis is uncommon in cats fed a commercial diet but can result from vitamin E deficiency so supplementation is recommended, along with supportive care to include analgesia and GI support as needed. Immunomodulation including glucocorticoids or cyclosporin is sometimes required, but infectious and neoplastic causes should be ruled out first.



**PATIENT**

Salem Luterzo

Splenomegaly with normal parenchyma is likely secondary to severe anemia and reflects extramedullary hematopoiesis. Splenic aspirate is recommended to further characterize as round cell infiltration, while not suspected, remains a possible cause of both splenomegaly and anemia.

**SPECIES**

Feline

Liver changes are a common benign age related change, but infiltrative disease (lymphoma, MCT, other) cannot be definitively ruled out. No significant disruption of architecture noted to suggest significant pathology. Nodule may represent reactive, regenerative or inflammatory nodule, or less likely early neoplastic change. Fine needle aspirate could be considered to further characterize parenchymal changes if clinically indicated, especially if any weight loss is noted or for baseline cytological assessment.

**BREED**

Domestic Shorthair

**SEX**

Neutered male

**AGE**

12 years

**WEIGHT**

11.3 lbs

**INTERPRETED BY**

Dr Brittany Sinclair, BVSc(hons), DACVECC

**IMAGING PERFORMED BY**

Kelly Vazquez, CVT

**HOSPITAL NAME**

Ringwood AH

**REFERRING VET**

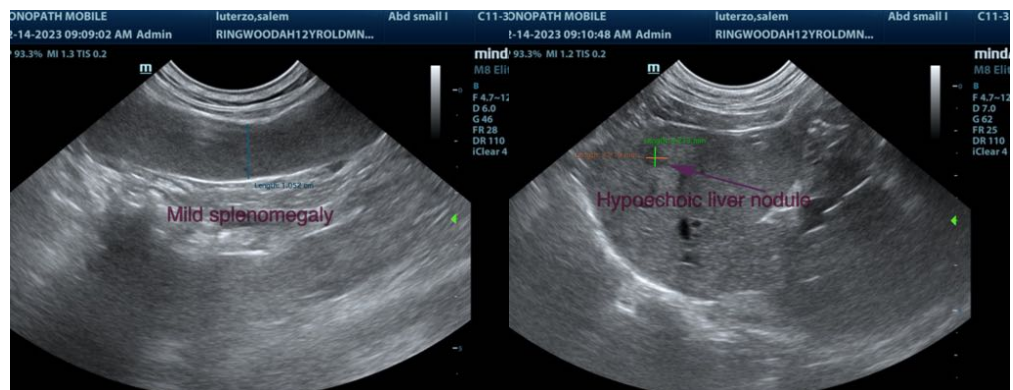
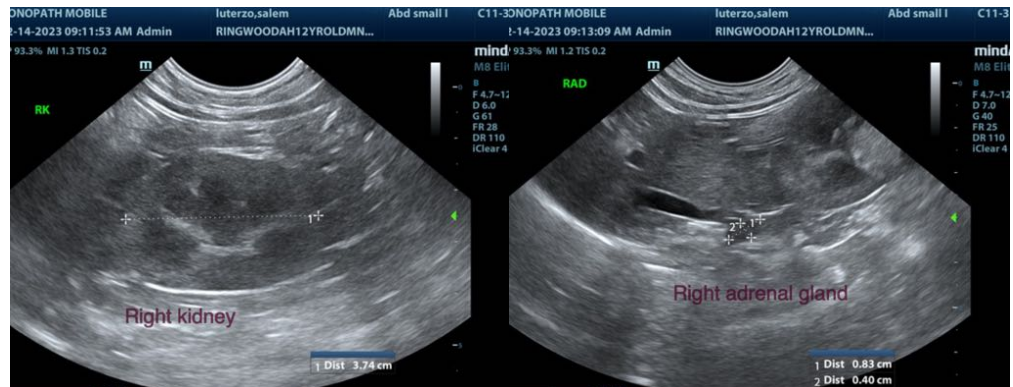
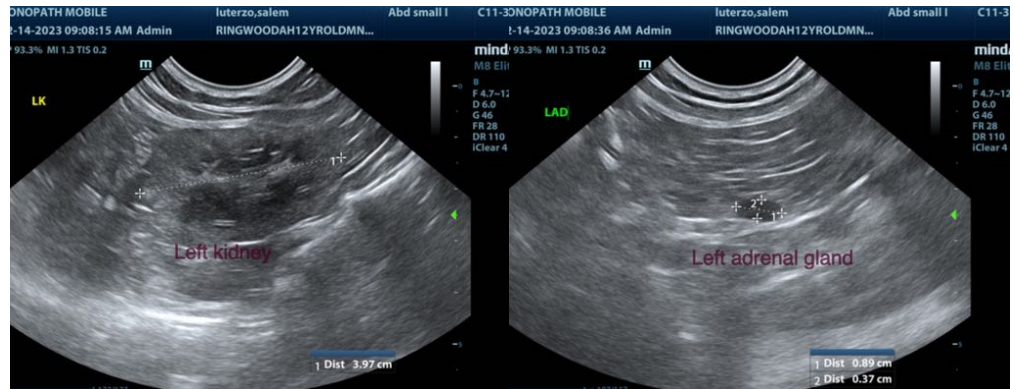
Dr. Wilkes

**INVOICE**

42788

**DATE**

2/14/23





**PATIENT**

Salem Luterzo

**SPECIES**

Feline

**BREED**

Domestic Shorthair

**SEX**

Neutered male

**AGE**

12 years

**WEIGHT**

11.3 lbs

**INTERPRETED BY**

Dr Brittany Sinclair,  
BVSc(hons), DACVECC

**IMAGING  
PERFORMED BY**

Kelly Vazquez, CVT

**HOSPITAL NAME**

Ringwood AH

**REFERRING VET**

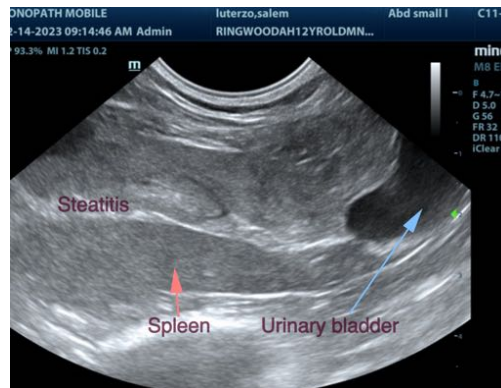
Dr. Wilkes

**INVOICE**

42788

**DATE**

2/14/23



The information and recommendations provided are based on the images presented by the referring veterinarian/sonographer. No evaluation can be communicated regarding pathology that was not visible in the image/video clips provided.

Thank you for this referral. If the clinical or image interpretation does not parallel your findings or if I can be of any further assistance please contact me.

Dr Brittany Sinclair, BVSc(hons), DACVECC  
info@SonoPath.com