

**PATIENT**

Maggie Diverty

**SPECIES**

Canine

**BREED**

Irish Wolfhound

**SEX**

Intact female

**AGE**

1 year

**WEIGHT**

44 kg

**INTERPRETED BY**

Dr Brittany Sinclair,  
BVSc(hons), DACVECC

**IMAGING  
PERFORMED BY**

Kelly Reshny, RVT

**HOSPITAL NAME**

East Plains AH

**REFERRING VET**

Dr. Cumming

**INVOICE**

43106

**DATE**

3/6/23

**PRESENTING CLINICAL SIGNS**

History: History of decreased appetite for the last 3-4 weeks. Is still eating, but far less than her normal amount (usually eating 6 cups per day, now is eating 1-2 at most). Has lost 2kg since the last time we have seen her (1 month). Vomiting intermittently the last few weeks as well despite no history of diet change, dietary indiscretion or foreign material ingestion. Just had first heat cycle and symptoms started shortly after. Quieter than normal, seems listless. No changes in bathroom habits - urinating with normal frequency, solid stools. No discharge from back end noted since cycle ended. Is not licking hind end excessively, swollen vulva has resolved. \*\*No fever on exam, comfortable for abdominal palpation - could not feel palpable enlarged uterus.. Current Medications Cerenia SID, famotidine BID  
Abnormal PE/Chem/CBC/UA Results: Bloodwork from March 1 wnl including cpli and 4dx

**ULTRASONOGRAPHIC EXAMINATION OF THE ABDOMEN**

**Urinary System**

The urinary bladder, trigone, and visible pelvic urethra were of normal thickness. The ureters were not visible which is normal. There was normal wall layering with no masses, uroliths or abnormal thickening visualized. Urine was anechoic. No evidence of inflammatory or neoplastic changes were noted.

The kidneys were both normal size and structure, with smooth capsule and normal corticomedullary definition and ratio (cortex 1/3 of medulla). Medullary structure differed distinctly from that of the cortex. No evidence of pelvic dilation was present. The right kidney measured 8.54 cm. The left kidney measured 8.3 cm.

**Adrenal Glands**

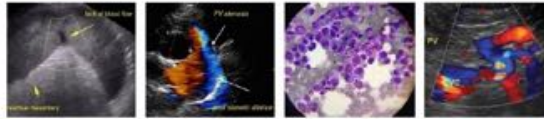
Both adrenal glands were visualized and recognized as having normal shape, position and echogenicity for this breed. Both adrenal glands measured relatively small for this breed and size of dog. The visualized phrenic vasculature, glandular echogenicity and detail were unremarkable. Capsule, cortex, and medullary definition were normal for this age patient. The left kidney measured 2.79 cm in length x 0.36 cm at the caudal pole and 0.53 cm at the cranial pole. The right adrenal gland measured 2.3 cm in length x 0.34 cm at the caudal pole and 0.87 cm at the cranial pole.

**Spleen**

The spleen was normal with a smooth homogeneous parenchyma hyperechoic to liver and renal cortical parenchyma and smooth capsule, with normal splenic vasculature with no signs of congestion or thrombosis. No sonographic evidence of acute or chronic inflammatory, neoplastic, or infarct changes were noted.

**Liver**

The liver is subjectively normal in size with normal contours and structure. There is appropriate echogenicity and echotexture. No overt structural evidence of inflammatory, infiltrative or regenerative pathology is evident. Vascular and biliary tracts are of normal volume with no evidence of congestion. No pathological hepatic lymphadenopathy observed. Gallbladder is moderately distended with normal wall thickness and anechoic contents. Common bile duct is non-distended and tapers normally


**PATIENT**

Maggie Diverty

**SPECIES**

Canine

**BREED**

Irish Wolfhound

**SEX**

Intact female

**AGE**

1 year

**WEIGHT**

44 kg

**INTERPRETED BY**

 Dr Brittany Sinclair,  
 BVSc(hons), DACVECC

**IMAGING  
 PERFORMED BY**

Kelly Reshny, RVT

**HOSPITAL NAME**

East Plains AH

**REFERRING VET**

Dr. Cumming

**INVOICE**

43106

**DATE**

3/6/23

***Gastrointestinal***

The stomach contains minimal luminal contents. It measures at a normal thickness of with some variability due to the presence of rugal folds. The distinction of the gastric wall layers is adequate and there is no impression of reduced peristaltic activity. No masses or focal lesions were observed. The visualized areas of duodenum, jejunum and ileum have a relatively uniform diameter with minimal fluid distension. Wall thickness is normal. Bowel loops follow a curvilinear path with distinct wall layering maintaining the typical 1:3 muscularis:mucosa layer ratio. Visualized peristalsis appears appropriate. There were no focal lesions consistent with obstruction or a mass effect observed. The ileocecal junction was visualized and exhibited normal intact wall layering and is subjectively of normal thickness. Sections of colon are visualized with formed fecal material and gas shadowing distally. There is no observed focal or generalized colon wall thickening or loss of layering.

***Pancreas***

The base and limbs of the pancreas were observed to be largely isoechoic to surrounding omental fat. Pancreatic duct and capsular contour and parenchyma were normal. No overt evidence of active inflammatory or neoplastic disease was noted.

***Lymph Nodes***

No clinically significant lymphadenopathy or abnormalities noted.

***Free Abdomen***

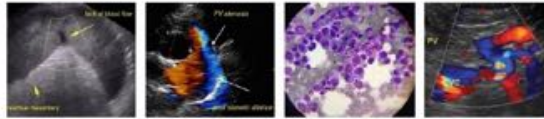
No masses or free fluid were noted.

**ULTRASONOGRAPHIC FINDINGS**
**Primary Findings**

1. Bilaterally small adrenal glands
2. Normal GI tract

**INTERPRETATION OF THE FINDINGS & FURTHER RECOMMENDATIONS**

There is no definitive ultrasonographically evident cause of reported GI signs in this abdominal study. Pancreas and GI tract are within normal limits. Consideration for dietary indiscretion, food sensitivity/allergy or mild inflammatory bowel disease is reasonable. Atypical hypoadrenocorticism should be considered given the small adrenal glands, though adrenal size is variable and does not always correlate with adrenal gland function. While not sonographically evident, pancreatitis cannot be completely ruled out. Empiric treatment for GI signs including anti-nausea, appetite stimulant and fluid support as clinically indicated is warranted. A diet trial with hydrolyzed protein or select protein diet could be considered if food sensitivity is suspected clinically. If signs are persistent or recurrent, additional diagnostics to be considered include GI panel (TLI/PLI/cobalamin/folate), baseline cortisol +/- ACTH stimulation test, fecal pathogen panel, thyroid testing, bile acid profile, and thoracic radiographs to rule out occult neoplasia, cardiac disease and esophageal disease as potential causes. Ultimately GI



**PATIENT**

Maggie Diverty

biopsy may be required for more definitive diagnosis if the patient is not responsive to medical treatment.

**SPECIES**

Canine

**BREED**

Irish Wolfhound

**SEX**

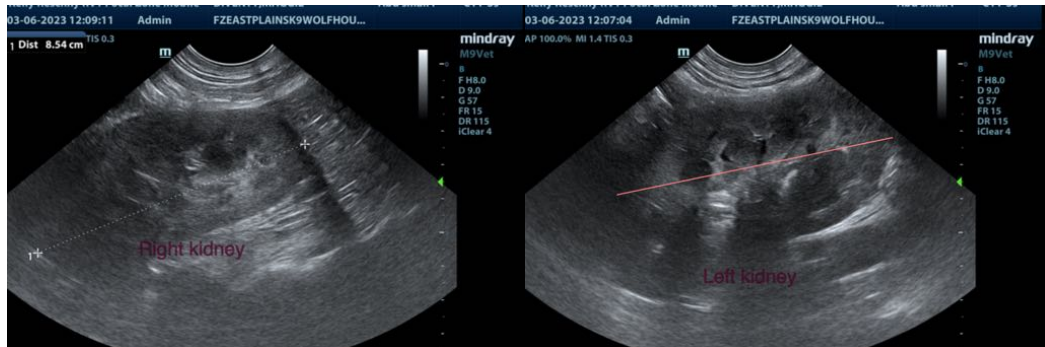
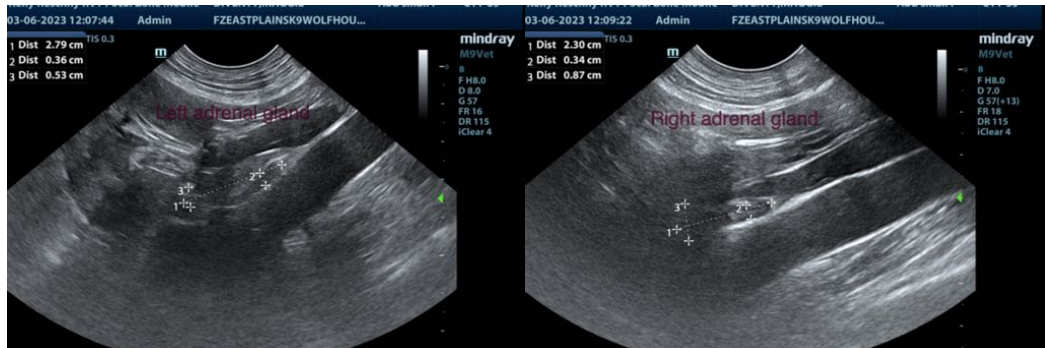
Intact female

**AGE**

1 year

**WEIGHT**

44 kg



**INTERPRETED BY**

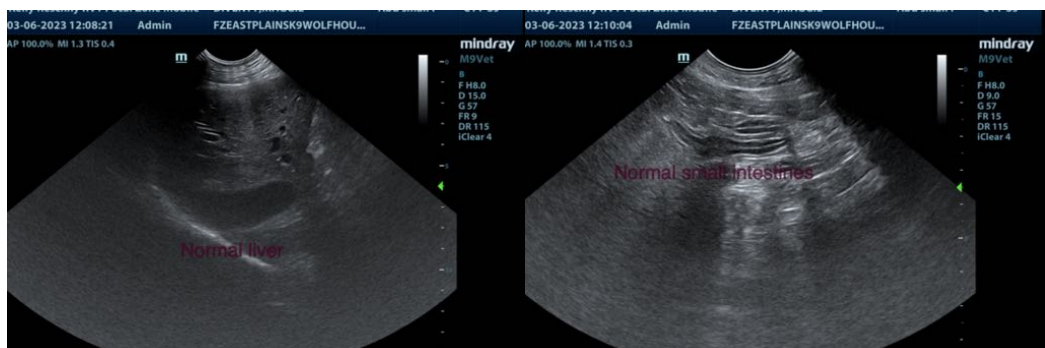
Dr Brittany Sinclair, BVSc(hons), DACVECC

**IMAGING PERFORMED BY**

Kelly Reshny, RVT

**HOSPITAL NAME**

East Plains AH



**REFERRING VET**

Dr. Cumming

The information and recommendations provided are based on the images presented by the referring veterinarian/sonographer. No evaluation can be communicated regarding pathology that was not visible in the image/video clips provided.

Thank you for this referral. If the clinical or image interpretation does not parallel your findings or if I can be of any further assistance please contact me.

**INVOICE**

43106

Dr Brittany Sinclair, BVSc(hons), DACVECC  
info@SonoPath.com

**DATE**

3/6/23