



**PATIENT**

Zara Warren

**PRESENTING CLINICAL SIGNS**

History: chronic hematuria despite medications; intermittent leaking/dripping; during flare-ups licks vulva ; also prone to dermatitis. On deramaxx. Has been on Hills S/O  
Abnormal PE/Chem/CBC/UA Results: latest UA: prot +3, pH 6.5, blood 3+, USPG 1.035, sediment rbc's ntc, few PMNs. Previous UA showed struvites, which has cleared up.

**SPECIES**

Canine

**ULTRASONOGRAPHIC EXAMINATION OF THE ABDOMEN**

**BREED**

Great Dane

**Urinary System**

The urinary bladder, trigone, and visible pelvic urethra were of normal thickness. The ureters were not visible which is normal. There was normal wall layering with no masses, uroliths or abnormal thickening visualized. Mobile debris present in the urinary bladder. Correlate clinical significance with urinalysis findings. No evidence of inflammatory or neoplastic changes were noted.

**SEX**

Spayed female

The kidneys have a smooth capsule and with hazing of corticomedullary definition to the point of inability to determine cortical/medullary ratio. No evidence of pelvic dilation was present. Hyperechoic shadowing was present in the left and right renal pelvises with no dilation consistent with non-obstructive nephrolithiasis. The left kidney measured 8.1 cm and the right kidney measured 8.35 cm.

**AGE**

4 years

**Adrenal Glands**

**WEIGHT**

132 lbs

Both adrenal glands were visualized and recognized as having normal shape, size, position and echogenicity for this breed. The phrenic vasculature, glandular echogenicity and detail were unremarkable. Capsule, cortex, and medullary definition were normal for this age patient. The left adrenal gland measured 2.4 cm in length and 0.59 cm at the cranial pole and 0.52 cm at the caudal pole. The right adrenal gland measured 3.63 cm in length and 1.87 cm at the cranial pole and 0.56 cm at the caudal pole.

**INTERPRETED BY**

Dr Brittany Sinclair,  
BVSc(hons), DACVECC

**IMAGING PERFORMED BY**

Diane McFadden, RVT

**Spleen**

The spleen was normal in size with a slightly mottled parenchyma and smooth capsule. Normal splenic vasculature with no signs of congestion or thrombosis.

**HOSPITAL NAME**

Branchville Country  
Vet

**Liver**

The liver is subjectively normal in size with normal contours and structure. There is appropriate echogenicity and echotexture. No overt structural evidence of inflammatory, infiltrative or regenerative pathology is evident. Vascular and biliary tracts are of normal volume with no evidence of congestion. No pathological hepatic lymphadenopathy observed. Gallbladder is moderately distended with normal wall thickness and anechoic contents. Common bile duct is non-distended and tapers normally

**REFERRING VET**

Dr. Talbot-Valerio

**INVOICE**

43870

**Gastrointestinal**

The stomach contains minimal luminal contents. It measures at a normal thickness of with some variability due to the presence of rugal folds. The distinction of the gastric wall layers is adequate and there is no impression of reduced peristaltic activity. No masses or focal lesions were observed.

**DATE**

4/18/23



**PATIENT**

Zara Warren

The visualized areas of duodenum, jejunum and ileum have a relatively uniform diameter with minimal fluid distension. Wall thickness is normal. Bowel loops follow a curvilinear path with distinct wall layering maintaining the typical 1:3 muscularis:mucosa layer ratio. Visualized peristalsis appears appropriate. There were no focal lesions consistent with obstruction or a mass effect observed.

**SPECIES**

Canine

Sections of colon are visualized with formed fecal material and gas shadowing distally. There is no observed focal or generalized colon wall thickening or loss of layering.

**BREED**

Great Dane

**Pancreas**

The base and limbs of the pancreas were observed to be largely isoechoic to surrounding omental fat. Pancreatic duct and capsular contour and parenchyma were normal. No overt evidence of active inflammatory or neoplastic disease was noted.

**SEX**

Spayed female

**Lymph Nodes**

No clinically significant lymphadenopathy or abnormalities noted.

**AGE**

4 years

**Free Abdomen**

No masses or free fluid were noted.

**WEIGHT**

132 lbs

**ULTRASONOGRAPHIC FINDINGS**

**INTERPRETED BY**

Dr Brittany Sinclair,  
BVSc(hons), DACVECC

**Primary Findings**

1. Non-obstructive nephrolithiasis (bilateral)
2. Mild urinary bladder debris
3. Splenic parenchymal changes with smooth capsule

**IMAGING PERFORMED BY**

Diane McFadden, RVT

**INTERPRETATION OF THE FINDINGS & FURTHER RECOMMENDATIONS**

No cause of recurrent urinary tract infections are apparent in the bladder study. No urinary bladder stones, mural thickening or signs of inflammation or significant debris were present. Renal nephroliths may act as a nidus of infection and predispose to urinary tract infections. They have the potential to move into the ureters or bladder causing obstructive uropathy. Promotion of increased water intake with canned food and access to water fountains and urinary health diets (hills c/d, royal canin urinary S/O, purina proplan UR, etc) may be useful if clinically indicated.

**HOSPITAL NAME**

Branchville Country  
Vet

**REFERRING VET**

Dr. Talbot-Valerio

Urine culture with sensitivity and 2-4 week course of appropriate antibiotic therapy with urinalysis and culture 3 days prior to discontinuation of antibiotics and 3 days after discontinuation is recommended to ensure adequate coverage and length of treatment. Thorough physical exam and historical information gathering to search for presence of predisposing factors for ascending infection such as skin disease, vulvar conformation or husbandry which may be predisposing to ascending infections. Thorough investigation for underlying disease which may be predisposing to lowered immunity including chem/lytes/CBC, thyroid testing and baseline cortisol +/- ACTH stimulation test is recommended. Ultimately cystoscopy may be required for more definitive diagnosis.

**INVOICE**

43870

**DATE**

4/18/23

Splenic changes are a common benign age related change, or may represent reaction to immune stimulation, but infiltrative disease (lymphoma, MCT, other) cannot be definitively ruled out. No significant disruption of architecture noted to suggest significant pathology. Fine needle aspirate could



**PATIENT**

Zara Warren

be considered to further characterize parenchymal changes if clinically indicated, especially if any weight loss is noted or for baseline cytological assessment.

**SPECIES**

Canine

**BREED**

Great Dane

**SEX**

Spayed female

**AGE**

4 years

**WEIGHT**

132 lbs

**INTERPRETED BY**

Dr Brittany Sinclair, BVSc(hons), DACVECC

**IMAGING PERFORMED BY**

Diane McFadden, RVT

**HOSPITAL NAME**

Branchville Country Vet

**REFERRING VET**

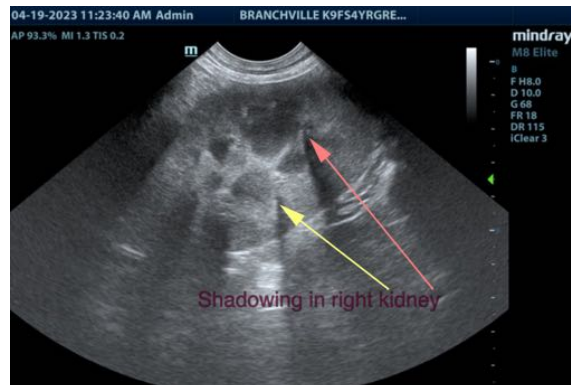
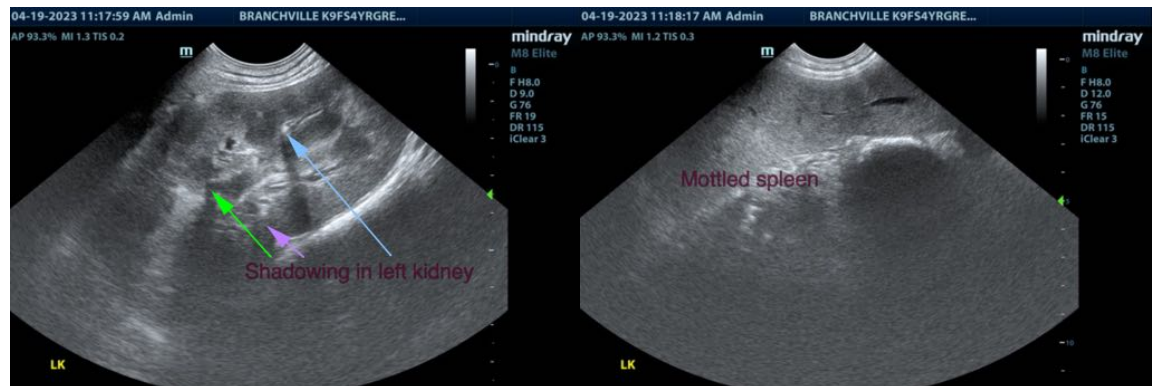
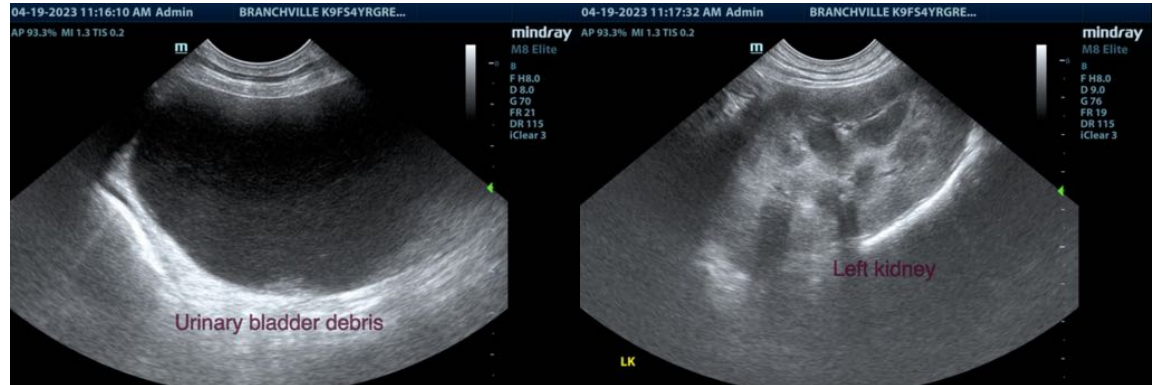Dr. Talbot-Valerio

**INVOICE**

43870

**DATE**

4/18/23



The information and recommendations provided are based on the images presented by the referring veterinarian/sonographer. No evaluation can be communicated regarding pathology that was not visible in the image/video clips provided.

Thank you for this referral. If the clinical or image interpretation does not parallel your findings or if I can be of any further assistance please contact me.

Dr Brittany Sinclair, BVSc(hons), DACVECC  
info@SonoPath.com