



PATIENT

Maddie Johnson

SPECIES

Feline

BREED

Ragdoll

SEX

Spayed female

AGE

9 years

WEIGHT

6 lbs

INTERPRETED BY

Dr Brittany Sinclair,
BVSc(hons), DACVECC

IMAGING PERFORMED BY

Dr. Gordon

HOSPITAL NAME

Coral Ridge AH

REFERRING VET

Dr. Gordon

INVOICE

43758

DATE

4/10/23

PRESENTING CLINICAL SIGNS

History: Weight loss anorexia bloody stool/diarrhea vomiting febrile on initial exam responded to conservative therapy pending labs - administered fluids, pen o g injection , cerenia Oral Flagyl was dispensed also had whipworms 2/22 and was dewormed with panacur
Abnormal PE/Chem/CBC/UA Results: Labs were normal in 7/21 4/5/23 ALT 697 - 27-158 ul AST 214 16-67 ul ALP 281 12-59 UL T Bil 0.4 0.0-0.3 mg dl lipase 61 0-45 ul Fecal negative /fecal Ag negative

ULTRASONOGRAPHIC EXAMINATION OF THE ABDOMEN

Urinary System

The urinary bladder, trigone, and visible pelvic urethra were of normal thickness. The ureters were not visible which is normal. There was normal wall layering with no masses, uroliths or abnormal thickening visualized. Urine was anechoic. No evidence of inflammatory or neoplastic changes were noted.

The kidneys were both normal size and structure, with smooth capsule and normal corticomedullary definition and ratio (cortex 1/3 of medulla). Medullary structure differed distinctly from that of the cortex. No evidence of pelvic dilation was present. The right kidney measured 3.35 cm. The left kidney measured 3.23 cm.

Adrenal Glands

Both adrenal glands were visualized and recognized as having normal shape, size, position and echogenicity for this breed. The phrenic vasculature, glandular echogenicity and detail were unremarkable. Capsule, cortex, and medullary definition were normal for this age patient. The left adrenal gland measured 1.04 cm in length and 0.28 cm at the cranial pole and 0.38 cm at the caudal pole. The right adrenal gland measured 1.06 cm in length and 0.24 cm at the cranial pole and 0.26 cm at the caudal pole.

Spleen

The spleen was normal with a smooth homogeneous parenchyma hyperechoic to liver and renal cortical parenchyma and smooth capsule, with normal splenic vasculature with no signs of congestion or thrombosis. No sonographic evidence of acute or chronic inflammatory, neoplastic, or infarct changes were noted.

Liver

The liver is subjectively normal in size with normal contours and structure. The parenchyma is slightly heterogeneous with a coarse appearance and multifocal hyperechoic nodules visualized. Vascular and biliary tracts are of normal volume with no evidence of congestion. No pathological hepatic lymphadenopathy observed.

The gall bladder is moderately distended with anechoic fluid, with hyperechoic non-shadowing debris present. The proximal common bile duct is moderately distended and tortuous but begins to taper and is non-distended near the duodenal papilla. There is no surrounding free fluid or signs of active inflammation.



PATIENT

Gastrointestinal

Maddie Johnson

A significantly thickened bowel loop is visualized in clips following clips of urinary bladder. In other clips it is at the ileocolic junction. It is uncertain whether this represents a loops of small or large intestine as it is not definitively traced caudally or cranially to fully define. There is not loss but some blurring of wall layering and significant thickening of the intestine itself and the muscularis layer specifically.

SPECIES

Feline

The stomach contains minimal luminal contents. It measures at a normal thickness of with some variability due to the presence of rugal folds. The distinction of the gastric wall layers is adequate and there is no impression of reduced peristaltic activity. No masses or focal lesions were observed.

BREED

Ragdoll

The majority of the areas of duodenum, jejunum and ileum have a relatively uniform diameter with minimal fluid distension. Wall thickness is normal. Bowel loops follow a curvilinear path with distinct wall layering maintaining the typical 1:3 muscularis:mucosa layer ratio. Visualized peristalsis appears appropriate. There were no focal lesions consistent with obstruction or a mass effect observed.

SEX

Spayed female

The ileocecal junction was visualized. A significantly thickened bowel loop is visualized in clips following clips of urinary bladder and in other clips a similar appearing bowel loop is present at the ileocolic junction. It is uncertain whether this represents a loops of small or large intestine as it is not definitively traced caudally or cranially to fully define. There is not loss but some blurring of wall layering and significant thickening of the intestine itself and the muscularis layer specifically.

AGE

9 years

Sections of colon are visualized with formed fecal material and gas shadowing distally. There is no observed focal or generalized colon wall thickening or loss of layering.

WEIGHT

6 lbs

Pancreas

The base and limbs of the pancreas were observed to be largely isoechoic to surrounding omental fat. Pancreatic duct and capsular contour and parenchyma were normal. No overt evidence of active inflammatory or neoplastic disease was noted.

INTERPRETED BY

Dr Brittany Sinclair,
BVSc(hons), DACVECC

Lymph Nodes

Lobulated hypoechoic structure included in two clips at the end of the study is suspected to represent an enlarged mesenteric lymph node which measures 2.8 cmx1.4 cm.

IMAGING PERFORMED BY

Dr. Gordon

HOSPITAL NAME

Coral Ridge AH

Free Abdomen

No masses or free fluid were noted.

REFERRING VET

Dr. Gordon

ULTRASONOGRAPHIC FINDINGS

Primary Findings

INVOICE

43758

1. Thickened bowel loop at ICJ
2. Mesenteric lymphadenopathy
3. Coarse liver parenchyma with nodules
4. Gall bladder debris, tortuous bile duct

DATE

4/10/23



PATIENT

Maddie Johnson

SPECIES

Feline

BREED

Ragdoll

SEX

Spayed female

AGE

9 years

WEIGHT

6 lbs

INTERPRETED BY

Dr Brittany Sinclair,
BVSc(hons), DACVECC

IMAGING PERFORMED BY

Dr. Gordon

HOSPITAL NAME

Coral Ridge AH

REFERRING VET

Dr. Gordon

INVOICE

43758

DATE

4/10/23

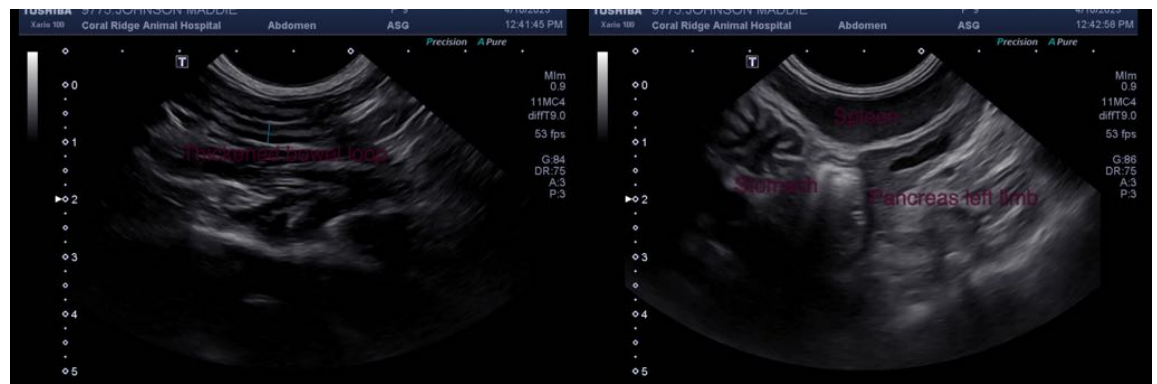
INTERPRETATION OF THE FINDINGS & FURTHER RECOMMENDATIONS

The focal significant thickening of the ICJ and muscularis layer is most consistent with infiltrative disease with inflammatory bowel disease or GI lymphoma being the top differentials. Resolving colitis/enteritis is possible, but less likely. No overt neoplastic criteria present in the bowel given that curvilinear layering is still intact which would suggest inflammatory bowel as opposed to round cell neoplasia (LSA, MCT and similar). Intraoperative US-guided bx would be optimal in this patient to obtain the most representative samples in the GI tract. I cannot rule out a preneoplastic (LSA) state however and follow-up sonograms recommended especially if the patient is not responding to empirical efforts. Endoscopic biopsy is less invasive but may miss lesions due to inability to sample more than top 1-2 layers of GI tract and inability to obtain samples from all sections of the GI tract. Surgical biopsies are more likely to be diagnostic but are more invasive. A GI panel (PLI/cobalamin/folate) will help determine the severity of SI dysfunction, and need for vitamin supplementation.

Lymphadenopathy with maintenance of normal structure is most suggestive of infectious lymphadenitis (bacterial, viral, protozoal or less likely fungal infection), reactive lymphadenitis (parasitism, migrating foreign body), or less likely infiltrative disease (lymphoma, MCT, other) among other things. Lymph node aspirate and culture is recommended to further define this change. Serial imaging for monitoring for progression or resolution of lymphadenopathy is recommended.

Liver changes are a common benign age related change, but infiltrative disease (lymphoma, MCT, other) cannot be definitively ruled out. Nodules may represent reactive, regenerative or inflammatory nodules, or early neoplastic change. In the face of elevated liver enzymes, fine needle aspirate is recommended to further characterize parenchymal changes, and bile acid profile to assess liver function, especially if any weight loss is noted or for baseline cytological assessment. Ultimately liver biopsy is often required for more definitive diagnosis.

Gall bladder debris and tortuous bile duct is a common change associated with chronic episodes of cholangitis. In the absence of significant hyperbilirubinemia and with distal tapering of the bile duct, post-hepatic obstruction is not suspected. These changes may be an incidental finding given lack of surrounding inflammation. In the face of elevated liver values ursodiol could be given as a choleric and empiric treatments (SAM-E, milk thistle, Vitamin E) could be tried. If liver supportive medications do not improve liver enzymes, a course of empiric antibiotics (clavamox, enrofloxacin) could be considered to cover for infectious cholangiohepatitis, though the lack of surrounding inflammation makes this less likely. Imaging should be rechecked on a routine basis for monitoring (q3-6mo) or if further significant increase in liver enzymes and/or new clinical signs are noted. If otherwise clinically indicated, investigation for endocrinopathy such as hyperadrenocorticism or hypothyroidism could be considered as an underlying cause predisposing to gall bladder debris accumulation.





PATIENT

Maddie Johnson

SPECIES

Feline

BREED

Ragdoll

SEX

Spayed female

AGE

9 years

WEIGHT

6 lbs

INTERPRETED BY

Dr Brittany Sinclair, BVSc(hons), DACVECC

IMAGING PERFORMED BY

Dr. Gordon

HOSPITAL NAME

Coral Ridge AH

REFERRING VET

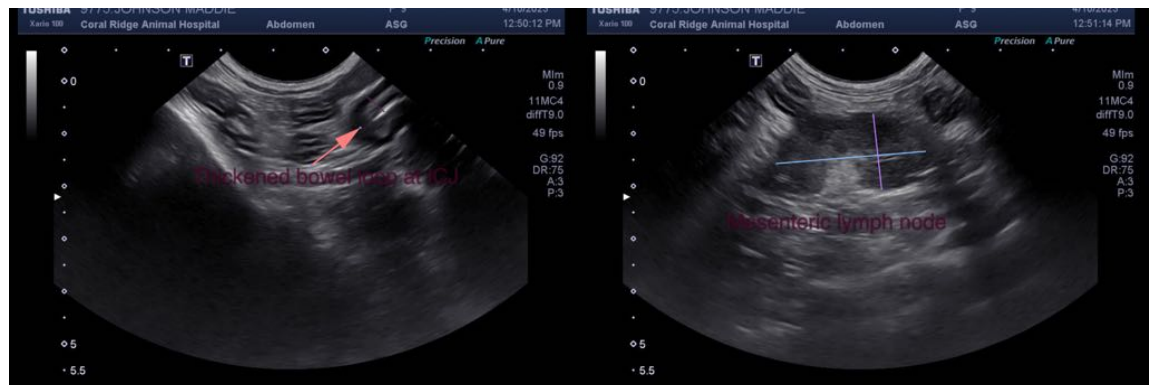
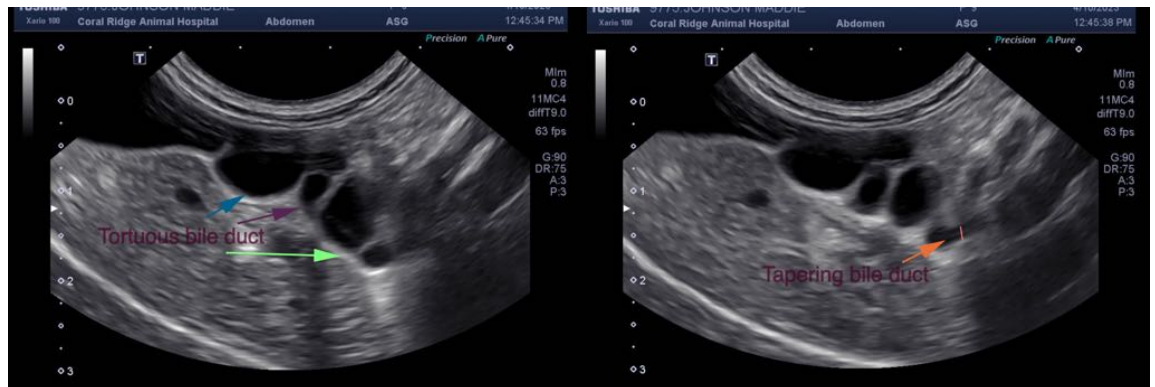
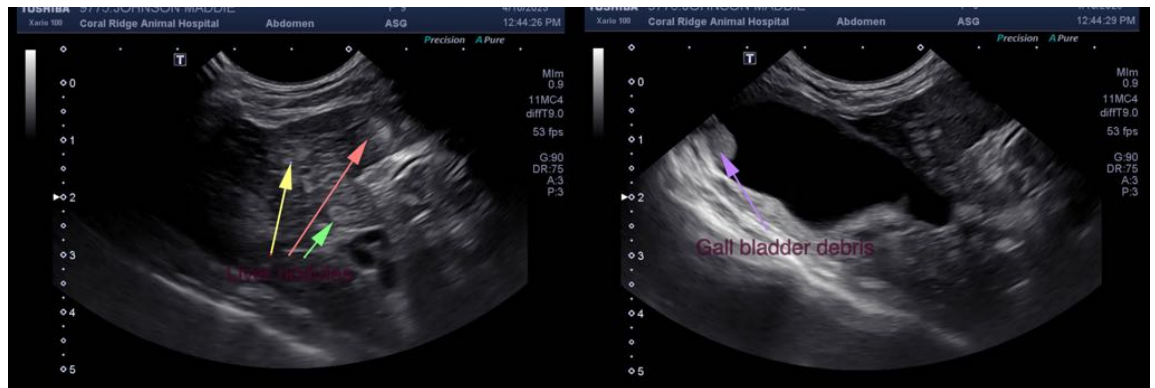
Dr. Gordon

INVOICE

43758

DATE

4/10/23



The information and recommendations provided are based on the images presented by the referring veterinarian/sonographer. No evaluation can be communicated regarding pathology that was not visible in the image/video clips provided.

Thank you for this referral. If the clinical or image interpretation does not parallel your findings or if I can be of any further assistance please contact me.

Dr Brittany Sinclair, BVSc(hons), DACVECC
info@SonoPath.com