



PATIENT

Emma Cosby

SPECIES

Canine

BREED

Corgi

SEX

Spayed female

AGE

12 years

WEIGHT

41.8 lbs

INTERPRETED BY

Dr Brittany Sinclair,
BVSc(hons), DACVECC

IMAGING PERFORMED BY

Dr. Arms

HOSPITAL NAME

Gilbetsville VH

REFERRING VET

Dr. Arms

INVOICE

43146

DATE

3/7/23

PRESENTING CLINICAL SIGNS

History: Presented for senior wellness, 2-3 inch right anal gland mass noted on exam. Labwork showed increased total calcium (12.8), mild increased AST (90), usg 1.008. CXR today showed age related changes, rad review pending.

ULTRASONOGRAPHIC EXAMINATION OF THE ABDOMEN

Urinary System

The urinary bladder, trigone, and visible pelvic urethra were of normal thickness. The ureters were not visible which is normal. There was normal wall layering with no masses, uroliths or abnormal thickening visualized. Urine was anechoic. No evidence of inflammatory or neoplastic changes were noted.

The kidneys have a smooth capsule and with hazing of corticomedullary definition to the point of inability to determine cortical/medullary ratio and pinpoint areas of cortical mineralization. No evidence of pelvic dilation was present. The left kidney measured 5.5 cm and the right kidney measured 5.9 cm.

Adrenal Glands

Both adrenal glands were visualized and recognized as having normal shape, size, position and echogenicity for this breed. The phrenic vasculature, glandular echogenicity and detail were unremarkable. Capsule, cortex, and medullary definition were normal for this age patient. The left adrenal gland measured 2.5 cm in length and 0.6 cm at the cranial pole and 0.72 cm at the caudal pole. The right adrenal gland measured 2.2 cm in length x 0.76 cm at the cranial pole and 0.45 cm at the caudal pole.

Spleen

The spleen has a generally smooth homogeneous parenchyma hyperechoic to liver and renal cortical parenchyma and smooth capsule, with normal splenic vasculature with no signs of congestion or thrombosis. Multifocal variably sized hyperechoic nodules are present throughout and are most consistent with benign myelolipomas. No sonographic evidence of acute or chronic inflammatory, neoplastic, or infarct changes were noted.

Liver

The liver is subjectively normal in size with normal contours and structure. There is appropriate echogenicity and echotexture. No overt structural evidence of inflammatory, infiltrative or regenerative pathology is evident. Vascular and biliary tracts are of normal volume with no evidence of congestion. No pathological hepatic lymphadenopathy observed. Gallbladder is moderately distended with normal wall thickness and anechoic contents. Common bile duct is non-distended and tapers normally



PATIENT

Gastrointestinal

Emma Cosby

The stomach contains minimal luminal contents. It measures at a normal thickness of with some variability due to the presence of rugal folds. The distinction of the gastric wall layers is adequate and there is no impression of reduced peristaltic activity. No masses or focal lesions were observed. The visualized areas of duodenum, jejunum and ileum have a relatively uniform diameter with minimal fluid distension. Wall thickness is normal. Bowel loops follow a curvilinear path with distinct wall layering maintaining the typical 1:3 muscularis:mucosa layer ratio. Visualized peristalsis appears appropriate. There were no focal lesions consistent with obstruction or a mass effect observed. The ileocecal junction was visualized and exhibited normal intact wall layering and is subjectively of normal thickness. Sections of colon are visualized with formed fecal material and gas shadowing distally. There is no observed focal or generalized colon wall thickening or loss of layering.

SPECIES

Canine

BREED

Corgi

SEX

Spayed female

Pancreas

The base and limbs of the pancreas were observed to be largely isoechoic to surrounding omental fat. Pancreatic duct and capsular contour and parenchyma were normal. No overt evidence of active inflammatory or neoplastic disease was noted.

AGE

12 years

Lymph Nodes

WEIGHT

41.8 lbs

No clinically significant lymphadenopathy or abnormalities noted.

INTERPRETED BY

Free Abdomen

No masses or free fluid were noted.

Dr Brittany Sinclair,
BVSc(hons), DACVECC

IMAGING PERFORMED BY

Dr. Arms

ULTRASONOGRAPHIC FINDINGS

HOSPITAL NAME

Gilbetsville VH

Primary Findings

1. Splenic myelolipomas
2. Degenerative renal changes
3. No sublumbar lymphadenopathy

REFERRING VET

Dr. Arms

INTERPRETATION OF THE FINDINGS & FURTHER RECOMMENDATIONS

No signs of sublumbar lymphadenopathy or other significant concern for intra-abdominal metastasis of anal gland mass or other cause of hypercalcemia.

INVOICE

43146

Splenic changes are a common age related change and nodules are most consistent with benign myelolipomas. Fine needle aspirate could be considered to further characterize parenchymal changes if clinically indicated.

DATE

3/7/23

Renal changes are likely age related degeneration. Correlate clinical significance with blood work/urinalysis findings and clinical signs.



PATIENT

Emma Cosby

SPECIES

Canine

BREED

Corgi

SEX

Spayed female

AGE

12 years

WEIGHT

41.8 lbs

INTERPRETED BY

Dr Brittany Sinclair,
BVSc(hons), DACVECC

IMAGING PERFORMED BY

Dr. Arms

HOSPITAL NAME

Gilbetsville VH

REFERRING VET

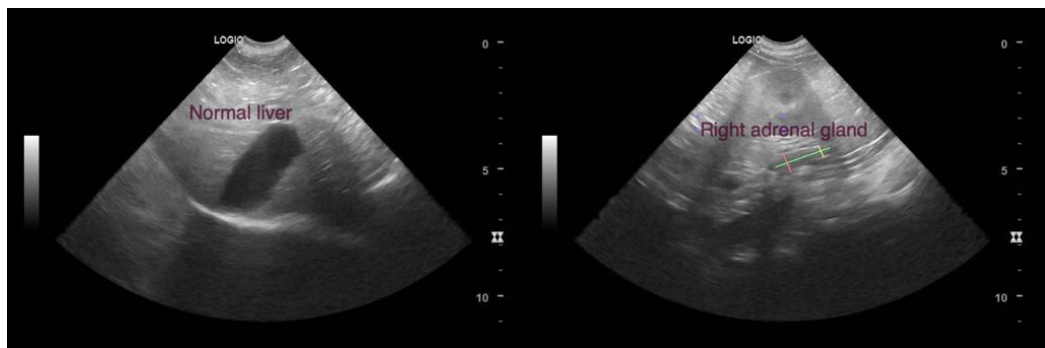
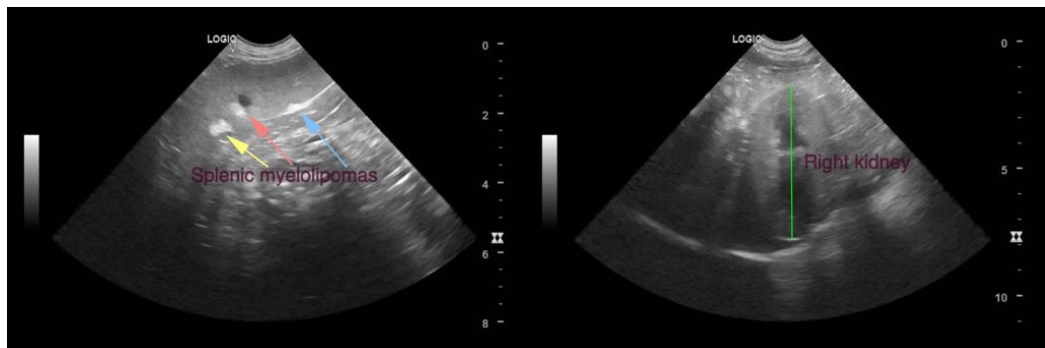
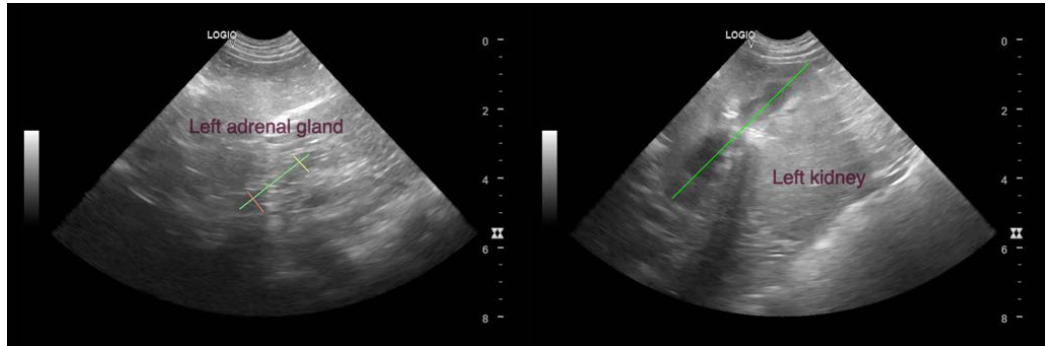
Dr. Arms

INVOICE

43146

DATE

3/7/23



The information and recommendations provided are based on the images presented by the referring veterinarian/sonographer. No evaluation can be communicated regarding pathology that was not visible in the image/video clips provided.

Thank you for this referral. If the clinical or image interpretation does not parallel your findings or if I can be of any further assistance please contact me.

Dr Brittany Sinclair, BVSc(hons), DACVECC
info@SonoPath.com