SonoPath
Clinical Sonography & Telecytology

EDUCATIONAL TELECONSULTATION SERVICES™

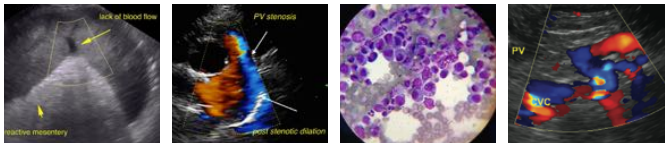

SonoPath.com™
1-800-838-4268 info@sonopath.com

PATIENT
Dually Hudson

SPECIES
Canine

BREED
Bernese Mountain Dog

SEX
Neutered male

AGE
4 years

WEIGHT
100.4 lbs

INTERPRETED BY
Dr Brittany Sinclair, BVSc(hons), DACVECC

IMAGING PERFORMED BY
Dr. Brenner

HOSPITAL NAME
Riverside AC

REFERRING VET
Dr. Brenner

INVOICE
43033

DATE
2/28/23

PRESENTING CLINICAL SIGNS

Acute onset vomiting last night. Current Leptospirosis vaccine.
Abnormal PE/Chem/CBC/UA Results: Exam normal 2/28/23. CBC normal Chem ALT 838 (10-125), AST 657 (0-50), Tbili 2.7 (0-0.9).

ULTRASONOGRAPHIC EXAMINATION OF THE ABDOMEN

Urinary System

The urinary bladder, trigone, and visible pelvic urethra were of normal thickness. The ureters were not visible which is normal. There was normal wall layering with no masses, uroliths or abnormal thickening visualized. Urine was anechoic. No evidence of inflammatory or neoplastic changes were noted.

The kidneys have a smooth capsule and with hazing of corticomedullary definition to the point of inability to determine cortical/medullary ratio. No evidence of pelvic dilation was present. The left kidney measured 6.22 cm and the right kidney measured 6.95 cm.

Adrenal Glands

Both adrenal glands were visualized and were subjectively small for a patient this size, with normal shape, position and echogenicity for this breed. The visualized phrenic vasculature, glandular echogenicity and detail were unremarkable. Capsule, cortex, and medullary definition were normal for this age patient. The left adrenal gland measured 2.56 cm in length x 0.36 cm at the caudal pole and 0.36 cm at the cranial pole. The right adrenal gland measured 1.71 cm in length x 0.41 cm at the caudal pole and 0.36 cm at the cranial pole.

Spleen

The spleen was subjectively mildly enlarged with a slightly heterogenous hyperechoic parenchyma with normal splenic vasculature with no signs of congestion or thrombosis. No specific nodules or masses were visualized.

Liver

The liver is subjectively normal in size with normal contours and structure. There is appropriate echogenicity and echotexture. No overt structural evidence of inflammatory, infiltrative or regenerative pathology is evident. Vascular and biliary tracts are of normal volume with no evidence of congestion. No pathological hepatic lymphadenopathy observed. The gall bladder is moderately distended with anechoic fluid, with hyperechoic non-shadowing debris present. There is no surrounding free fluid or signs of active inflammation.

Gastrointestinal

The stomach contains minimal luminal contents. It measures at a normal thickness of with some variability due to the presence of rugal folds. The distinction of the gastric wall layers is adequate and there is no impression of reduced peristaltic activity. No masses or focal lesions were observed. The visualized areas of duodenum, jejunum and ileum have a relatively uniform diameter with minimal fluid distension. Wall thickness is normal. Bowel loops follow a curvilinear path with distinct wall layering maintaining the typical 1:3 muscularis:mucosa layer ratio. Visualized peristalsis appears appropriate.

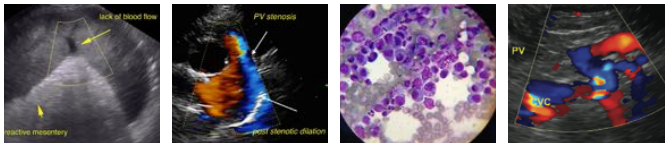

SonoPath.com™
1-800-838-4268 info@sonopath.com

PATIENT
Dually Hudson

SPECIES
Canine

BREED
Bernese Mountain Dog

SEX
Neutered male

AGE
4 years

WEIGHT
100.4 lbs

INTERPRETED BY
Dr Brittany Sinclair, BVSc(hons), DACVECC

IMAGING PERFORMED BY
Dr. Brenner

HOSPITAL NAME
Riverside AC

REFERRING VET
Dr. Brenner

INVOICE
43033

DATE
2/28/23

There were no focal lesions consistent with obstruction or a mass effect observed. The ileocecal junction was visualized and exhibited normal intact wall layering and is subjectively of normal thickness. Sections of colon are visualized with formed fecal material and gas shadowing distally. There is no observed focal or generalized colon wall thickening or loss of layering.

Pancreas

The base and limbs of the pancreas were observed to be largely isoechoic to surrounding omental fat. Pancreatic duct and capsular contour and parenchyma were normal. No overt evidence of active inflammatory or neoplastic disease was noted.

Lymph Nodes

No clinically significant lymphadenopathy or abnormalities noted.

Free Abdomen

No masses or free fluid were noted.

ULTRASONOGRAPHIC FINDINGS

Primary Findings

1. Normal liver
2. Gall bladder debris
3. Mild splenomegaly
4. Small adrenal glands

INTERPRETATION OF THE FINDINGS & FURTHER RECOMMENDATIONS

The liver appears sonographically normal, and the gall bladder and common bile duct are normal in this patient. In light of lack of anemia and no evidence of hemolytic disease, the bilirubin elevation must be owing to hepatic parenchymal disease. Liver FNA is indicated. Acute hepatotoxin, infectious or inflammatory hepatitis (bacterial, viral, auto-immune other), and neoplasia among other things remain possibilities.

Gall bladder debris may be an incidental finding given lack of surrounding inflammation. In the face of elevated ALKP ursodiol could be given as a choleretic and empiric treatments (SAM-E, milk thistle, Vitamin E) could be tried. If liver supportive medications do not improve liver enzymes, a course of empiric antibiotics (clavamox, enrofloxacin) could be considered to cover for infectious cholangiohepatitis, though the lack of surrounding inflammation makes this less likely. Imaging should be rechecked on a routine basis for monitoring (q3-6mo) or if further significant increase in liver enzymes and/or new clinical signs are noted. If otherwise clinically indicated, investigation for endocrinopathy such as hyperadrenocorticism or hypothyroidism could be considered as an underlying cause predisposing to gall bladder debris accumulation.

Splenomegaly with hyperechoic parenchyma is concerning for infiltrative disease such as lymphoma or mast cell tumor, and splenic aspirate is recommended. This may be a benign reactive or inflammatory change, or could reflect extramedullary hematopoiesis.

SonoPath
Clinical Sonography & Telecytology

EDUCATIONAL TELECONSULTATION SERVICES™

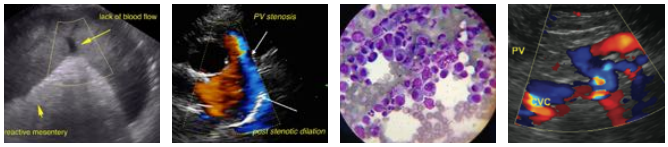

SonoPath.com™
1-800-838-4268 info@sonopath.com

PATIENT

Dually Hudson

SPECIES

Canine

BREED

Bernese Mountain Dog

SEX

Neutered male

AGE

4 years

WEIGHT

100.4 lbs

INTERPRETED BY

Dr Brittany Sinclair, BVSc(hons), DACVECC

IMAGING PERFORMED BY

Dr. Brenner

HOSPITAL NAME

Riverside AC

REFERRING VET

Dr. Brenner

INVOICE

43033

DATE

2/28/23

Adrenal gland size is variable. This patients adrenal glands are subjectively small in size which can occur due to exogenous glucocorticoid use, be a variation of normal or may represent hypoadrenocorticism. Assessment of baseline cortisol +/- ACTH stimulation test is recommended if clinically warranted.

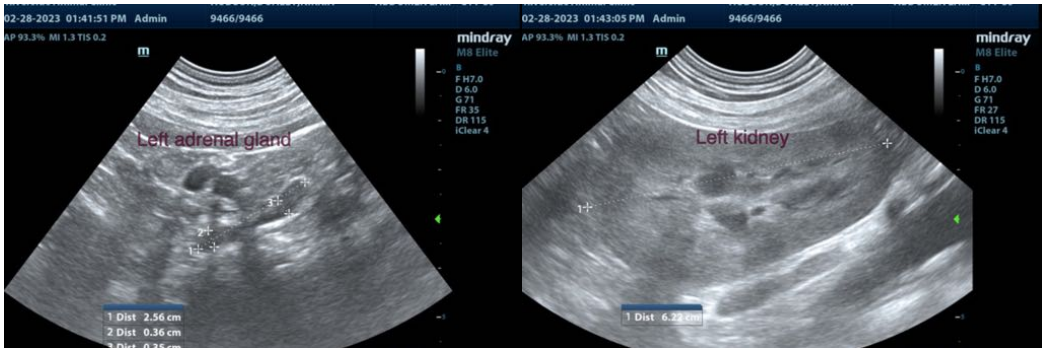

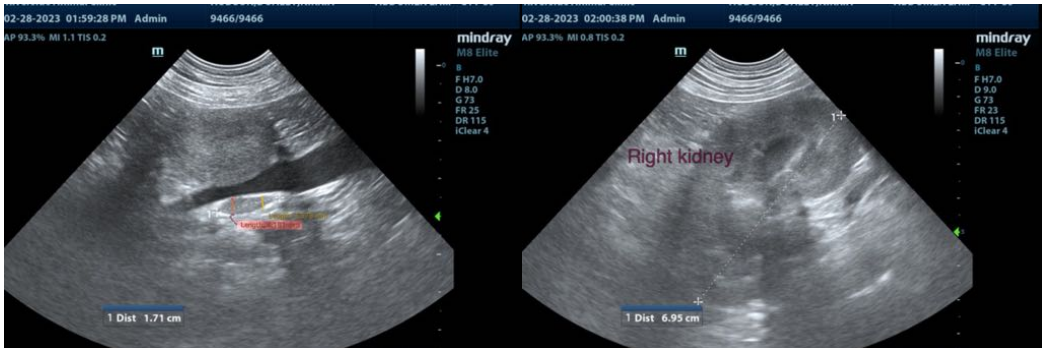

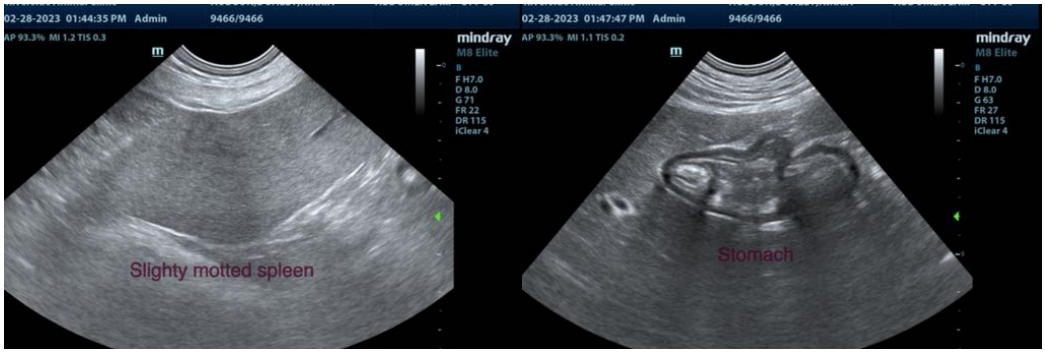

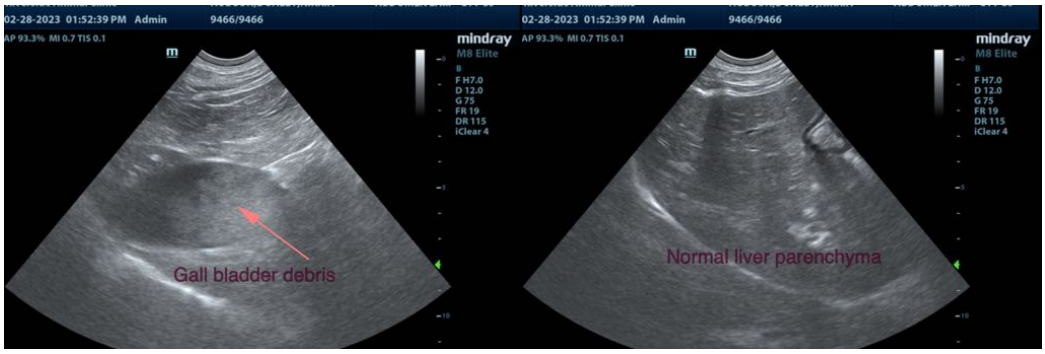

SonoPath
Clinical Sonography & Telecytology

EDUCATIONAL TELECONSULTATION SERVICES™

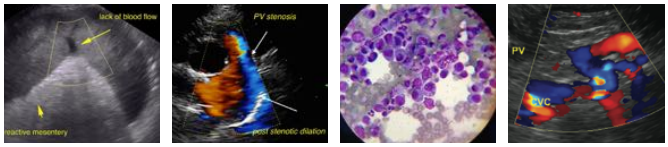

SonoPath.com™
1-800-838-4268 info@sonopath.com

PATIENT

Dually Hudson

SPECIES

Canine

BREED

Bernese Mountain Dog

SEX

Neutered male

AGE

4 years

WEIGHT

100.4 lbs

INTERPRETED BY

Dr Brittany Sinclair, BVSc(hons), DACVECC

IMAGING PERFORMED BY

Dr. Brenner

HOSPITAL NAME

Riverside AC

REFERRING VET

Dr. Brenner

INVOICE

43033

DATE

2/28/23

The information and recommendations provided are based on the images presented by the referring veterinarian/sonographer. No evaluation can be communicated regarding pathology that was not visible in the image/video clips provided.

Thank you for this referral. If the clinical or image interpretation does not parallel your findings or if I can be of any further assistance please contact me.

Dr Brittany Sinclair, BVSc(hons), DACVECC
info@SonoPath.com