



PATIENT PRESENTING CLINICAL SIGNS

Sophie Kroon

History: 1 week history of vomiting and anorexia, chronic PU/PD with no polyphagia. No recent increase in PU/PD.

SPECIES

Canine

Abnormal PE/Chem/CBC/UA Results: PE- Tense with abdominal palpation. CBC: Chem: 10/25-ALT= 174 (20-150), ALP= 469 (20-150), BUN> 180 (7-25), Ca= 1..9 (8.6-11.8), Phos= 16.4 (2.9-8.6), Cre= 6.3 (0.3-1.4) Kidney panel 10/26: BUN= 173 (7-25), Cre= 3.9 (0.3-1.4), Phos= 8.3 (2.9-6.6), tCo2= 27 (12-27) U/A: U.S.G.= 1.015, pH= 6.0, inactive sediment Urine culture pending

BREED

Dachshund

ULTRASONOGRAPHIC EXAMINATION OF THE ABDOMEN

Urinary System

SEX

Spayed female

The urinary bladder, trigone, and visible pelvic urethra were of normal thickness. The ureters were not visible which is normal. There was normal wall layering with no masses, uroliths or abnormal thickening visualized. Urine was anechoic. No evidence of inflammatory or neoplastic changes were noted.

AGE

13 years

The left kidney has a smooth capsule and with hazing of corticomedullary definition to the point of inability to determine cortical/medullary ratio. No evidence of pelvic dilation was present. The right kidney has an irregular capsule and with hazing of corticomedullary definition to the point of inability to determine cortical/medullary ratio. Areas of indentation in renal capsule with underlying triangular shaped hypoechoic parenchyma consistent with an area of previous infarct was visualized. No evidence of pelvic dilation was present. The left kidney measured 4.1 cm and the right kidney measured 4.8 cm.

WEIGHT

15.4 lbs

Adrenal Glands

INTERPRETED BY

Dr Brittany Sinclair, BVSc(hons), DACVECC

Left adrenal gland is abnormal with an enlarged caudal pole and hypoechoic nodule consistent with hormonal hyperstimulation or adrenal gland mass. Capsule, cortex, and medullary definition were normal for this age patient. No overt vascular invasion is observed. The left adrenal gland measured 1.83 cm in length x 0.84 cm at the caudal pole and 0.47 cm at the cranial pole.

IMAGING PERFORMED BY

Dr. Ertunc

Right adrenal gland is enlarged and irregular. Normal structure is effaced by abnormal tissue with heterogenous echotexture containing a 1.5cm x 0.96cm hyperechoic mottled nodule. Vasculature surrounding right adrenal gland has turbulent flow and there is significant concern for vascular invasion. The right adrenal gland measured 2.3 cm in length x 1.3 cm in width.

HOSPITAL NAME

Healing Spirit Animal Wellness

Spleen

REFERRING VET

Dr. Ertunc

The spleen was normal with a smooth homogeneous parenchyma hyperechoic to liver and renal cortical parenchyma and smooth capsule, with normal splenic vasculature with no signs of congestion or thrombosis. No sonographic evidence of acute or chronic inflammatory, neoplastic, or infarct changes were noted.

INVOICE

42342

Liver

DATE

12/26/22

The liver is subjectively normal in size with normal contours and structure. There is appropriate echogenicity and echotexture. No overt structural evidence of inflammatory, infiltrative or regenerative pathology is evident. Vascular and biliary tracts are of normal volume with no evidence of congestion. No pathological hepatic lymphadenopathy observed. Gallbladder is moderately distended with normal wall thickness and anechoic contents. Common bile duct is non-distended and tapers normally



PATIENT

Sophie Kroon

SPECIES

Canine

BREED

Dachshund

SEX

Spayed female

AGE

13 years

WEIGHT

15.4 lbs

INTERPRETED BY

Dr Brittany Sinclair,
BVSc(hons), DACVECC

IMAGING PERFORMED BY

Dr. Ertunc

HOSPITAL NAME

Healing Spirit Animal
Wellness

REFERRING VET

Dr. Ertunc

INVOICE

42342

DATE

12/26/22

Gastrointestinal

The stomach contains minimal luminal contents. It measures at a normal thickness of with some variability due to the presence of rugal folds. The distinction of the gastric wall layers is adequate and there is no impression of reduced peristaltic activity. No masses or focal lesions were observed. The visualized areas of duodenum, jejunum and ileum have a relatively uniform diameter with minimal fluid distension. Wall thickness is normal. Bowel loops follow a curvilinear path with distinct wall layering maintaining the typical 1:3 muscularis:mucosa layer ratio. Visualized peristalsis appears appropriate. There were no focal lesions consistent with obstruction or a mass effect observed. The ileocecal junction was visualized and exhibited normal intact wall layering and is subjectively of normal thickness. Sections of colon are visualized with formed fecal material and gas shadowing distally. There is no observed focal or generalized colon wall thickening or loss of layering.

Pancreas

The base and limbs of the pancreas were observed to be largely isoechoic to surrounding omental fat. Pancreatic duct and capsular contour and parenchyma were normal. No overt evidence of active inflammatory or neoplastic disease was noted.

Lymph Nodes

No clinically significant lymphadenopathy or abnormalities noted.

Free Abdomen

No masses or free fluid was noted.

ULTRASONOGRAPHIC FINDINGS

Primary Findings

1. Right adrenal gland mass with vascular invasion
2. Left adrenal gland prominent
3. Moderate degenerative renal changes

INTERPRETATION OF THE FINDINGS & FURTHER RECOMMENDATIONS

The most concerning finding is the right adrenal gland mass which appears to be invading the local vasculature. An adrenal carcinoma or pheochromocytoma, is considered most likely, which is locally invasive and may have distant metastasis. Adrenal adenoma, or less likely glucocorticoid secreting tumor among others remain possibilities. Thoracic radiographs are recommended to further assess for metastasis. Left adrenomegaly may represent hypertrophy in hormonal response to a hormonally inactive right adrenal gland or may represent metastatic adrenal neoplasia. It is also possible to have pituitary dependent hyperadrenocorticism affecting the left adrenal gland and a neoplastic process in the right adrenal gland, or less likely bilateral, non-related adrenal neoplastic processes. Right adrenalectomy may be considered but should be undertaken by a skilled surgeon and abdominal CT to



PATIENT

Sophie Kroon

SPECIES

Canine

BREED

Dachshund

SEX

Spayed female

AGE

13 years

WEIGHT

15.4 lbs

INTERPRETED BY

Dr Brittany Sinclair,
BVSc(hons), DACVECC

IMAGING PERFORMED BY

Dr. Ertunc

HOSPITAL NAME

Healing Spirit Animal
Wellness

REFERRING VET

Dr. Ertunc

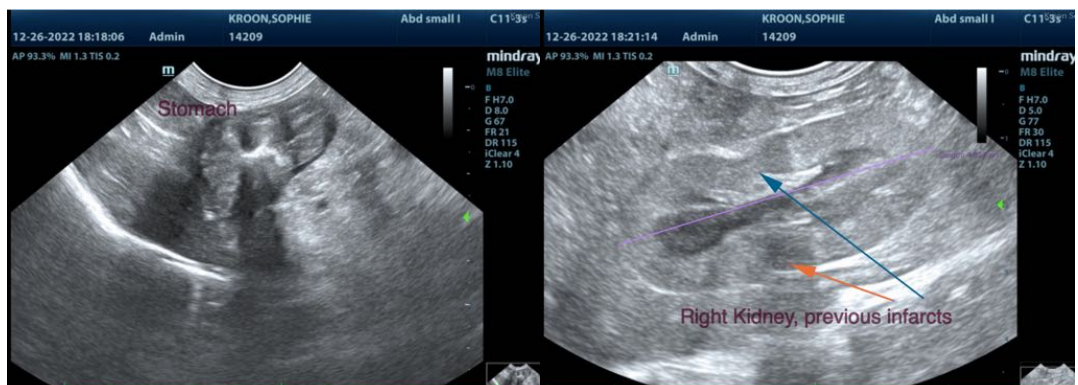
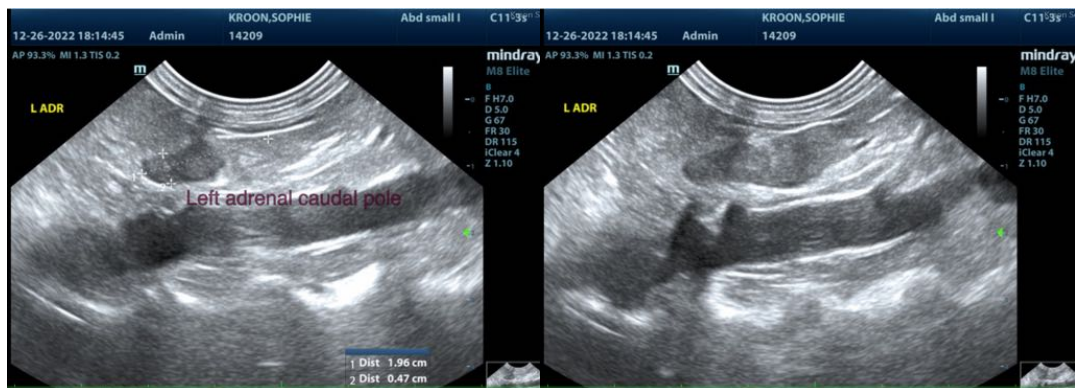
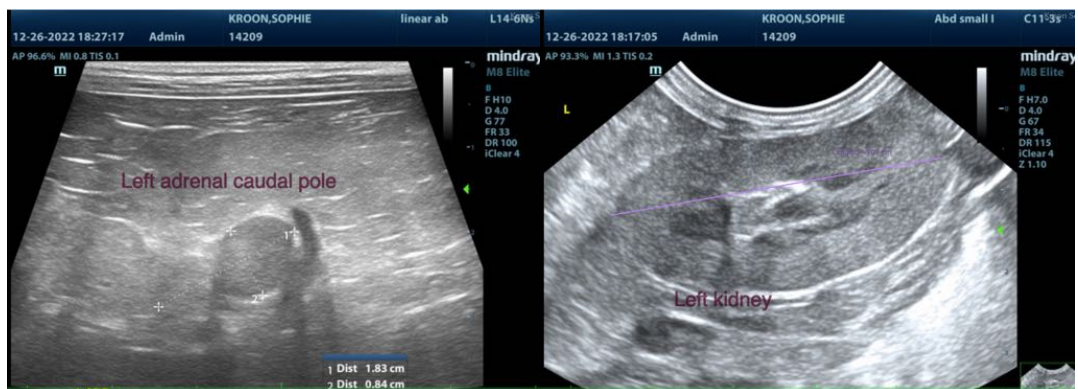
INVOICE

42342

DATE

12/26/22

further characterize the vascular invasion may be required. Prior to adrenalectomy urine metanephrine screening should be done to assess for pheochromocytoma as perioperative mortality is very high if pretreatment with phenoxybenzamine is not undertaken. Renal changes appear chronic and degenerative and account for severe azotemia noted in bloodwork. Severe hypocalcemia reported (1.9 ref 8.6-11.8) is likely spurious but should be rechecked for confirmation and if persistent confirmed with ionized calcium measurement.





PATIENT

Sophie Kroon

SPECIES

Canine

BREED

Dachshund

SEX

Spayed female

AGE

13 years

WEIGHT

15.4 lbs

INTERPRETED BY

Dr Brittany Sinclair, BVSc(hons), DACVECC

IMAGING PERFORMED BY

Dr. Ertunc

HOSPITAL NAME

Healing Spirit Animal Wellness

REFERRING VET

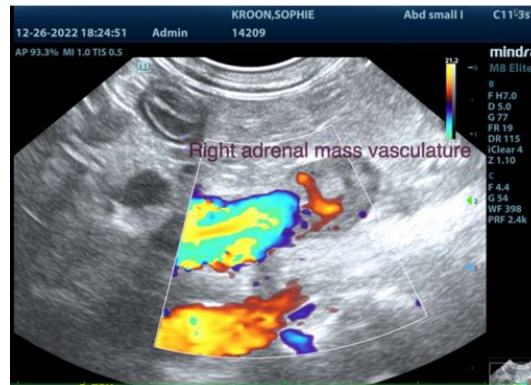
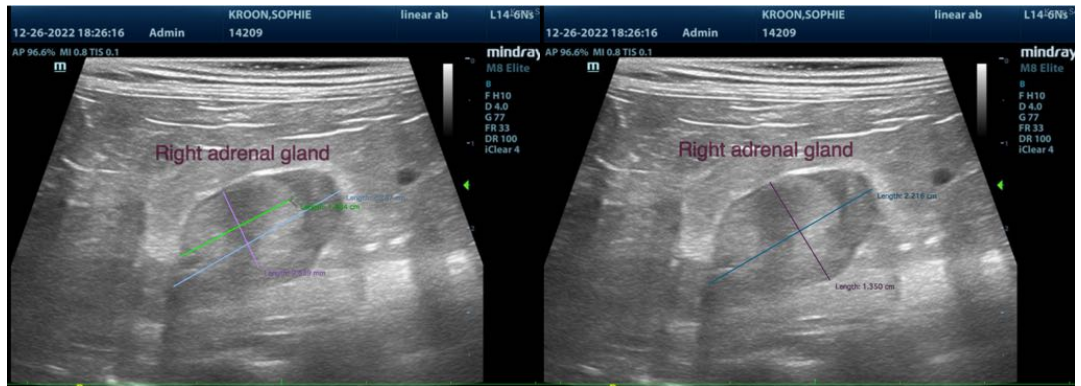
Dr. Ertunc

INVOICE

42342

DATE

12/26/22



The information and recommendations provided are based on the images presented by the referring veterinarian/sonographer. No evaluation can be communicated regarding pathology that was not visible in the image/video clips provided.

Thank you for this referral. If the clinical or image interpretation does not parallel your findings or if I can be of any further assistance please contact me.

Dr Brittany Sinclair, BVSc(hons), DACVECC
info@SonoPath.com