



PATIENT

Cooper Carley

SPECIES

Feline

BREED

Domestic Shorthair

SEX

Spayed female

AGE

12 years

WEIGHT

8.55 lbs

INTERPRETED BY

Dr Brittany Sinclair,
BVSc(hons), DACVECC

IMAGING PERFORMED BY

Dr. Sheldon

HOSPITAL NAME

Advanced Pet Care of
Oakland

REFERRING VET

Dr. Sheldon

INVOICE

423340

DATE

12/26/22

PRESENTING CLINICAL SIGNS

History: 3 mo history of azotemia - prior hypertensive concerns - resolved/normotensive 12/21. O notes long history of chronic vomiting - not improved with diet change. Bloodwork 12/21/22 - BUN 46, Creat 2.6, AST 61 HI rest nsf. Prior 10/22 bloodwork - Creat 3.0, BUN 44

ULTRASONOGRAPHIC EXAMINATION OF THE ABDOMEN

Urinary System

The urinary bladder, trigone, and visible pelvic urethra were of normal thickness. The ureters were not visible which is normal. There was normal wall layering with no masses, uroliths or abnormal thickening visualized. Urine was anechoic. No evidence of inflammatory or neoplastic changes were noted.

The kidneys have a smooth capsule and with hazing of corticomedullary definition to the point of inability to determine cortical/medullary ratio. No evidence of pelvic dilation was present. The left kidney measured 3.14 cm and the right kidney measured 3.28 cm.

Adrenal Glands

Both adrenal glands were visualized and recognized as having normal shape, size, position and echogenicity for this breed. The phrenic vasculature, glandular echogenicity and detail were unremarkable. Capsule, cortex, and medullary definition were normal for this age patient. The left adrenal gland measured 0.6 cm in length and 0.15 cm at the cranial pole and 0.13 cm at the caudal pole. The right adrenal gland measured 0.83 cm at the cranial pole and 0.25 cm at the caudal pole.

Spleen

The spleen was normal with a smooth homogeneous parenchyma hyperechoic to liver and renal cortical parenchyma and smooth capsule, with normal splenic vasculature with no signs of congestion or thrombosis. No sonographic evidence of acute or chronic inflammatory, neoplastic, or infarct changes were noted.

Liver

The liver is subjectively normal in size with normal contours and structure. There is appropriate echogenicity and echotexture. No overt structural evidence of inflammatory, infiltrative or regenerative pathology is evident. Vascular and biliary tracts are of normal volume with no evidence of congestion. No pathological hepatic lymphadenopathy observed. Gallbladder is moderately distended with normal wall thickness and anechoic contents. Common bile duct is non-distended and tapers normally

Gastrointestinal

The stomach contains minimal luminal contents. The fundic mucosa is thickened measuring up to 0.56 cm with maintenance of wall layering and other parts of the stomach appear normal in thickness with some variability due to the presence of rugal folds. The distinction of the gastric wall layers is adequate and there is no impression of reduced peristaltic activity.



PATIENT

Cooper Carley

The visualized areas of duodenum, jejunum and ileum have a relatively uniform diameter with minimal fluid distension. Wall thickness is increased but bowel loops follow a curvilinear path with distinct wall layering maintaining the typical 1:3 muscularis:mucosa layer ratio. Visualized peristalsis appears appropriate. There were no focal lesions consistent with obstruction or a mass effect observed. The ileocecal junction was visualized and exhibited normal intact wall layering and is subjectively of normal thickness.

SPECIES

Feline

Sections of colon are visualized with formed fecal material and gas shadowing distally. There is no observed focal or generalized colon wall thickening or loss of layering.

BREED

Domestic Shorthair

Pancreas

SEX

Spayed female

The base and limbs of the pancreas were observed to be largely isoechoic to surrounding omental fat. Pancreatic duct and capsular contour and parenchyma were normal. No overt evidence of active inflammatory or neoplastic disease was noted.

AGE

12 years

Lymph Nodes

No clinically significant lymphadenopathy or abnormalities noted.

WEIGHT

8.55 lbs

Free Abdomen

No masses or free fluid

INTERPRETED BY

Dr Brittany Sinclair,
BVSc(hons), DACVECC

ULTRASONOGRAPHIC FINDINGS

Primary Findings

IMAGING PERFORMED BY

Dr. Sheldon

1. Chronic degenerative renal changes
2. Focal gastric mucosa thickening
3. Thickened small intestinal loops with maintenance of wall layering

HOSPITAL NAME

Advanced Pet Care of
Oakland

INTERPRETATION OF THE FINDINGS & FURTHER RECOMMENDATIONS

Renal changes are consistent with age related degeneration and decreased renal function is the likely explanation for azotemia – correlate with urinalysis findings. Focal gastric wall thickening likely represents an area of focal gastritis. Small intestinal thickening with maintenance of wall layering may represent a variation of normal diameter or inflammatory disease such as enteritis. The absence of muscularis thickening makes infiltrative disease such as inflammatory bowel disease or intestinal neoplasia less likely. Dietary indiscretion or protein hypersensitivity/allergy is a likely possibility and trial with select protein diet could be considered. Uremic gastroenteritis is a less likely explanation given the mild degree of azotemia. Ultimately GI biopsy could be considered to further characterize the GI thickening and focal gastric thickening if clinically indicated. Follow-up sonograms are recommended especially if the patient is not responding to empirical efforts. Endoscopic biopsy is less invasive but may miss lesions due to inability to sample more than top 1-2 layers of GI tract and inability to obtain samples from all sections of the GI tract. Surgical biopsies are more likely to be diagnostic but are more invasive. A GI panel (PLI/cobalamin/folate) will help determine the severity of SI dysfunction, and need for vitamin supplementation.

REFERRING VET

Dr. Sheldon

INVOICE

423340

DATE

12/26/22



PATIENT

Cooper Carley

SPECIES

Feline

BREED

Domestic Shorthair

SEX

Spayed female

AGE

12 years

WEIGHT

8.55 lbs

INTERPRETED BY

Dr Brittany Sinclair,
BVSc(hons), DACVECC

IMAGING PERFORMED BY

Dr. Sheldon

HOSPITAL NAME

Advanced Pet Care of
Oakland

REFERRING VET

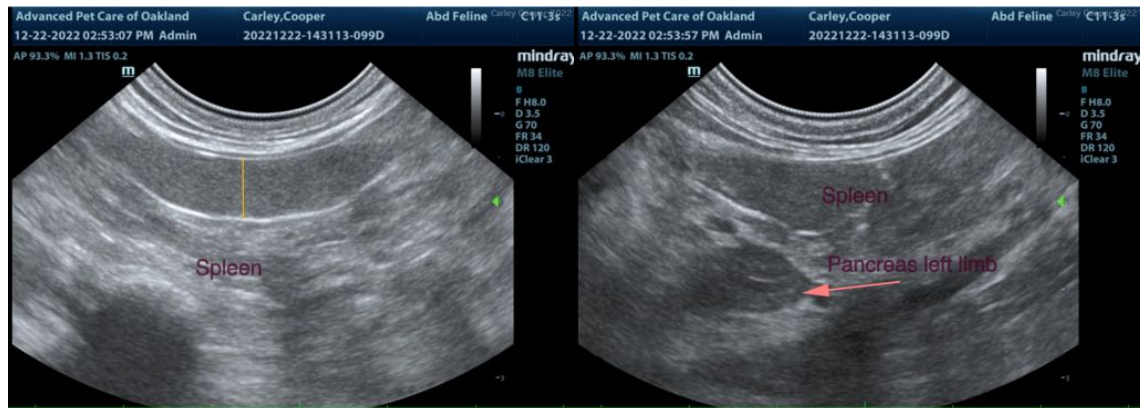
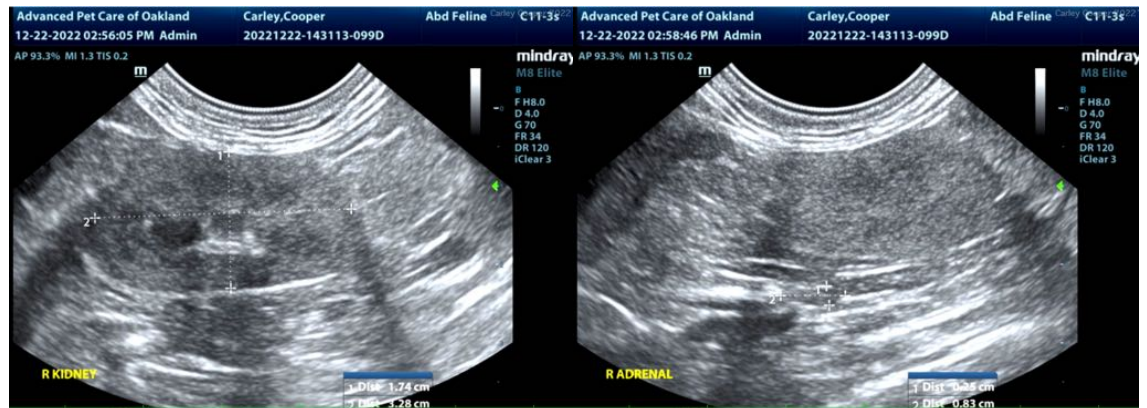
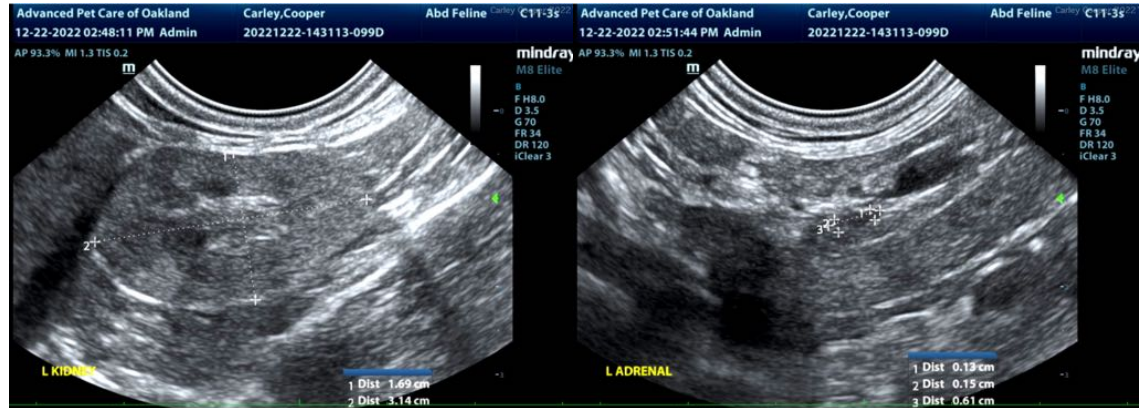
Dr. Sheldon

INVOICE

423340

DATE

12/26/22





PATIENT

Cooper Carley

SPECIES

Feline

BREED

Domestic Shorthair

SEX

Spayed female

AGE

12 years

WEIGHT

8.55 lbs

INTERPRETED BY

Dr Brittany Sinclair, BVSc(hons), DACVECC

IMAGING PERFORMED BY

Dr. Sheldon

HOSPITAL NAME

Advanced Pet Care of Oakland

REFERRING VET

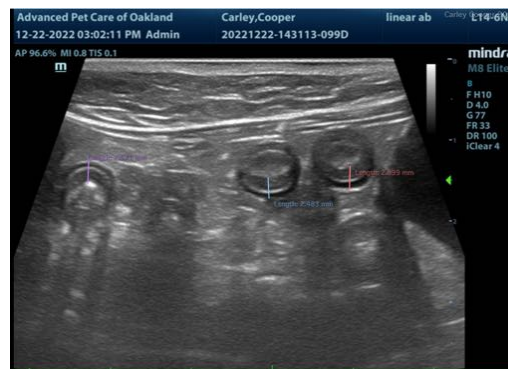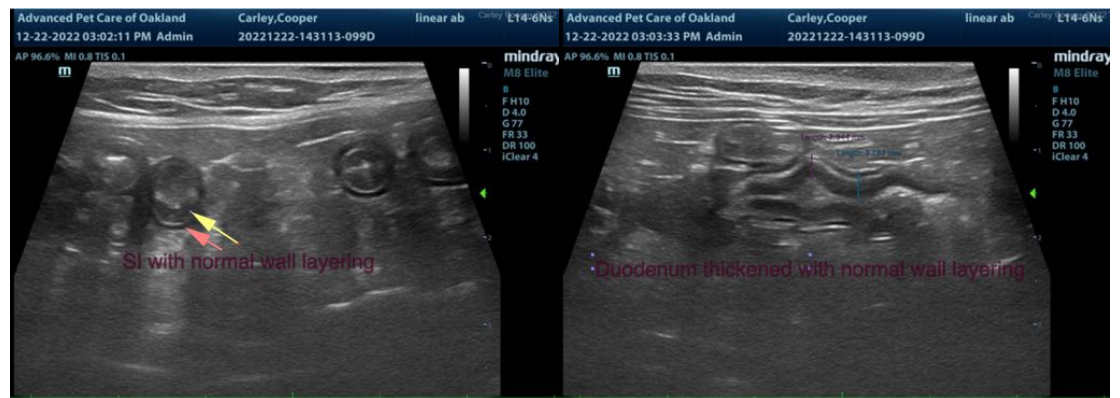
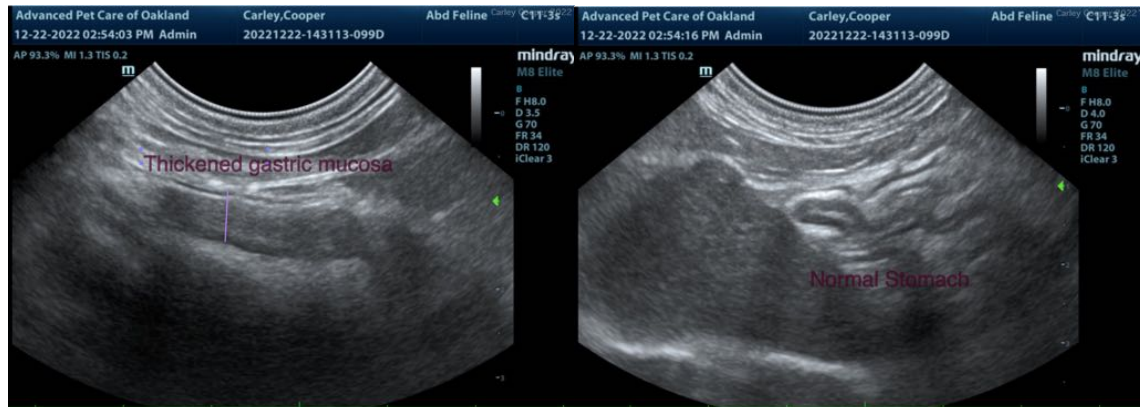
Dr. Sheldon

INVOICE

423340

DATE

12/26/22



The information and recommendations provided are based on the images presented by the referring veterinarian/sonographer. No evaluation can be communicated regarding pathology that was not visible in the image/video clips provided.

Thank you for this referral. If the clinical or image interpretation does not parallel your findings or if I can be of any further assistance please contact me.

Dr Brittany Sinclair, BVSc(hons), DACVECC
info@SonoPath.com