



PATIENT

Hughley Jenkins

SPECIES

Canine

BREED

Mix

SEX

Neutered male

AGE

7 years

WEIGHT

75.6 lbs

PRESENTING CLINICAL SIGNS

History: Hughley presents today for an u/s focusing on his urinary tract. Over the last few weeks, Rachel noticed that Hughley has been asking to go outside more frequently and will urinate several times while outside. Thirst level the same, no changes to the actual urine itself. Free catch urinalysis performed in October prior to onset of clinical signs showed USG: 1.040 with >50/hpf WBC and 3-5/hpf non-squamous epithelial cells. Recheck free catch urinalysis performed in November showed persistent WBC and 6-10/hpf non-squamous epithelial cells. Free catch AND cystocentesis urinalysis performed today were unremarkable - no epithelial cells, WBC, RBC, bacteria, crystals.

ULTRASONOGRAPHIC EXAMINATION OF THE ABDOMEN

Urinary System

The urinary bladder, trigone, and visible pelvic urethra were of normal thickness. The ureters were not visible which is normal. There was normal wall layering with no masses, uroliths or abnormal thickening visualized. Urine was anechoic. No evidence of inflammatory or neoplastic changes were noted.

The prostate was not imaged.

The kidneys were both normal size and structure, with smooth capsule and normal corticomedullary definition and ratio (cortex 1/3 of medulla). Medullary structure differed distinctly from that of the cortex. No evidence of pelvic dilation was present. The right kidney measured 6.6 cm. The left kidney measured 5.9 cm.

INTERPRETED BY

Dr Brittany Sinclair,
BVSc(hons), DACVECC

IMAGING PERFORMED BY

Dr. Puthoff

HOSPITAL NAME

Kings VH

REFERRING VET

Dr. Puthoff

INVOICE

42246

DATE

12/20/22

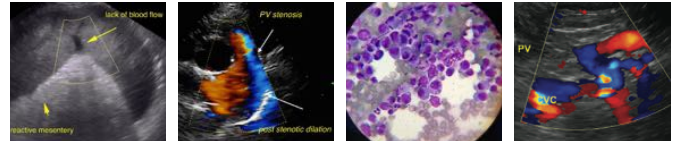
ULTRASONOGRAPHIC FINDINGS

Primary Findings

1. Normal kidneys
2. Normal urinary bladder

INTERPRETATION OF THE FINDINGS & FURTHER RECOMMENDATIONS

No cause of pollakiuria found on this ultrasound study. Prostate not visible on this study. No evidence of cystitis on ultrasound. Submission of urine culture could be considered to screen for occult UTI despite normal urinalysis findings.



PATIENT

Hughley Jenkins

SPECIES

Canine

BREED

Mix

SEX

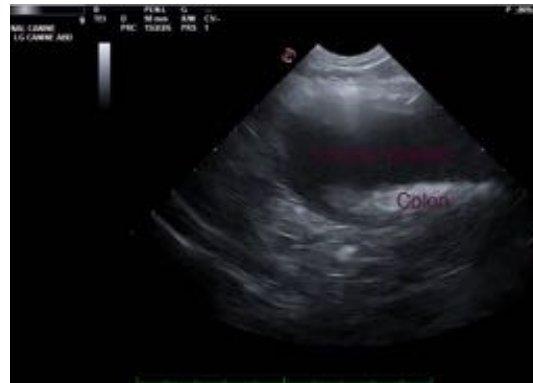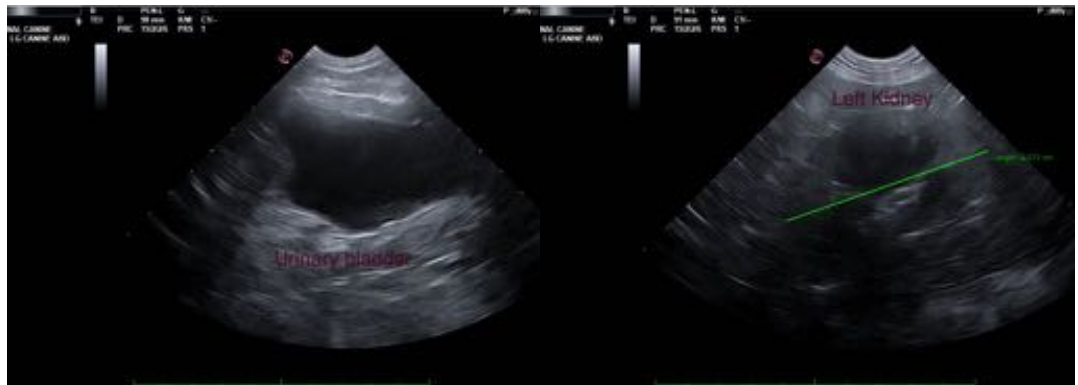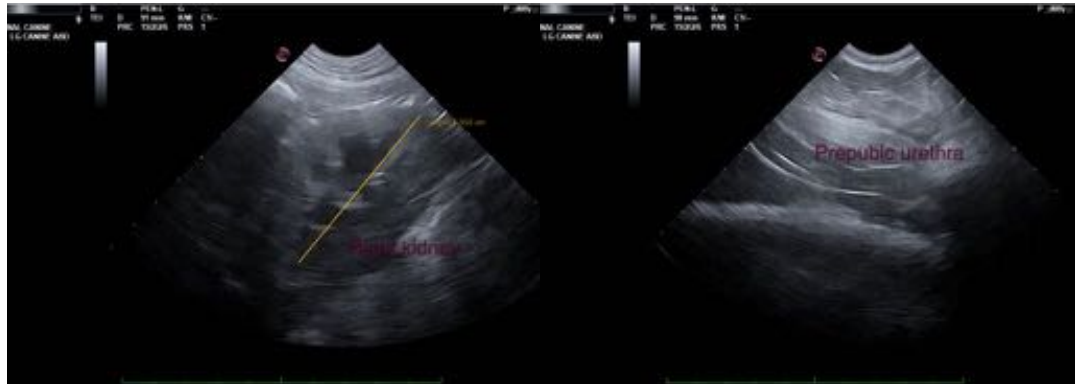Neutered male

AGE

7 years

WEIGHT

75.6 lbs



INTERPRETED BY

Dr Brittany Sinclair,
BVSc(hons), DACVECC

IMAGING PERFORMED BY

Dr. Puthoff

HOSPITAL NAME

Kings VH

REFERRING VET

Dr. Puthoff

INVOICE

42246

DATE

12/20/22

The information and recommendations provided are based on the images presented by the referring veterinarian/sonographer. No evaluation can be communicated regarding pathology that was not visible in the image/video clips provided.

Thank you for this referral. If the clinical or image interpretation does not parallel your findings or if I can be of any further assistance please contact me.

Dr Brittany Sinclair, BVSc(hons), DACVECC
info@SonoPath.com