



**PATIENT**

Aslan Bivens

**SPECIES**

Feline

**BREED**

DSH

**SEX**

Neutered Male

**AGE**

7 Years 11 Months

**WEIGHT**

9.2 lbs

**INTERPRETED BY**

Dr Brittany Sinclair,  
BVSc(hons), DACVECC

**IMAGING PERFORMED BY**

Kerri Becker

**HOSPITAL NAME**

Animal Care Centers of  
Flanders

**REFERRING VET**

Dr. Casulli

**INVOICE**

16269

**DATE**

06/03/26

**PRESENTING CLINICAL SIGNS**

Decrease appetite now, vomiting rule out gastric foreign body versus IBD

Abnormal PE/Chem/CBC/UA Results: Elev Eos

**ULTRASONOGRAPHIC EXAMINATION OF THE ABDOMEN**

*Urinary System*

The urinary bladder, trigone, and visible pelvic urethra were of normal thickness. The ureters were not visible which is normal. There was normal wall layering with no masses, uroliths or abnormal thickening visualized. Urine was anechoic. No evidence of inflammatory or neoplastic changes were noted.

The kidneys were both normal size and structure, with smooth capsule of the left kidney and a slightly irregular capsule of the right kidney with normal corticomedullary definition and ratio. Medullary structure differed distinctly from that of the cortex. No evidence of pelvic dilation was present. The left kidney measured 3.47 cm in length. The right kidney measured 3.32 cm in length.

*Adrenal Glands*

Adrenal glands are visualized and measured on still images only. Resolution is inadequate to assess glandular detail or confirm measurement. The left adrenal gland measured 0.27 cm in thickness. The right adrenal gland measured 0.33 cm in thickness.

*Spleen*

The spleen had a generally smooth homogeneous parenchyma and a smooth capsule with a solitary hyperechoic nodule visualized most consistent with benign myelolipoma. There was normal splenic vasculature with no signs of congestion or thrombosis. No sonographic evidence of acute or chronic inflammatory, neoplastic, or infarct changes were noted.

*Liver*

The liver is subjectively normal in size with normal contours and structure. There is age-appropriate echogenicity and echotexture. No overt structural evidence of inflammatory, infiltrative or regenerative pathology is evident. Vascular and biliary tracts are of normal volume with no evidence of congestion.

Gall bladder is moderately distended with normal wall thickness and anechoic contents. Common bile duct is non-distended and tapers normally.

*Gastrointestinal*

The stomach contains minimal luminal contents. It measures at a normal thickness of with some variability due to the presence of rugal folds. The distinction of the gastric wall layers is adequate. No masses or focal lesions were observed.

The visualized areas of duodenum, jejunum and ileum have a relatively uniform diameter with minimal fluid distension. Wall thickness is diffusely increased, and wall layering is distinct with a prominent muscularis layer. There were no focal lesions consistent with obstruction or a mass effect observed.



**PATIENT**

Aslan Bivens

The ileocecal junction was not visualized. Sections of colon are visualized with formed fecal material and gas shadowing distally. There is no observed focal or generalized colon wall thickening or loss of layering.

**SPECIES**

Feline

***Pancreas***

The area of the pancreas was isoechoic to surrounding tissue with no overt inflammation. Pancreatic tissue was not distinctly visualized which is common.

**BREED**

DSH

***Lymph Nodes***

No clinically significant lymphadenopathy or abnormalities noted.

**SEX**

Neutered Male

***Free Abdomen***

No masses or free fluid were noted.

**AGE**

7 Years 11 Months

**ULTRASONOGRAPHIC FINDINGS**

- Diffusely thickened small intestines with prominent muscularis.
- Solitary hyperechoic splenic nodule- likely benign myelolipoma.
- Slightly irregular right renal capsule- incidental.

**WEIGHT**

9.2 lbs

**INTERPRETATION OF THE FINDINGS & FURTHER RECOMMENDATIONS**

**INTERPRETED BY**

Dr Brittany Sinclair,  
BVSc(hons), DACVECC

Small intestinal changes are most consistent with infiltrative disease of the small intestine with inflammatory bowel disease or GI lymphoma being the top differentials. No overt neoplastic criteria present in the bowel given that curvilinear layering is still intact. Ultrasound cannot differentiate between small cell lymphoma and inflammatory bowel disease, and GI biopsies are recommended for definitive diagnosis, especially if there is a poor response to empirical efforts or recurrence of clinical signs after initial control. Endoscopic biopsy is less invasive but may miss lesions due to inability to obtain samples from all sections of the GI tract, especially the jejunum which is the most common site of development of disease. Surgical biopsies are more likely to be diagnostic but are more invasive. A GI panel (TLI/PLI/cobalamin/folate) will help determine the severity of SI dysfunction, and need for vitamin supplementation.

**IMAGING PERFORMED BY**

Kerri Becker

**HOSPITAL NAME**

Animal Care Centers of  
Flanders

Empiric treatment for IBD includes diet trial with either hydrolyzed or select protein diet, vitamin b-12 supplementation, GI support as needed (anti-nausea, appetite stimulant). Treatment with steroids (budesonide vs prednisolone) is often required – biopsies should be acquired prior to treatment with steroids. Steroids may ultimately be tapered to the lowest effective dose or discontinued in some cases.

**REFERRING VET**

Dr. Casulli

Splenic changes are a common age-related change and hyperechoic areas are most consistent with benign myelolipoma, but infiltrative disease (lymphoma, MCT, other) cannot be definitively ruled out. No significant disruption of architecture noted to suggest significant pathology. Fine needle aspirate could be considered to further characterize parenchymal changes if clinically indicated, especially if any weight loss is noted or for baseline cytological assessment.

**INVOICE**

16269

**DATE**

06/03/26



**PATIENT**

Aslan Bivens

**SPECIES**

Feline

**BREED**

DSH

**SEX**

Neutered Male

**AGE**

7 Years 11 Months

**WEIGHT**

9.2 lbs

**INTERPRETED BY**

Dr Brittany Sinclair,  
 BVSc(hons), DACVECC

**IMAGING PERFORMED BY**

Kerri Becker

**HOSPITAL NAME**

Animal Care Centers of  
 Flanders

**REFERRING VET**

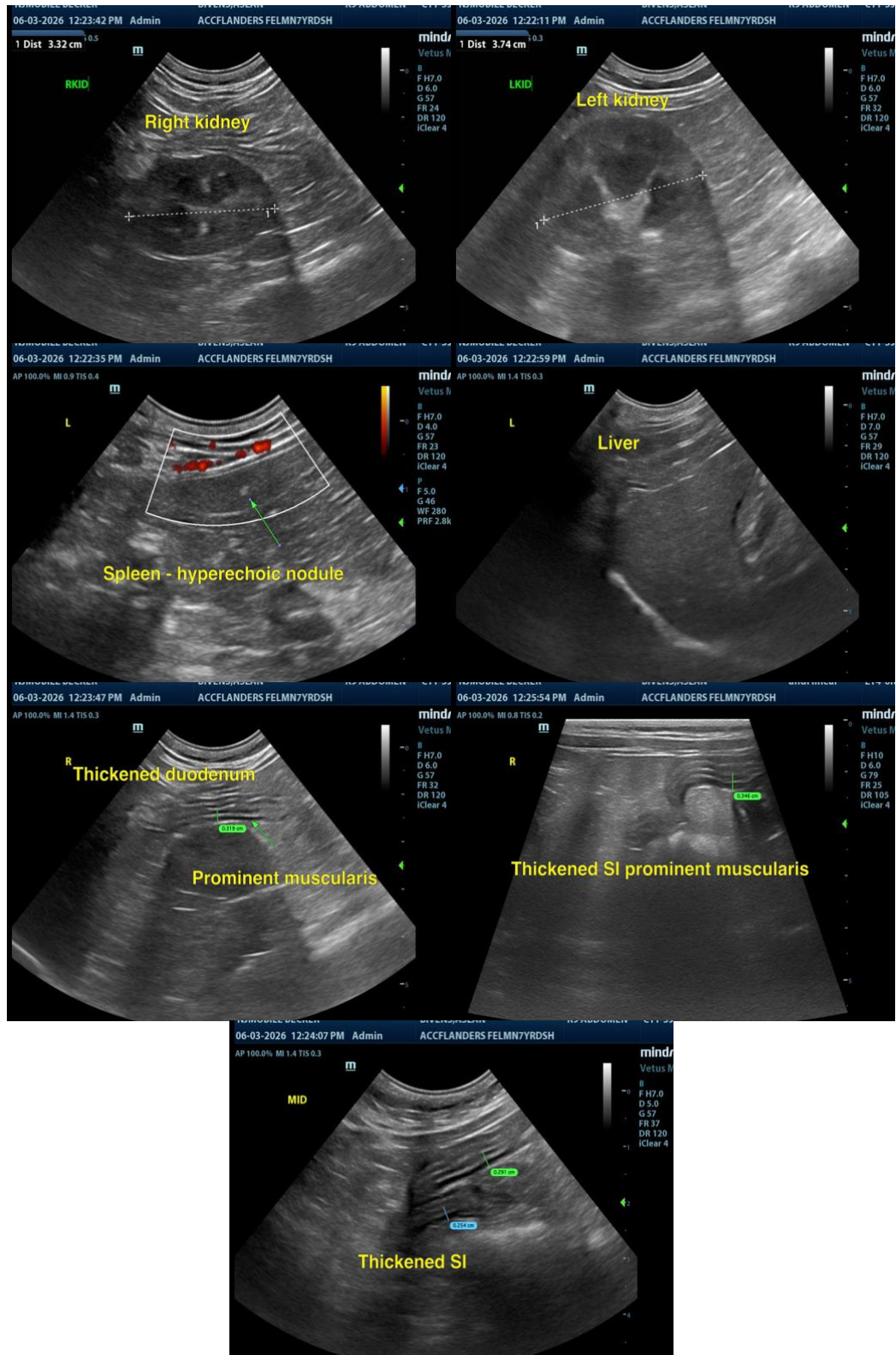
Dr. Casulli

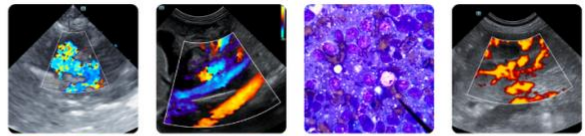
**INVOICE**

16269

**DATE**

06/03/26





**PATIENT**

Aslan Bivens

**SPECIES**

Feline

**BREED**

DSH

**SEX**

Neutered Male

**AGE**

7 Years 11 Months

**WEIGHT**

9.2 lbs

**INTERPRETED BY**

Dr Brittany Sinclair,  
BVSc(hons), DACVECC

**IMAGING  
PERFORMED BY**

Kerri Becker

**HOSPITAL NAME**

Animal Care Centers of  
Flanders

**REFERRING VET**

Dr. Casulli

**INVOICE**

16269

**DATE**

06/03/26

The information and recommendations provided are based on the images presented by the referring veterinarian/sonographer. No evaluation can be communicated regarding pathology that was not visible in the image/video clips provided.

Thank you for this referral. If the clinical or image interpretation does not parallel your findings or if I can be of any further assistance, please contact me.

Dr Brittany Sinclair, BVSc(hons), DACVECC

info@SonoPath.com