



## PATIENT

Nebu Velazquez

## SPECIES

Feline

## BREED

Domestic Shorthair

## SEX

Neutered Male

## AGE

8 Years 9 Months

## WEIGHT

9.8 lbs

## INTERPRETED BY

Dr Brittany Sinclair,  
BVSc(hons),  
DACVECC

## IMAGING PERFORMED BY

Gabriel Ferrer, DVM

## HOSPITAL NAME

Pulse: Pet Ultrasound

## REFERRING VET

Dr. Alma Alicea

## INVOICE

75329

## DATE

5/21/26

## PRESENTING CLINICAL SIGNS

Pt presented 5/16/26 to EC w/ acute onset of lethargy, anorexia, vomiting, for approx 3 days. icterus noted that day. multiple cat household, other cats ok. Pt has hx of recent diet change before problem started. Also, has had GI problems before with diet changes. Currently on maint. IV fluids, cerenia, famotidine, metronidazole, unasyn, simbadol, mirtazapine, esophageal tube placed 5/17. Also on Denamarin, ursodiol, hepatosupport via esophageal tube. Vit B-12 also given 5/16. Clinically patient continues to be anorexic, nauseas, icteric. Abdominal pain has improved but not completely resolved. No v/d. Concerns with pancreatitis, Triaditis, neoplasia (LSA?), hepatic lipidosis.

Abnormal PE/Chem/CBC/UA Results: Bloodwork and Radiographs attached as supporting documents cbc, chem (mildly elevated ALT/ALKP), fiv/felv (neg x 2), cPL 16.1, Bilirubin increased from 2.4 to 5.1, albumin was normal at first, now 2.2.

## ULTRASONOGRAPHIC EXAMINATION OF THE ABDOMEN

### Urinary System

The urinary bladder, trigone, and visible pelvic urethra were of normal thickness. The ureters were not visible which is normal. There was normal wall layering with no masses, uroliths or abnormal thickening visualized. Urine was anechoic. No evidence of inflammatory or neoplastic changes were noted.

The kidneys were both normal size and structure, with smooth capsule and normal corticomedullary definition and ratio. Medullary structure differed distinctly from that of the cortex. No evidence of pelvic dilation was present. Left kidney measures 3.93 cm. Right kidney measures 4.03 cm.

### Adrenal Glands

Both adrenal glands were visualized and recognized as having normal shape, size, position and echogenicity for this breed and age. The visible phrenic vasculature was unremarkable. Right measures 0.36 cm in thickness. Left measures 0.34 cm in thickness.

### Spleen

The spleen was normal with age appropriate homogeneous parenchyma and a smooth capsule with normal splenic vasculature with no signs of congestion or thrombosis. No sonographic evidence of acute or chronic inflammatory, neoplastic, or infarct changes were noted.

### Liver

The liver is subjectively enlarged in size with slight rounding of lobes and homogenous hyperechoic parenchyma with no specific nodules or masses. Vascular and biliary tracts are of normal volume with no evidence of congestion. No pathological hepatic lymphadenopathy observed.

Gall bladder is moderately distended with anechoic bile with some echogenic amorphous component within the lumen. The cystic and common bile ducts are dilated and slightly tortuous to the level of the duodenal papilla with scant surrounding free fluid.

### Gastrointestinal

The stomach contains minimal luminal contents. It measures at a normal thickness of with some variability due to the presence of rugal folds. The distinction of the gastric wall layers is adequate. No masses or focal lesions were observed.



## PATIENT

Nebu Velazquez

## SPECIES

Feline

## BREED

Domestic Shorthair

## SEX

Neutered Male

## AGE

8 Years 9 Months

## WEIGHT

9.8 lbs

## INTERPRETED BY

Dr Brittany Sinclair,  
BVSc(hons),  
DACVECC

## IMAGING PERFORMED BY

Gabriel Ferrer, DVM

## HOSPITAL NAME

Pulse: Pet Ultrasound

## REFERRING VET

Dr. Alma Alicea

## INVOICE

75329

## DATE

5/21/26

The visualized areas of duodenum, jejunum and ileum have a relatively uniform diameter with minimal fluid distension. Wall thickness is normal. Bowel loops follow a curvilinear path with distinct wall layering maintaining the typical 1:3 muscularis:mucosa layer ratio. There were no focal lesions consistent with obstruction or a mass effect observed.

The ileocecal junction was visualized and exhibited normal intact wall layering and is subjectively of normal thickness. Sections of colon are visualized with formed fecal material and gas shadowing distally. There is no observed focal or generalized colon wall thickening or loss of layering.

### **Pancreas**

Visible pancreas is enlarged and hypoechoic with surrounding hyperechoic mesentery. No fluid accumulations visualized. No mass effect consistent with pancreatic neoplasia visualized. =

### **Free Abdomen**

No clinically significant lymphadenopathy or abnormalities noted.

There is scant free fluid visualized between liver lobes around cystic/common bile ducts.

## **ULTRASONOGRAPHIC FINDINGS**

- Cholangiohepatitis
- Hyperechoic hepatomegaly – hepatitis +/- hepatic lipidosis versus other infiltrative disease.
- Pancreatitis.

## **INTERPRETATION OF THE FINDINGS & FURTHER RECOMMENDATIONS**

Pancreatic and gallbladder changes are consistent with cholangiohepatitis with concurrent pancreatitis. A version of feline Triaditis is possible. Ultrasonographically and together with worsening bloodwork, inflammation appears to be severe in this patient.

The prognosis of acute pancreatitis and cholangiohepatitis is largely dependent on the severity of clinical signs and response to treatment. Mortality is reported as high as 25% and secondary organ dysfunction and systemic inflammatory response syndrome can occur as inflammation progresses. Ultimately the need for hospitalization for treatment is based on the patient's cardiovascular stability, pain and appetite. Hydration and enteral nutrition are key factors in positive outcomes and if these cannot be achieved on an outpatient basis, hospitalization for 24 hour care is strongly recommended.

Treatment for pancreatitis is entirely supportive and involves fluid support, GI support - anti-nausea (ondansetron, cerenia 2mg/kg PO SID), appetite stimulation (mirtazapine, elura), analgesia (buprenorphine, gabapentin) and enteral nutrition as needed (syringe feeding, NG tube placement, etc). Given evidence of concurrent cholangiohepatitis, antibiotic coverage is warranted. Amoxicillin, Amoxicillin with clavulanic acid, cephalosporins, and fluoroquinolones are suggested first choices. Intravenous antibiotics are preferred to ensure absorption and decrease GI side effects of oral antibiotics which can lower appetite compromising treatment and recovery. Anti-inflammatory steroids may be tried in an attempt to reduce inflammation if traditional supportive care is inadequate. Serial imaging is indicated to monitor response to treatment.

Hepatic changes may reflect a concurrent hepatic lipidosis among other things. Liver FNA is indicated to further defined.



**PATIENT**

Nebu Velazquez

**SPECIES**

Feline

**BREED**

Domestic Shorthair

**SEX**

Neutered Male

**AGE**

8 Years 9 Months

**WEIGHT**

9.8 lbs

**INTERPRETED BY**

Dr Brittany Sinclair,  
BVSc(hons),  
DACVECC

**IMAGING  
PERFORMED BY**

Gabriel Ferrer, DVM

**HOSPITAL NAME**

Pulse: Pet Ultrasound

**REFERRING VET**

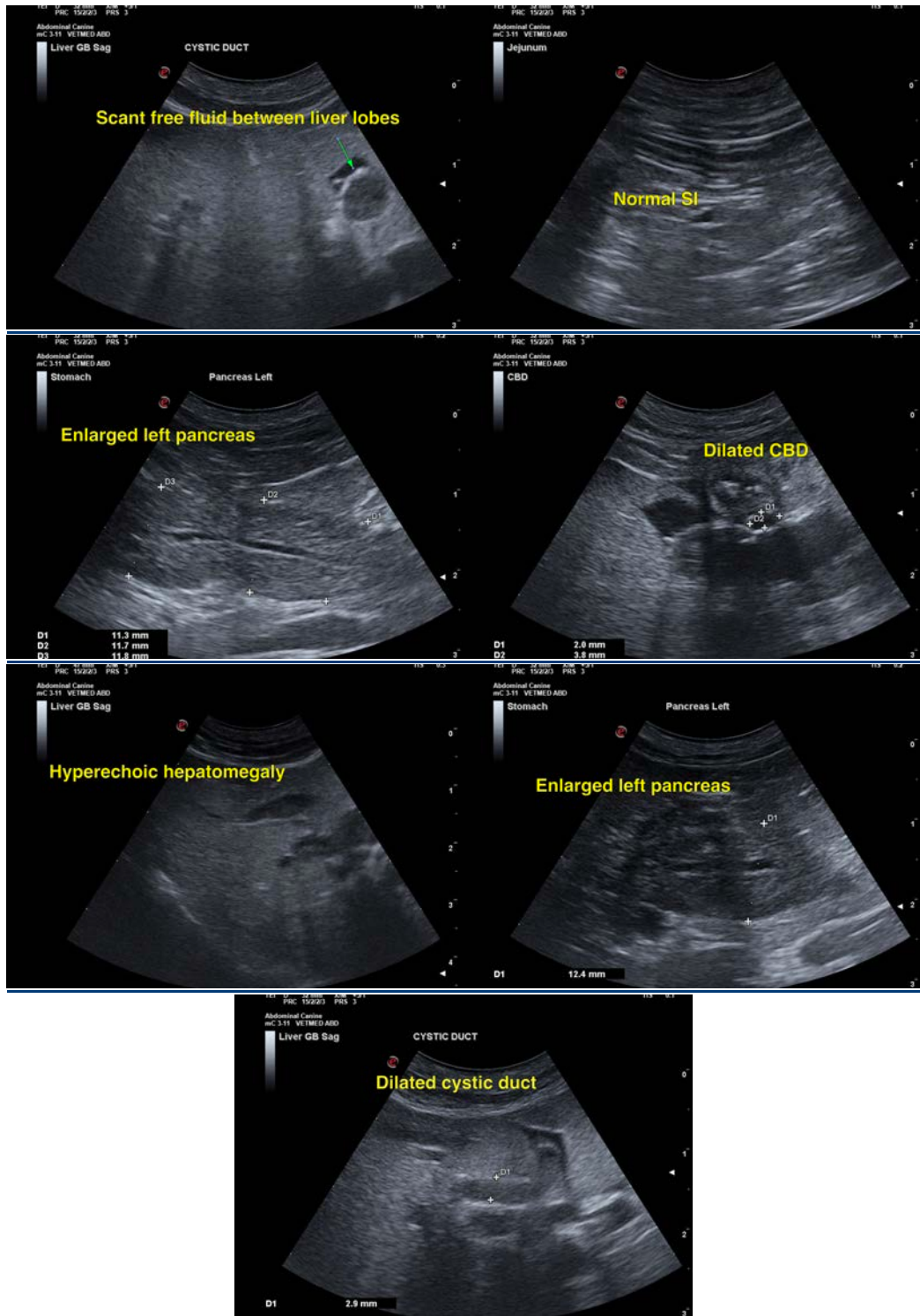
Dr. Alma Alicea

**INVOICE**

75329

**DATE**

5/21/26





## PATIENT

Nebu Velazquez

## SPECIES

Feline

## BREED

Domestic Shorthair

## SEX

Neutered Male

## AGE

8 Years 9 Months

## WEIGHT

9.8 lbs

## INTERPRETED BY

Dr Brittany Sinclair,  
BVSc(hons),  
DACVECC

## IMAGING PERFORMED BY

Gabriel Ferrer, DVM

## HOSPITAL NAME

Pulse: Pet Ultrasound

## REFERRING VET

Dr. Alma Alicea

## INVOICE

75329

## DATE

5/21/26

The information and recommendations provided are based on the images presented by the referring veterinarian/sonographer. No evaluation can be communicated regarding pathology that was not visible in the image/video clips provided.

Thank you for this referral. If the clinical or image interpretation does not parallel your findings or if I can be of any further assistance please contact me.

Dr Brittany Sinclair, BVSc(hons), DACVECC

info@SonoPath.com