



PATIENT

Meeshoo Kamawi

SPECIES

Feline

BREED

DSH

SEX

Intact Male

AGE

8 Months

WEIGHT

3.91 kg

INTERPRETED BY

Dr Brittany Sinclair,
 BVSc(hons),
 DACVECC

IMAGING PERFORMED BY

Kelly Reschny

HOSPITAL NAME

East Credit Veterinary
 Hospital

REFERRING VET

Dr. Webster

INVOICE

75243

DATE

5/19/26

PRESENTING CLINICAL SIGNS

Only one testicle is palpable within the scrotum (right testicle). Cryptorchid - planning to book neuter.

ULTRASONOGRAPHIC EXAMINATION OF THE ABDOMEN

Urinary System

The urinary bladder, trigone, and visible pelvic urethra were of normal thickness. The ureters were not visible which is normal. There was normal wall layering with no masses, uroliths or abnormal thickening visualized. Urine was anechoic. No evidence of inflammatory or neoplastic changes were noted.

The kidneys were both normal size and structure, with smooth capsule and normal corticomedullary definition and ratio. Medullary structure differed distinctly from that of the cortex. No evidence of pelvic dilation was present. Left kidney measures 3.72 cm. Right kidney measures 4.0 cm.

Adrenal Glands

The left adrenal gland is visualized on still images only. It appears to have normal shape, size, position and echogenicity for this breed and age though this could not be confirmed on cine loops. Left measures 0.34 cm in thickness.

The right adrenal gland is visualized and measured on still images only. Resolution is inadequate to assess glandular detail or confirm measurement. Right measures 0.47 cm in thickness.

Spleen

The spleen was normal with age appropriate homogeneous parenchyma and a smooth capsule with normal splenic vasculature with no signs of congestion or thrombosis. No sonographic evidence of acute or chronic inflammatory, neoplastic, or infarct changes were noted.

Liver

The liver is subjectively normal in size with normal contours and structure. There is age appropriate echogenicity and echotexture. No overt structural evidence of inflammatory, infiltrative or regenerative pathology is evident. Vascular and biliary tracts are of normal volume with no evidence of congestion.

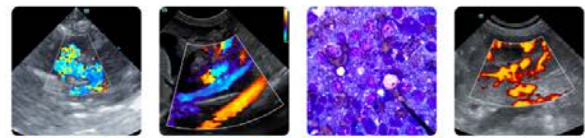
Gall bladder is moderately distended with normal wall thickness and anechoic contents. Common bile duct is non-distended and tapers normally.

Gastrointestinal

The stomach contains minimal luminal contents. It measures at a normal thickness of with some variability due to the presence of rugal folds. The distinction of the gastric wall layers is adequate. No masses or focal lesions were observed.

The visualized areas of duodenum, jejunum and ileum have a relatively uniform diameter with minimal fluid distension. Wall thickness is normal. Bowel loops follow a curvilinear path with distinct wall layering maintaining the typical 1:3 muscularis:mucosa layer ratio. There were no focal lesions consistent with obstruction or a mass effect observed.

Sections of colon are visualized with formed fecal material and gas shadowing distally. There is no observed focal or generalized colon wall thickening or loss of layering.



PATIENT

Meeshoo Kamawi

SPECIES

Feline

BREED

DSH

SEX

Intact Male

AGE

8 Months

WEIGHT

3.91 kg

INTERPRETED BY

Dr Brittany Sinclair,
BVSc(hons),
DACVECC

IMAGING PERFORMED BY

Kelly Reschny

HOSPITAL NAME

East Credit Veterinary
Hospital

REFERRING VET

Dr. Webster

INVOICE

75243

DATE

5/19/26

Pancreas

The area of the pancreas was isoechoic to surrounding tissue with no overt inflammation. Pancreatic tissue was not distinctly visualized which is common.

Free Abdomen

A hypoechoic, ovoid structure consistent with a retained testicle is visible approximately 1/3 of the way between the bladder and kidney (closer to the bladder) along the body wall.

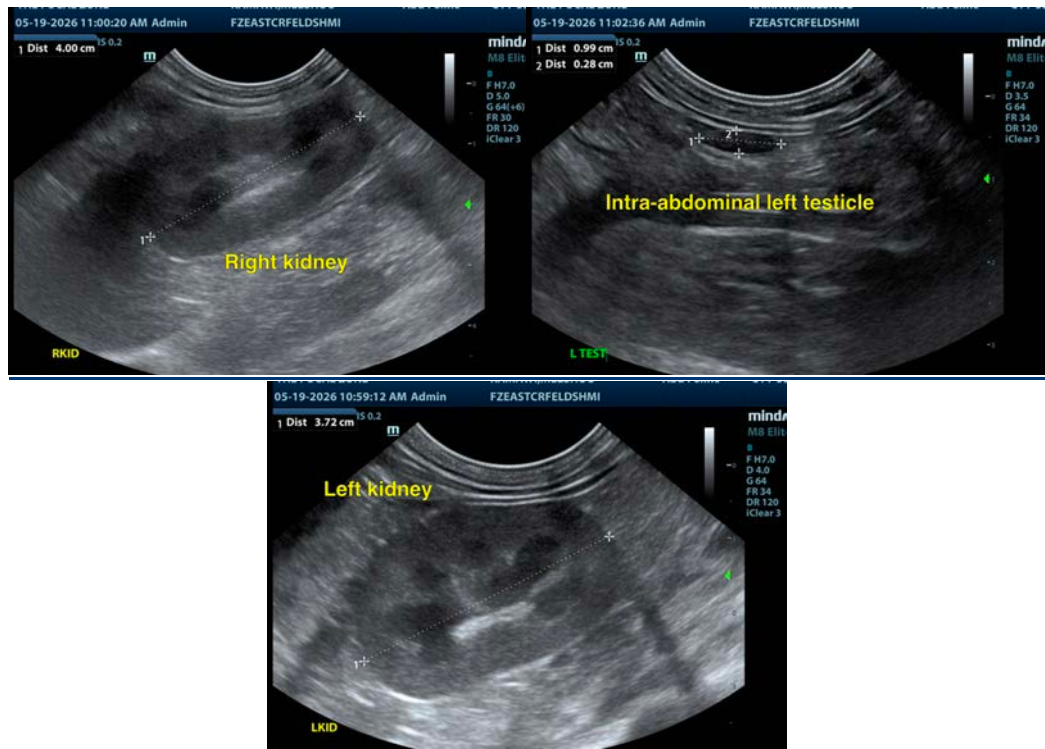
No clinically significant lymphadenopathy or abnormalities noted. No free fluid noted.

ULTRASONOGRAPHIC FINDINGS

- Retained left testicle, intraabdominal

INTERPRETATION OF THE FINDINGS & FURTHER RECOMMENDATIONS

The retained testicle appears to be intraabdominal approximately 1/3 of the way between the urinary bladder and left kidney (closer to the urinary bladder).



The information and recommendations provided are based on the images presented by the referring veterinarian/sonographer. No evaluation can be communicated regarding pathology that was not visible in the image/video clips provided.

Thank you for this referral. If the clinical or image interpretation does not parallel your findings or if I can be of any further assistance please contact me.

Dr Brittany Sinclair, BVSc(hons), DACVECC info@SonoPath.com