



PATIENT

Snap Wittig

SPECIES

Canine

BREED

Pit Bull x

SEX

Neutered Male

AGE

11 Years

WEIGHT

60 lbs

INTERPRETED BY

Dr Brittany Sinclair,
BVSc(hons),
DACVECC

IMAGING PERFORMED BY

Sara Hansen

HOSPITAL NAME

Willakenzie Animal
Clinic

REFERRING VET

Dr. Poquette

INVOICE

75102

DATE

5/13/26

PRESENTING CLINICAL SIGNS

Yearly check for neoplasia as he had a neoplastic anal gland removed 2 years ago. (At OVRA)
ABNORMAL Labwork Values: labs WNL. Current Medications: gabapentin and trazodone PRN vet visits

ULTRASONOGRAPHIC EXAMINATION OF THE ABDOMEN

Urinary System

The urinary bladder, trigone, and visible pelvic urethra were of normal thickness. The ureters were not visible which is normal. There was normal wall layering with no masses, uroliths or abnormal thickening visualized. Urine was anechoic. No evidence of inflammatory or neoplastic changes were noted.

The prostate is not visible.

The kidneys were both normal size and structure, with smooth capsule and normal corticomedullary definition and ratio. Medullary structure differed distinctly from that of the cortex. No evidence of pelvic dilation was present. Left kidney measured 7.04 cm. Right kidney measured 7.19 cm.

Adrenal Glands

Both adrenal glands were visualized and recognized as having normal shape, size, position and echogenicity for this breed and age. The visible phrenic vasculature was unremarkable. Left measures 3.14 cm in length x 0.62 cm at the caudal pole and 0.72 cm at the cranial pole. Right measures 2.81 cm in length x 0.85 cm at the caudal pole and 0.84 cm at the cranial pole.

Spleen

The spleen was subjectively normal in size with a diffusely mildly mottled parenchyma and a smooth capsule. No specific masses or nodules were seen.

Liver

The liver is subjectively normal in size with normal contours and structure. There is age appropriate echogenicity and echotexture. No overt structural evidence of inflammatory, infiltrative or regenerative pathology is evident. Vascular and biliary tracts are of normal volume with no evidence of congestion.

Gall bladder is moderately distended with normal wall thickness and anechoic contents. Common bile duct is non-distended and tapers normally.

Gastrointestinal

The stomach contains minimal luminal contents. It measures at a normal thickness of with some variability due to the presence of rugal folds. The distinction of the gastric wall layers is adequate. No masses or focal lesions were observed.

The visualized areas of duodenum, jejunum and ileum have a relatively uniform diameter with minimal fluid distension. Wall thickness is normal. Bowel loops follow a curvilinear path with distinct wall layering maintaining the typical 1:3 muscularis:mucosa layer ratio. There were no focal lesions consistent with obstruction or a mass effect observed.

Sections of colon are visualized with formed fecal material and gas shadowing distally. There is no observed focal or generalized colon wall thickening or loss of layering.



PATIENT

Snap Wittig

SPECIES

Canine

BREED

Pit Bull x

SEX

Neutered Male

AGE

11 Years

WEIGHT

60 lbs

INTERPRETED BY

Dr Brittany Sinclair,
 BVSc(hons),
 DACVECC

IMAGING PERFORMED BY

Sara Hansen

HOSPITAL NAME

Willakenzie Animal
 Clinic

REFERRING VET

Dr. Poquette

INVOICE

75102

DATE

5/13/26

Pancreas

The visible pancreas was observed to be largely isoechoic to surrounding omental fat.

Free Abdomen

No clinically significant lymphadenopathy or abnormalities noted. No free fluid noted.

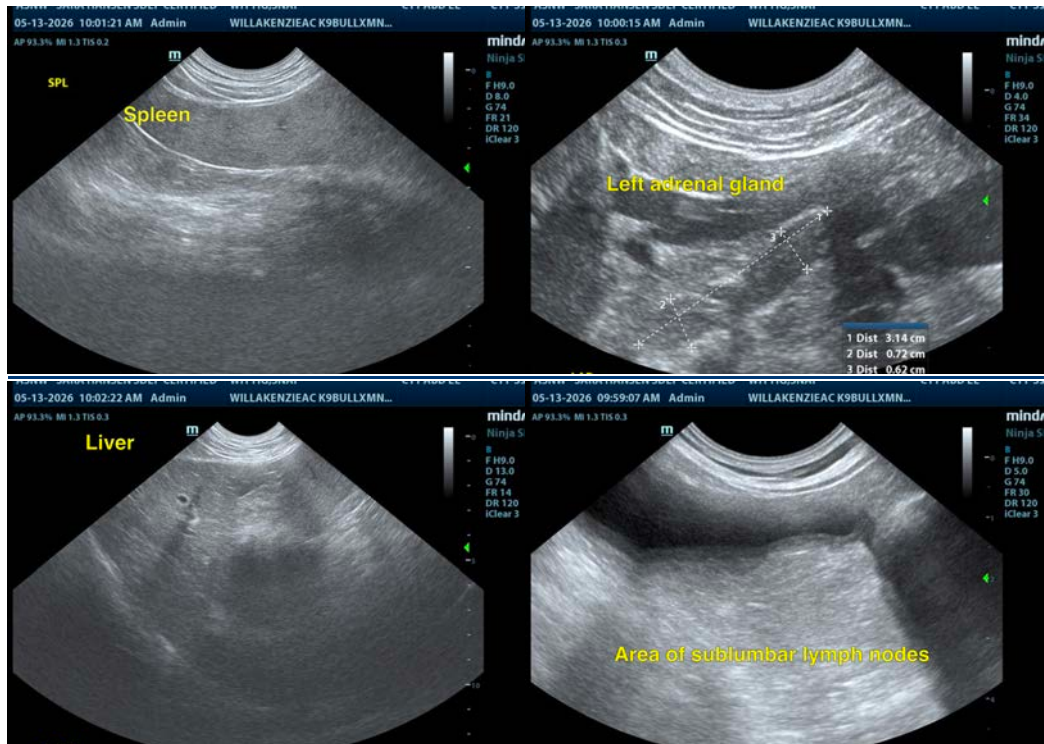
ULTRASONOGRAPHIC FINDINGS

- Slightly mottled spleen.

INTERPRETATION OF THE FINDINGS & FURTHER RECOMMENDATIONS

There were no changes in the sublumbar area suggestive of recurrent anal gland neoplasia nor in the remainder of the abdomen.

Splenic changes were very mild and are a common benign age related change. Together with likely mild passive congestion from sedation this is considered the most likely cause. Infiltrative disease (lymphoma, MCT, other) cannot be definitively ruled out. No significant disruption of architecture noted to suggest significant pathology. Fine needle aspirate could be considered to further characterize parenchymal changes if clinically indicated, especially if any weight loss is noted or for baseline cytological assessment.





PATIENT

Snap Wittig

SPECIES

Canine

BREED

Pit Bull x

SEX

Neutered Male

AGE

11 Years

WEIGHT

60 lbs

INTERPRETED BY

Dr Brittany Sinclair,
BVSc(hons),
DACVECC

IMAGING PERFORMED BY

Sara Hansen

HOSPITAL NAME

Willakenzie Animal
Clinic

REFERRING VET

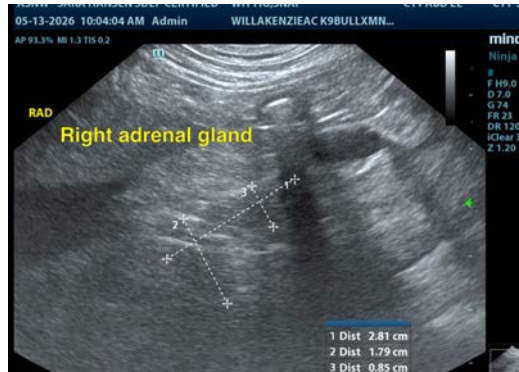Dr. Poquette

INVOICE

75102

DATE

5/13/26



The information and recommendations provided are based on the images presented by the referring veterinarian/sonographer. No evaluation can be communicated regarding pathology that was not visible in the image/video clips provided.

Thank you for this referral. If the clinical or image interpretation does not parallel your findings or if I can be of any further assistance please contact me.

Dr Brittany Sinclair, BVSc(hons), DACVECC

info@SonoPath.com