



**PATIENT**

Maisie Neamtu

**SPECIES**

Canine

**BREED**

Mini Schnauzer

**SEX**

Spayed Female

**AGE**

10 Years

**WEIGHT**

18.3 lbs

**INTERPRETED BY**

Dr Brittany Sinclair,  
BVSc(hons),  
DACVECC

**IMAGING PERFORMED BY**

Amanda Stewart

**HOSPITAL NAME**

Dover Animal Hospital

**REFERRING VET**

Dr. Foster

**INVOICE**

74290

**DATE**

4/8/26

**PRESENTING CLINICAL SIGNS**

Presented with pu/pd and recently had a seizure. Has had ultrasounds in the past. History of pancreatitis and mild vacuolar hepatopathy.

Current Medications: Aventi Liver Complete, Apoquel 3.6 mg

Abnormal PE/Chem/CBC/UA Results: Cortisol/ Creatinine 119 ALKP 1909, AMYL 1524 Primary Question to Be Answered in This Exam Rule out Cushings (rec low dose dexamethasone suppression test but owner wants to start with u/s)

**ULTRASONOGRAPHIC EXAMINATION OF THE ABDOMEN**

**Urinary System**

The urinary bladder, trigone, and visible pelvic urethra were diffusely thickened with slightly irregular mucosa but maintenance of wall layering. The ureters were not visible which is normal. There are no masses or uroliths visualized. Mobile debris present in the urinary bladder. No evidence of inflammatory or neoplastic changes were noted.

The left kidney has a smooth capsule and with hazing of corticomedullary definition to the point of inability to determine cortical/medullary ratio. The left renal pelvis is very mildly dilated. Hyperechoic, shadowing foci present in renal parenchyma and calyces consistent with nephrocalcinosis. Left kidney measures 5.17 cm. Ureter is non-dilated.

The right kidney has a smooth capsule and with hazing of corticomedullary definition to the point of inability to determine cortical/medullary ratio. No pelvic dilation present. Hyperechoic, shadowing foci present in renal parenchyma and calyces consistent with nephrocalcinosis. Ureter is non-dilated. Right kidney measures 5.06 cm. Complete visualization of the right kidney is limited by intercostal location causing overlying rib shadowing.

**Adrenal Glands**

Both adrenal glands were visualized and recognized as having normal shape, size, position and echogenicity for this breed and age. The visible phrenic vasculature was unremarkable. Left measures 1.77 cm in length x 0.52 cm at the caudal pole and 0.58 cm at the cranial pole. Right measures 2.11 cm in length x 0.44 cm at the caudal pole and 1.03 cm at the cranial pole.

**Spleen**

The spleen was normal with age appropriate homogeneous parenchyma and a smooth capsule with normal splenic vasculature with no signs of congestion or thrombosis. No sonographic evidence of acute or chronic inflammatory, neoplastic, or infarct changes were noted.

**Liver**

The liver is diffusely enlarged and hyperechoic (isoechoic to the spleen). In the central liver there is a roughly spherical, somewhat poorly defined small nodule/mass measuring approximately 1.88 cm x 1.97 cm abutting the diaphragmatic surface.

The gall bladder is moderately distended with anechoic fluid, with hyperechoic non-shadowing debris present. There is no surrounding free fluid or signs of active inflammation.



**PATIENT**

Maisie Neamtu

**SPECIES**

Canine

**BREED**

Mini Schnauzer

**SEX**

Spayed Female

**AGE**

10 Years

**WEIGHT**

18.3 lbs

**INTERPRETED BY**

Dr Brittany Sinclair,  
 BVSc(hons),  
 DACVECC

**IMAGING PERFORMED BY**

Amanda Stewart

**HOSPITAL NAME**

Dover Animal Hospital

**REFERRING VET**

Dr. Foster

**INVOICE**

74290

**DATE**

4/8/26

***Gastrointestinal***

The stomach contains minimal luminal contents. It measures at a normal thickness of with some variability due to the presence of rugal folds. The distinction of the gastric wall layers is adequate. No masses or focal lesions were observed.

The visualized areas of duodenum, jejunum and ileum have a relatively uniform diameter with minimal fluid distension. Wall thickness is normal. Bowel loops follow a curvilinear path with distinct wall layering maintaining the typical 1:3 muscularis:mucosa layer ratio. There were no focal lesions consistent with obstruction or a mass effect observed.

Sections of colon are visualized with gas shadowing distally. There is no observed focal or generalized colon wall thickening or loss of layering.

***Pancreas***

The area of the pancreas was isoechoic to surrounding tissue with no overt inflammation. Pancreatic tissue was not distinctly visualized which is common.

***Free Abdomen***

No clinically significant lymphadenopathy or abnormalities noted. No free fluid noted.

**ULTRASONOGRAPHIC FINDINGS**

- Mildly thickened, irregular urinary bladder wall with urinary bladder debris – consistent with cystitis.
- Degenerative renal changes with nephrocalcinosis and mild left pyelectasia – consistent with reported PU/PD.
- Hyperechoic hepatomegaly.
- Focal liver nodule/mass.
- Gallbladder debris.

**INTERPRETATION OF THE FINDINGS & FURTHER RECOMMENDATIONS**

The most common causes of pu/pd in dogs include renal disease, diabetes mellitus and hyperadrenocorticism. Early renal insufficiency is a possible cause but is considered unlikely given normal renal values. Urine culture is recommended to screen for UTI, especially given signs of urinary bladder cystitis. Adrenal gland function testing is recommended despite normal appearance of adrenal glands, given elevated cortisol to creatinine ratio and elevation in ALP, as hyperadrenocorticism cannot be ruled out based on normal appearing adrenal glands and is a common cause of significant pu/pd. The focal nodule/mass in the liver is of uncertain clinical significance. Unfortunately, it is not in a location that is likely amenable to percutaneous FNA, and further differentiation of the cause of this focal abnormality will likely require surgical liver biopsy. While the patient has been previously diagnosed with vacuolar hepatopathy, this lesion does not have the typical appearance of nodules seen with vacuolar hepatopathy. If surgical explore and liver biopsy is not desired at this time, serial monitoring with ultrasound in 1, 3, and 6 months is recommended to monitor for progression or regression of this lesion. This is a possible contributor to PU/PD.



**PATIENT**

Maisie Neamtu

**SPECIES**

Canine

**BREED**

Mini Schnauzer

**SEX**

Spayed Female

**AGE**

10 Years

**WEIGHT**

18.3 lbs

**INTERPRETED BY**

Dr Brittany Sinclair,  
 BVSc(hons),  
 DACVECC

**IMAGING PERFORMED BY**

Amanda Stewart

**HOSPITAL NAME**

Dover Animal Hospital

**REFERRING VET**

Dr. Foster

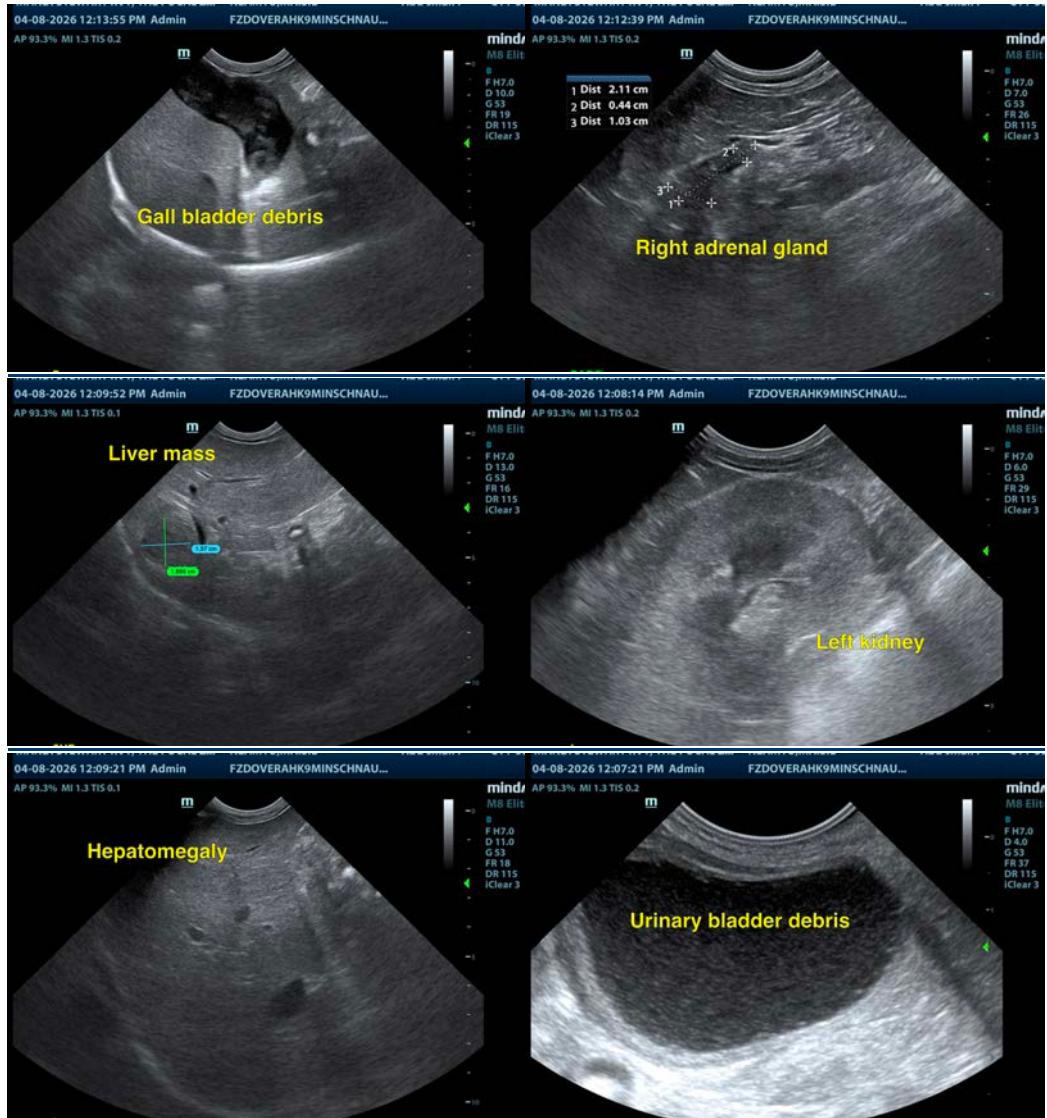
**INVOICE**

74290

**DATE**

4/8/26

Rarer causes of pu/pd should also be considered such as hyperthyroidism, hypercalcemia, diabetes insipidus (central or nephrogenic). Additional tests to be considered include ionized calcium measurement (even if total is normal), thyroid testing, bile acid profile, leptospirosis testing, and ultimately a desmopressin trial to investigate for central diabetes insipidus if other causes have been ruled out. Ultimately MRI may be required to screen for primary neurologic causes. Psychogenic polydipsia is an idiopathic cause of pu/pd and is a diagnosis of exclusion.





**PATIENT**

Maisie Neamtu

**SPECIES**

Canine

**BREED**

Mini Schnauzer

**SEX**

Spayed Female

**AGE**

10 Years

**WEIGHT**

18.3 lbs

**INTERPRETED BY**

Dr Brittany Sinclair,  
 BVSc(hons),  
 DACVECC

**IMAGING PERFORMED BY**

Amanda Stewart

**HOSPITAL NAME**

Dover Animal Hospital

**REFERRING VET**

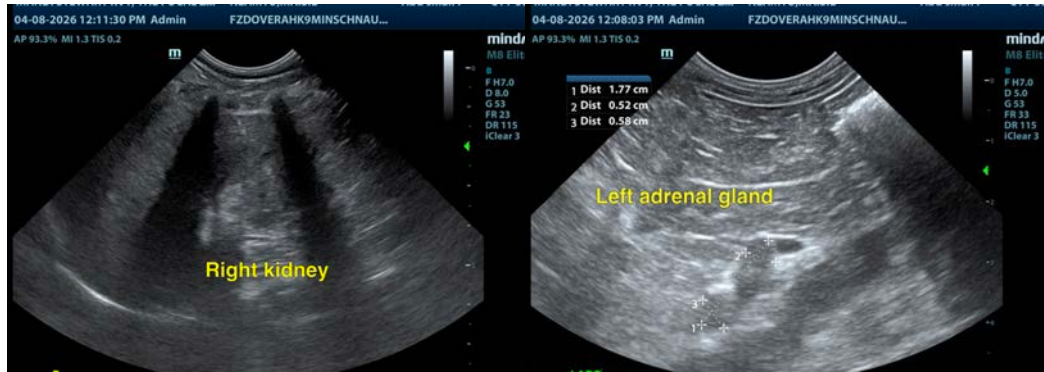
Dr. Foster

**INVOICE**

74290

**DATE**

4/8/26



The information and recommendations provided are based on the images presented by the referring veterinarian/sonographer. No evaluation can be communicated regarding pathology that was not visible in the image/video clips provided.

Thank you for this referral. If the clinical or image interpretation does not parallel your findings or if I can be of any further assistance please contact me.

Dr Brittany Sinclair, BVSc(hons), DACVECC

info@SonoPath.com