



PATIENT

Bailey Diviney

SPECIES

Canine

BREED

Goldendoodle

SEX

Neutered Male

AGE

10 Years

WEIGHT

Not Provided

INTERPRETED BY

Dr Brittany Sinclair,
BVSc(hons), DACVECC

IMAGING PERFORMED BY

Shari Reffi CVT

HOSPITAL NAME

Black River VH

REFERRING VET

Dr. Tack

INVOICE

14836

DATE

04/03/26

PRESENTING CLINICAL SIGNS

- AUS to R/O liver mass vs Cushing's vs Adrenal mass

ULTRASONOGRAPHIC EXAMINATION OF THE ABDOMEN

Urinary System

The urinary bladder, trigone, and visible pelvic urethra were of normal thickness. The ureters were not visible which is normal. There was normal wall layering with no masses, uroliths or abnormal thickening visualized. Urine was anechoic. No evidence of inflammatory or neoplastic changes were noted.

The prostate was not visualized in this study likely due to intrapelvic location.

The kidneys have a smooth capsule and with mild hazing of corticomedullary definition. Hyperechoic, shadowing foci present in renal parenchyma and calyces consistent with nephrocalcinosis. The left kidney measured 7.29 cm in length. The right kidney measured 6.77 cm in length.

Adrenal Glands

Both adrenal glands were visualized and recognized as having normal shape, size, position and echogenicity for this breed and age. The visible phrenic vasculature was unremarkable. The left adrenal gland measured 2.62 cm in length and 0.67 cm at the caudal pole and 0.73 cm at the cranial pole. The right adrenal gland measured 3.38 cm in length and 0.64 cm at the caudal pole and 0.71 cm at the cranial pole.

Spleen

The spleen was normal with age-appropriate homogeneous parenchyma and a smooth capsule with normal splenic vasculature with no signs of congestion or thrombosis. No sonographic evidence of acute or chronic inflammatory, neoplastic, or infarct changes were noted.

Liver

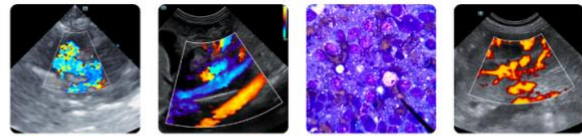
The liver is diffusely abnormal. It is enlarged with nodular/irregular margins. Parenchyma is diffusely abnormal. There are multifocal variably sized heterogeneous nodules noted throughout the parenchyma, some of which have a hyperechoic center consistent with target lesions. The largest measurable liver nodule is noted in the right liver lobe and is irregular, measuring 2.3 cm by 3.4 cm.

Gall bladder is moderately distended with normal wall thickness and anechoic contents. Common bile duct is non-distended and tapers normally.

Gastrointestinal

The stomach contains minimal luminal contents. It measures at a normal thickness of with some variability due to the presence of rugal folds. The distinction of the gastric wall layers is adequate. No masses or focal lesions were observed.

The visualized areas of duodenum, jejunum and ileum have a relatively uniform diameter with gas throughout with no overt distention. Wall thickness is normal. Bowel loops follow a curvilinear path with distinct wall layering maintaining the typical 1:3 muscularis: mucosa layer ratio. There were no focal lesions consistent with obstruction or a mass effect observed.



PATIENT

Bailey Diviney

The ileocecal junction was not visualized. Sections of colon are visualized with formed fecal material and gas shadowing distally. There is no observed focal or generalized colon wall thickening or loss of layering.

SPECIES

Canine

Pancreas

The pancreas was not distinctly visualized.

BREED

Goldendoodle

Lymph Nodes

No clinically significant lymphadenopathy or abnormalities noted.

SEX

Neutered Male

Free Abdomen

No masses or free fluid were noted.

AGE

10 Years

ULTRASONOGRAPHIC FINDINGS

- Diffuse nodular hepatic changes with irregular nodules and target lesions.
- Mild aging renal changes.

WEIGHT

Not Provided

INTERPRETATION OF THE FINDINGS & FURTHER RECOMMENDATIONS

Liver changes may represent reactive, regenerative or inflammatory changes, nodular hyperplasia or infiltrative disease (lymphoma, MCT, metastatic neoplasia or other). They are likely at least partially chronic in nature but may represent an acute on chronic hepatopathy. Evaluation of a bile acid profile is recommended to further define the degree of liver dysfunction. Liver FNA is recommended to further characterize parenchymal changes. Ultimately liver biopsy is likely required for more definitive diagnosis. Thoracic radiographs are recommended to screen for pulmonary disease.

INTERPRETED BY

Dr Brittany Sinclair,
BVSc(hons), DACVECC

IMAGING PERFORMED BY

Shari Reffi CVT

HOSPITAL NAME

Black River VH

REFERRING VET

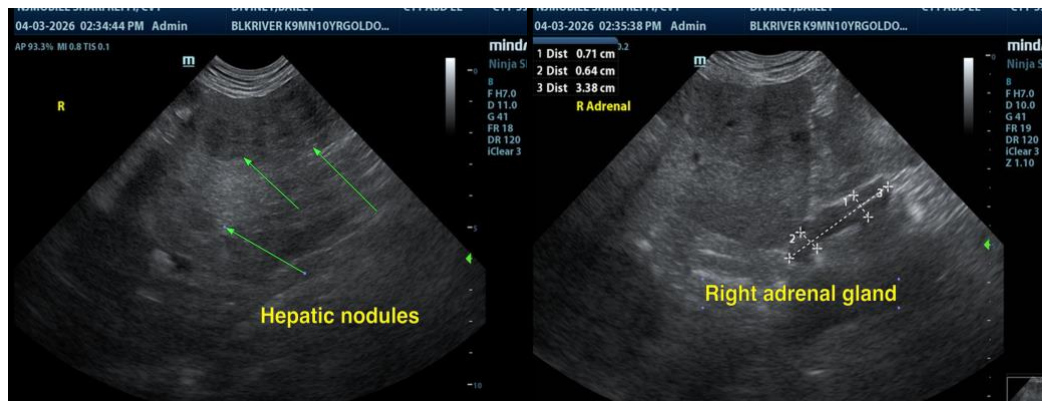
Dr. Tack

INVOICE

14836

DATE

04/03/26





PATIENT

Bailey Diviney

SPECIES

Canine

BREED

Goldendoodle

SEX

Neutered Male

AGE

10 Years

WEIGHT

Not Provided

INTERPRETED BY

Dr Brittany Sinclair,
 BVSc(hons), DACVECC

IMAGING PERFORMED BY

Shari Reffi CVT

HOSPITAL NAME

Black River VH

REFERRING VET

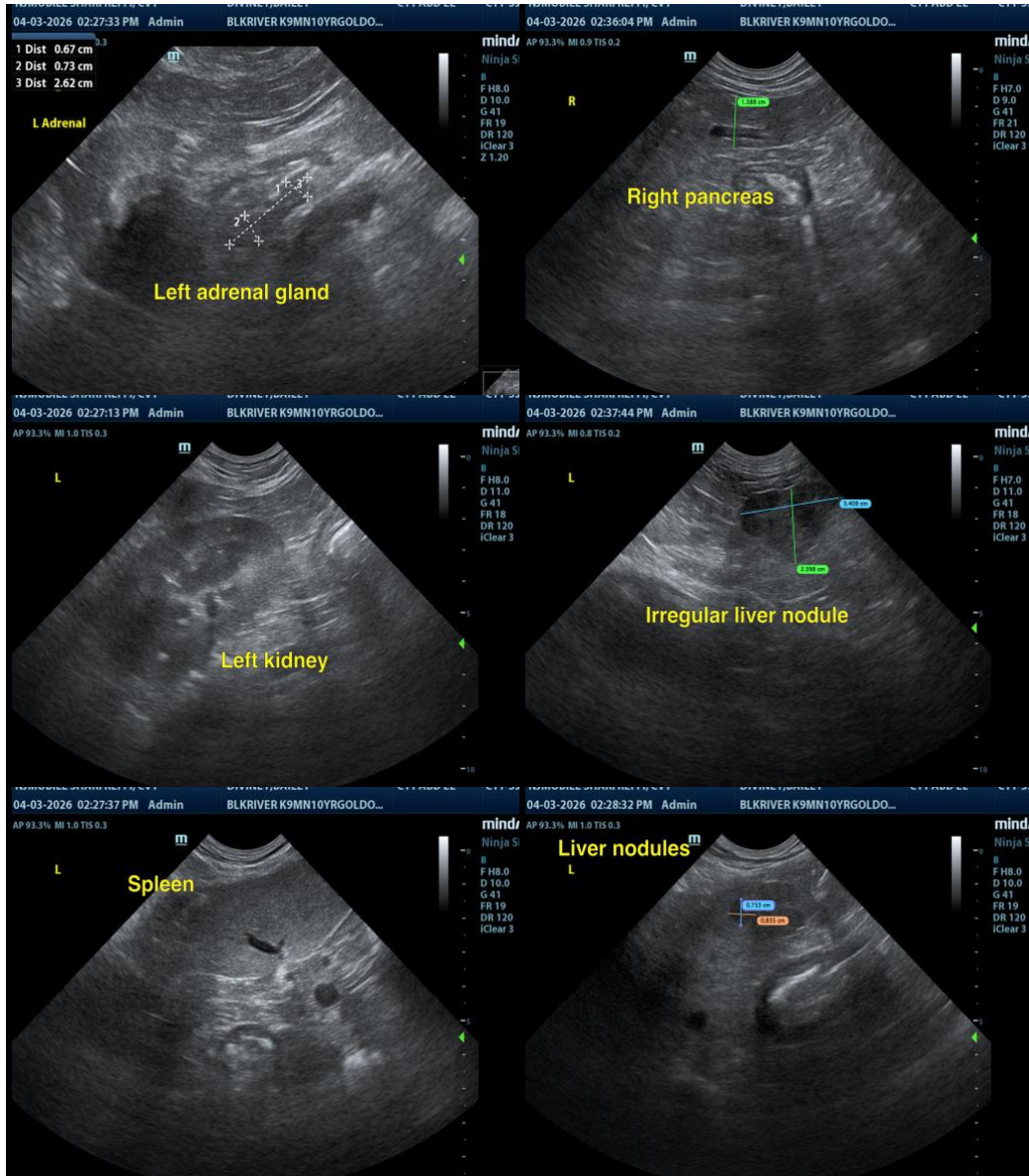
Dr. Tack

INVOICE

14836

DATE

04/03/26





PATIENT

Bailey Diviney

SPECIES

Canine

BREED

Goldendoodle

SEX

Neutered Male

AGE

10 Years

WEIGHT

Not Provided

INTERPRETED BY

Dr Brittany Sinclair,
 BVSc(hons), DACVECC

IMAGING PERFORMED BY

Shari Reffi CVT

HOSPITAL NAME

Black River VH

REFERRING VET

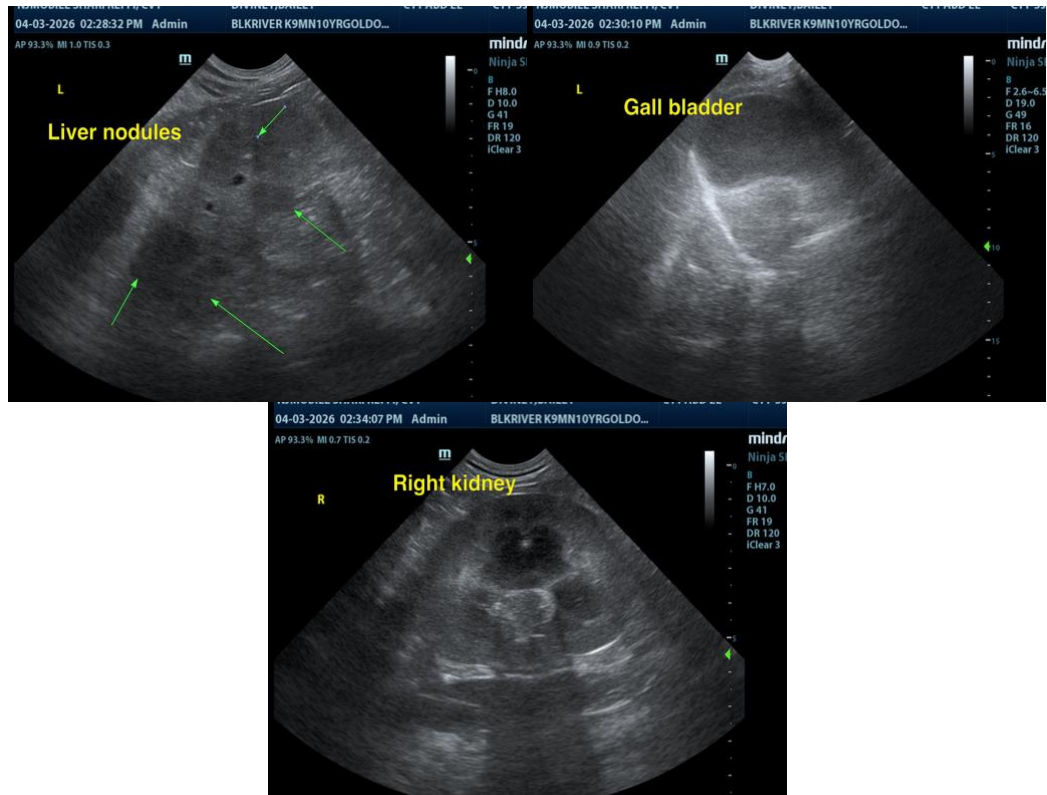
Dr. Tack

INVOICE

14836

DATE

04/03/26



The information and recommendations provided are based on the images presented by the referring veterinarian/sonographer. No evaluation can be communicated regarding pathology that was not visible in the image/video clips provided.

Thank you for this referral. If the clinical or image interpretation does not parallel your findings or if I can be of any further assistance, please contact me.

Dr Brittany Sinclair, BVSc(hons), DACVECC

info@SonoPath.com