



**PATIENT**

Walter Thomas

**SPECIES**

Canine

**BREED**

Schnauzer x

**SEX**

Neutered Male

**AGE**

10 Years

**WEIGHT**

14.5 lbs

**INTERPRETED BY**

Dr Brittany Sinclair,  
BVSc(hons),  
DACVECC

**IMAGING PERFORMED BY**

Sara Hansen

**HOSPITAL NAME**

Orchard Animal  
Hospital

**REFERRING VET**

Dr. Nelson

**INVOICE**

74798

**DATE**

4/29/26

**PRESENTING CLINICAL SIGNS**

Owner interested in laxative to help defecate. P is able to defecate but stool is soft rectal exam: Moderately enlarged prostate, not painful, rectum is empty of stool, straining may possibly be due to enteritis or enlarged prostate. As long as p is passing stool, please do not give laxative d/t possible enteritis. Enlarged prostate on neutered dog is a concern. rec abd u/s to r/o neoplasia, benign prostatomegaly, prostatitis, unable to appreciate prostate on radiograph; however there appears to be a mass effect in the cranial dorsal and ventral abd seen on lateral; spleen vs liver? pending labwork, still rec abd u/s.

**ABNORMAL Labwork Values:** labwork shows elevated liver enzymes ALT 199 and ALKP 216. hepatopathy may or may not be incidental to straining to defecate. rec abd u/s to evaluate liver as well as prostate

**ULTRASONOGRAPHIC EXAMINATION OF THE ABDOMEN**

**Urinary System**

The urinary bladder, trigone, and visible pelvic urethra were of normal thickness. The ureters were not visible which is normal. There was normal wall layering with no masses, uroliths or abnormal thickening visualized. Urine was anechoic. No evidence of inflammatory or neoplastic changes were noted.

The prostate is enlarged, rounded and hypoechoic with multifocal hyperechoic areas consistent with mineralization in the prostate. The prostate measures approximately 2.3 cm x 2.3 cm.

The kidneys have a smooth capsule and with mild hazing of corticomedullary definition. No evidence of pelvic dilation was present. Hyperechoic, shadowing foci present in renal parenchyma and calyces consistent with nephrocalcinosis. Left kidney measures 4.69 cm. Right kidney measures 4.55 cm.

**Adrenal Glands**

Both adrenal glands were visualized and recognized as having normal shape, size, position and echogenicity for this breed and age. The visible phrenic vasculature was unremarkable. Left measures 1.91 cm in length x 0.53 cm at the cranial pole and 0.66 cm at the caudal pole. Right measures 1.89 cm in length x 0.87 cm at the cranial pole and 0.54 cm at the caudal pole.

**Spleen**

The spleen is generally normal in size, shape and position. There are few hyperechoic areas consistent with benign splenic myelolipomas.

**Liver**

The liver is diffusely enlarged with a slightly coarse parenchyma and rounded margins. There are no specific masses visualized.

Gall bladder is moderately distended with normal wall thickness and anechoic contents. Common bile duct is non-distended and tapers normally.



**PATIENT**

Walter Thomas

**SPECIES**

Canine

**BREED**

Schnauzer x

**SEX**

Neutered Male

**AGE**

10 Years

**WEIGHT**

14.5 lbs

**INTERPRETED BY**

Dr Brittany Sinclair,  
 BVSc(hons),  
 DACVECC

**IMAGING PERFORMED BY**

Sara Hansen

**HOSPITAL NAME**

Orchard Animal  
 Hospital

**REFERRING VET**

Dr. Nelson

**INVOICE**

74798

**DATE**

4/29/26

***Gastrointestinal***

The stomach contains minimal luminal contents. It measures at a normal thickness of with some variability due to the presence of rugal folds. The distinction of the gastric wall layers is adequate. No masses or focal lesions were observed.

The visualized areas of duodenum, jejunum and ileum have a relatively uniform diameter with minimal fluid distension. Wall thickness is normal. Bowel loops follow a curvilinear path with distinct wall layering maintaining the typical 1:3 muscularis:mucosa layer ratio. There were no focal lesions consistent with obstruction or a mass effect observed.

Sections of colon are visualized with formed fecal material and gas shadowing distally. There is no observed focal or generalized colon wall thickening or loss of layering.

***Pancreas***

The visible pancreas was observed to be largely isoechoic to surrounding omental fat.

***Free Abdomen***

No clinically significant lymphadenopathy or abnormalities noted. No free fluid noted.

**ULTRASONOGRAPHIC FINDINGS**

- Prostatomegaly with mineralization.
- Mild aging renal changes.
- Hepatomegaly with slightly coarse echotexture.
- Splenic myelolipomas.

**INTERPRETATION OF THE FINDINGS & FURTHER RECOMMENDATIONS**

Most significant finding is prostatitis which is most concerning for prostatic carcinoma, but could be bacterial in origin. Prostatic aspirate for cytology and culture is recommended to assess for neoplasia and infection. Urine culture and/or prostatic wash with cytology and culture could be considered. CADET BRAF testing can pick up prostatic neoplasia if transitional cell in origin. Empiric therapy with antibiotics with good prostatic penetration (enrofloxacin, TMS, clindamycin, etc) for a minimum of 4 weeks and recheck imaging to monitor for resolution could also be considered.

Liver changes are a common benign age related change, but infiltrative disease (lymphoma, MCT, other) cannot be definitively ruled out. No significant disruption of architecture noted to suggest significant pathology. In the face of elevated liver enzymes, fine needle aspirate is recommended to further characterize parenchymal changes, and bile acid profile to assess liver function, especially if any weight loss is noted or for baseline cytological assessment. Ultimately liver biopsy is often required for more definitive diagnosis. Empiric treatments (SAM-E, milk thistle, Vitamin E, ursodiol if bilirubin elevated or gallbladder sludge) could be tried and liver enzymes re-evaluated, especially if liver FNA does not show significant pathology before more invasive liver sampling is pursued.

Splenic changes are a common age related change and hyperechoic areas are most consistent with benign myelolipoma, but infiltrative disease (lymphoma, MCT, other) cannot be definitively ruled out. No significant disruption of architecture noted to suggest significant pathology. Fine needle aspirate could be considered to further characterize parenchymal changes if clinically indicated, especially if any weight loss is noted or for baseline cytological assessment.



**PATIENT**

Walter Thomas

**SPECIES**

Canine

**BREED**

Schnauzer x

**SEX**

Neutered Male

**AGE**

10 Years

**WEIGHT**

14.5 lbs

**INTERPRETED BY**

Dr Brittany Sinclair,  
 BVSc(hons),  
 DACVECC

**IMAGING PERFORMED BY**

Sara Hansen

**HOSPITAL NAME**

Orchard Animal  
 Hospital

**REFERRING VET**

Dr. Nelson

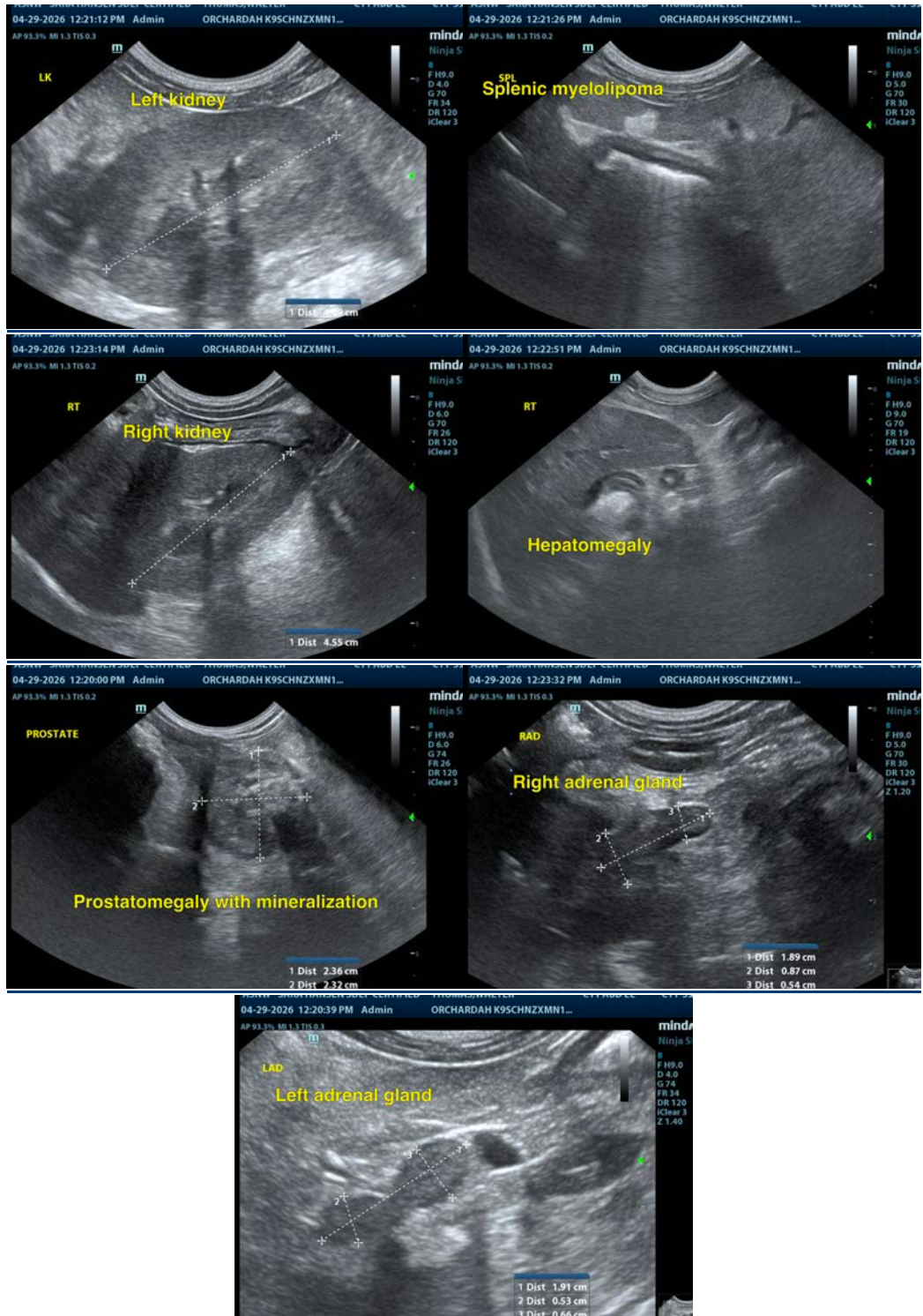
**INVOICE**

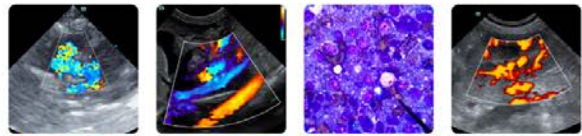
74798

**DATE**

4/29/26

Renal changes are likely age related degeneration. Correlate clinical significance with semi-annual blood work/urinalysis findings and clinical signs.





**PATIENT**

Walter Thomas

**SPECIES**

Canine

**BREED**

Schnauzer x

**SEX**

Neutered Male

**AGE**

10 Years

**WEIGHT**

14.5 lbs

**INTERPRETED BY**

Dr Brittany Sinclair,  
BVSc(hons),  
DACVECC

**IMAGING PERFORMED BY**

Sara Hansen

**HOSPITAL NAME**

Orchard Animal  
Hospital

**REFERRING VET**

Dr. Nelson

**INVOICE**

74798

**DATE**

4/29/26

The information and recommendations provided are based on the images presented by the referring veterinarian/sonographer. No evaluation can be communicated regarding pathology that was not visible in the image/video clips provided.

Thank you for this referral. If the clinical or image interpretation does not parallel your findings or if I can be of any further assistance please contact me.

Dr Brittany Sinclair, BVSc(hons), DACVECC

info@SonoPath.com