



PATIENT

Millie Lindaberry

SPECIES

Canine

BREED

Border Collie x

SEX

Spayed Female

AGE

7.2 Years

WEIGHT

28.6 lbs

INTERPRETED BY

Dr Brittany Sinclair,
BVSc(hons),
DACVECC

IMAGING PERFORMED BY

Dr. Kristen Carpenter

HOSPITAL NAME

Pennridge Animal
Hospital

REFERRING VET

Dr. Beth Mehaffey

INVOICE

74789

DATE

4/29/26

PRESENTING CLINICAL SIGNS

HX: Not sedated. Patient had gabapentin/trazodone pre-medication.

- Presented 4/13/26 for hyporexia. Patient needed to be fully sedated for evaluation. Oral exam WNL. Rads were suggestive of delayed gastric emptying. Bloodwork NSF. Started on probiotics, cerenia, and rx i/d food and had an initial favorable response.

- Patient re-presented today as she had one instance of vomiting over the weekend, had reduced appetite and developed diarrhea. Patient also had a 3 pound weight loss. Here for further workup today including AUS. Hospitalized for the day for GI supportive care (fluids, cerenia, metro, pepcid).

Abnormal PE/Chem/CBC/UA Results: 3/7/26 Full bloodwork: All WNL. Chronically anaplasma + (previously treated). Fecal NOS - 4/14/26 In house b/w + cpl - NSF, CPL 51 (normal) - 4/14/26 Radiographs: NSF except suspect delayed gastric emptying (stomach filled with food despite a 12 hour fast) - 4/28/26: Repeat bloodwork IH - WNL including normal cpl - 4/28/26 Repeat radiographs: Overall NSF

ULTRASONOGRAPHIC EXAMINATION OF THE ABDOMEN

Urinary System

The urinary bladder, trigone, and visible pelvic urethra were of normal thickness. The ureters were not visible which is normal. There was normal wall layering with no masses, uroliths or abnormal thickening visualized. Mobile debris present in the urinary bladder. No evidence of inflammatory or neoplastic changes were noted.

The kidneys were both normal size and structure, with smooth capsule and normal corticomedullary definition and ratio. Medullary structure differed distinctly from that of the cortex. No evidence of pelvic dilation was present. Left kidney measures 5.6 cm. Right kidney measures 4.75 cm.

Adrenal Glands

Both adrenal glands were visualized and recognized as having normal shape, size, position and echogenicity for this breed and age. The visible phrenic vasculature was unremarkable. Left measures 1.91 cm in length x 0.55 cm at the caudal pole and 0.43 cm at the cranial pole. Right measures 1.91 cm in length x 0.65 cm at the caudal pole and 0.85 cm at the cranial pole.

Spleen

The spleen was normal with age appropriate homogeneous parenchyma and a smooth capsule with normal splenic vasculature with no signs of congestion or thrombosis. No sonographic evidence of acute or chronic inflammatory, neoplastic, or infarct changes were noted.

Liver

The liver is subjectively normal in size with normal contours and structure. There is age appropriate echogenicity and echotexture. No overt structural evidence of inflammatory, infiltrative or regenerative pathology is evident. Vascular and biliary tracts are of normal volume with no evidence of congestion.

Gall bladder is moderately distended with normal wall thickness and anechoic contents. Common bile duct is non-distended and tapers normally.



PATIENT

Millie Lindaberry

SPECIES

Canine

BREED

Border Collie x

SEX

Spayed Female

AGE

7.2 Years

WEIGHT

28.6 lbs

INTERPRETED BY

Dr Brittany Sinclair,
BVSc(hons),
DACVECC

IMAGING PERFORMED BY

Dr. Kristen Carpenter

HOSPITAL NAME

Pennridge Animal
Hospital

REFERRING VET

Dr. Beth Mehaffey

INVOICE

74789

DATE

4/29/26

Gastrointestinal

The stomach contains ingesta. It measures at a normal thickness of with some variability due to the presence of rugal folds. The distinction of the gastric wall layers is adequate. No masses or focal lesions were observed.

The visualized areas of duodenum, jejunum and ileum have a relatively uniform diameter with minimal luminal contents with a small amount of ingesta moving through intestines. Wall thickness is normal. Bowel loops follow a curvilinear path with distinct wall layering maintaining the typical 1:3 muscularis:mucosa layer ratio. There were no focal lesions consistent with obstruction or a mass effect observed.

Sections of colon are visualized with formed fecal material and gas shadowing distally. There is no observed focal or generalized colon wall thickening or loss of layering.

Pancreas

The visible pancreas was observed to be largely isoechoic to surrounding omental fat.

Free Abdomen

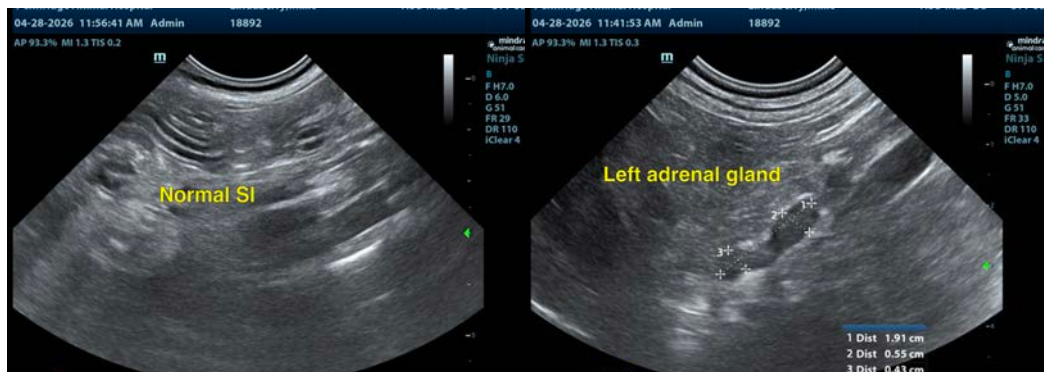No clinically significant lymphadenopathy or abnormalities noted. No free fluid noted.

ULTRASONOGRAPHIC FINDINGS

- Unremarkable abdomen.

INTERPRETATION OF THE FINDINGS & FURTHER RECOMMENDATIONS

There is no ultrasonographically evident cause of reported GI signs in this abdominal study. Pancreas and GI tract are within normal limits. Consideration for dietary indiscretion, infectious etiologies (bacterial, viral, parasitic), food sensitivity/allergy or mild inflammatory bowel disease is reasonable. While not sonographically evident, pancreatitis cannot be completely ruled out. Empiric treatment for GI signs including anti-nausea, appetite stimulant and fluid support as clinically indicated is warranted. A diet trial with hydrolyzed protein or select protein diet could be considered if food sensitivity is suspected clinically. If signs are persistent or recurrent, additional diagnostics to be considered include baseline cortisol +/- ACTH stimulation test, GI panel (TLI/PLI/cobalamin/folate), fecal pathogen panel, thyroid testing, bile acid profile, and thoracic radiographs to rule out occult neoplasia, cardiac disease and esophageal disease as potential causes. Ultimately GI biopsy may be required for more definitive diagnosis if the patient is not responsive to medical treatment.





PATIENT

Millie Lindaberry

SPECIES

Canine

BREED

Border Collie x

SEX

Spayed Female

AGE

7.2 Years

WEIGHT

28.6 lbs

INTERPRETED BY

Dr Brittany Sinclair,
BVSc(hons),
DACVECC

IMAGING PERFORMED BY

Dr. Kristen Carpenter

HOSPITAL NAME

Pennridge Animal
Hospital

REFERRING VET

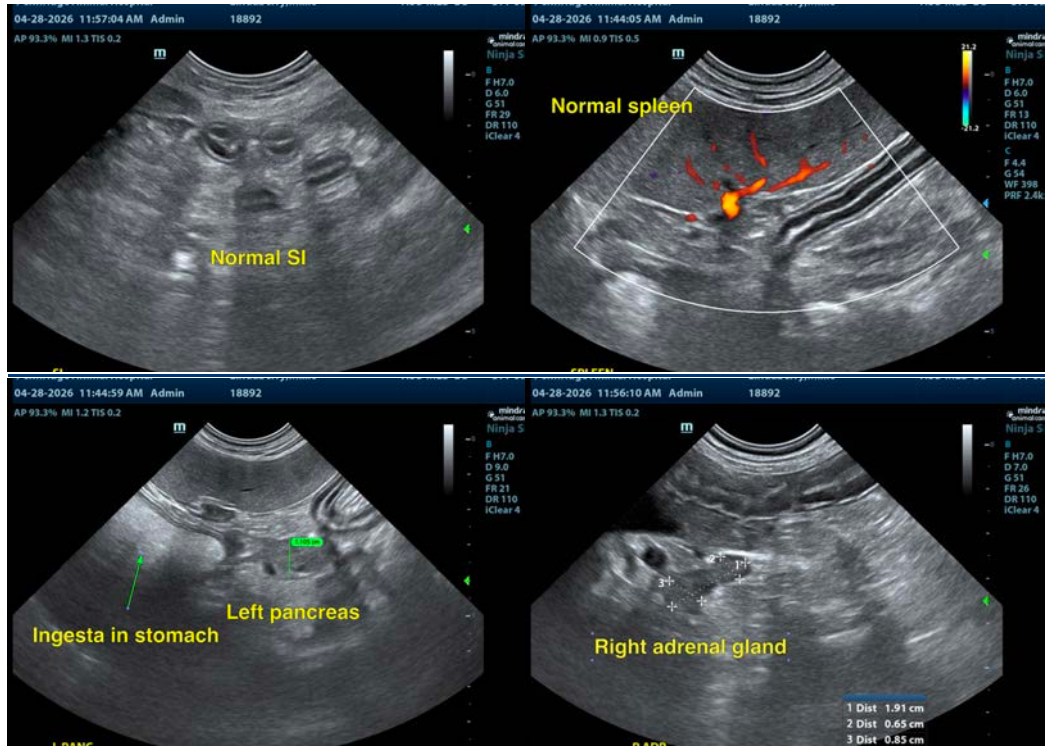
Dr. Beth Mehaffey

INVOICE

74789

DATE

4/29/26



The information and recommendations provided are based on the images presented by the referring veterinarian/sonographer. No evaluation can be communicated regarding pathology that was not visible in the image/video clips provided.

Thank you for this referral. If the clinical or image interpretation does not parallel your findings or if I can be of any further assistance please contact me.

Dr Brittany Sinclair, BVSc(hons), DACVECC

info@SonoPath.com