



PATIENT

Loki Cardone

SPECIES

Feline

BREED

DSH

SEX

Neutered Male

AGE

2 Years 8 Months

WEIGHT

11.8 Pounds

INTERPRETED BY

Brittany Sinclair DVM,
DACVECC

IMAGING PERFORMED BY

Shari Reffi, CVT

HOSPITAL NAME

Animal Mansion VH

REFERRING VET

Dr. Shelly Parker

INVOICE

36748

DATE

4/24/26

PRESENTING CLINICAL SIGNS

History: Weight loss, periodic bloody discharge from rectum. No abnormalities on PE other than weight loss. No current medications. Abnormal PE/Chem/CBC/UA Results: Elevated calcium

ULTRASONOGRAPHIC EXAMINATION OF THE ABDOMEN

Urinary System

The urinary bladder, trigone, and visible pelvic urethra were of normal thickness. The ureters were not visible which is normal. There was normal wall layering with no masses, uroliths or abnormal thickening visualized. Urine was anechoic. No evidence of inflammatory or neoplastic changes were noted.

The kidneys were both normal size and structure, with smooth capsule and normal corticomedullary definition and ratio. Medullary structure differed distinctly from that of the cortex. No evidence of pelvic dilation was present. The left kidney measured 4.01 cm in length. The right kidney measured 4.23 cm in length.

Adrenal Glands

Both adrenal glands were visualized and recognized as having normal shape, size, position and echogenicity for this breed and age. The visible phrenic vasculature was unremarkable. The left adrenal gland measured 0.45 cm in thickness. The right adrenal gland measured 0.43 cm in thickness.

Spleen

The spleen was normal with age-appropriate homogeneous parenchyma and a smooth capsule with normal splenic vasculature with no signs of congestion or thrombosis. No sonographic evidence of acute or chronic inflammatory, neoplastic, or infarct changes were noted.

Liver

The liver is subjectively normal in size with normal contours and structure. There is age-appropriate echogenicity and echotexture. No overt structural evidence of inflammatory, infiltrative or regenerative pathology is evident. Vascular and biliary tracts are of normal volume with no evidence of congestion.

Gall bladder is moderately distended with normal wall thickness and anechoic contents. Common bile duct is non-distended and tapers normally.

Gastrointestinal

The stomach contains minimal luminal contents. It measures at a normal thickness of with some variability due to the presence of rugal folds. The distinction of the gastric wall layers is adequate. No masses or focal lesions were observed.

The visualized areas of duodenum, jejunum and ileum have a relatively uniform diameter with minimal fluid distension. Wall thickness is diffusely increased with normal wall layering and maintenance of normal mucosa/muscularis ratio. There were no focal lesions consistent with obstruction or a mass effect observed.



PATIENT

Loki Cardone

The ileocecal junction was not visualized. Sections of colon are visualized with formed fecal material and gas shadowing distally. There is no observed focal or generalized colon wall thickening or loss of layering.

SPECIES

Feline

Pancreas

The visible pancreas was observed to be largely isoechoic to surrounding omental fat.

BREED

DSH

Lymph Nodes

No clinically significant lymphadenopathy or abnormalities noted.

SEX

Neutered Male

Free Abdomen

No masses or free fluid were noted.

AGE

2 Years 8 Months

ULTRASONOGRAPHIC FINDINGS

- Mild small intestinal thickening

WEIGHT

11.8 Pounds

INTERPRETATION OF THE FINDINGS & FURTHER RECOMMENDATIONS

Small intestinal thickening is mild and may be a variation of normal given reported clinical signs. Infiltrated disease of the small intestine with inflammatory bowel disease or GI lymphoma being the top differentials should be considered. No overt neoplastic criteria present in the bowel given that curvilinear layering is still intact. Ultrasound cannot differentiate between small cell lymphoma and inflammatory bowel disease, and GI biopsies are recommended for definitive diagnosis, especially if there is a poor response to empirical efforts or recurrence of clinical signs after initial control. Endoscopic biopsy is less invasive but may miss lesions due to inability to obtain samples from all sections of the GI tract, especially the jejunum which is the most common site of development of disease. Surgical biopsies are more likely to be diagnostic but are more invasive. A GI panel (TLI/PLI/cobalamin/folate) will help determine the severity of SI dysfunction, and need for vitamin supplementation.

INTERPRETED BY

Brittany Sinclair DVM,
DACVECC

Empiric treatment for IBD includes diet trial with either hydrolyzed or select protein diet, vitamin b-12 supplementation, GI support as needed (anti-nausea, appetite stimulant). Treatment with steroids (budesonide vs prednisolone) is often required – biopsies should be acquired prior to treatment with steroids. Steroids may ultimately be tapered to the lowest effective dose or discontinued in some cases.

IMAGING PERFORMED BY

Shari Reffi, CVT

HOSPITAL NAME

Animal Mansion VH

REFERRING VET

Dr. Shelly Parker

INVOICE

36748

DATE

4/24/26



PATIENT

Loki Cardone

SPECIES

Feline

BREED

DSH

SEX

Neutered Male

AGE

2 Years 8 Months

WEIGHT

11.8 Pounds

INTERPRETED BY

Brittany Sinclair DVM,
 DACVECC

IMAGING PERFORMED BY

Shari Reffi, CVT

HOSPITAL NAME

Animal Mansion VH

REFERRING VET

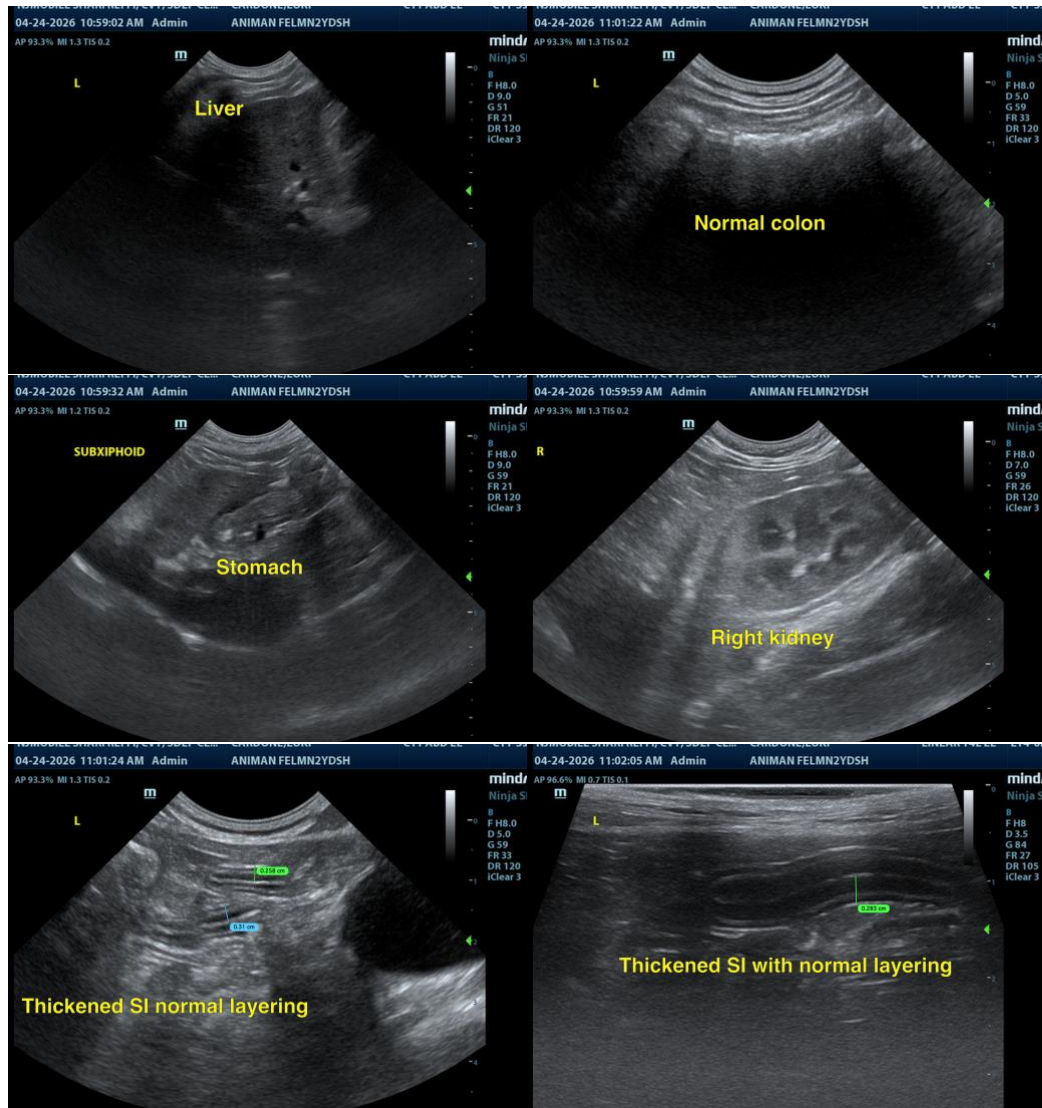
Dr. Shelly Parker

INVOICE

36748

DATE

4/24/26



The information and recommendations provided are based on the images presented by the referring veterinarian/sonographer. No evaluation can be communicated regarding pathology that was not visible in the image/video clips provided.

Thank you for this referral. If the clinical or image interpretation does not parallel your findings or if I can be of any further assistance, please contact me.

Dr Brittany Sinclair, BVSc(hons), DACVECC

info@SonoPath.com