



**PATIENT**

Molly Haymaker

**SPECIES**

Canine

**BREED**

Havanese

**SEX**

Spayed Female

**AGE**

6 Years

**WEIGHT**

18.8 lbs

**INTERPRETED BY**

Dr Brittany Sinclair,  
BVSc(hons),  
DACVECC

**IMAGING PERFORMED BY**

Shari Reffi, CVT

**HOSPITAL NAME**

Pet Stat Animal Urgent  
Care

**REFERRING VET**

Dr. Clause

**INVOICE**

74732

**DATE**

4/23/26

**PRESENTING CLINICAL SIGNS**

ALT elevation. Chronic progressive ALT elevation found on annual exam.  
Abnormal PE/Chem/CBC/UA Results: ALT-304 (H 118), 195 9/2024

**ULTRASONOGRAPHIC EXAMINATION OF THE ABDOMEN**

**Urinary System**

The urinary bladder, trigone, and visible pelvic urethra were of normal thickness. The ureters were not visible which is normal. There was normal wall layering with no masses, uroliths or abnormal thickening visualized. Urine was anechoic. No evidence of inflammatory or neoplastic changes were noted.

The kidneys have a smooth capsule and with hazing of corticomedullary definition to the point of inability to determine cortical/medullary ratio. No evidence of pelvic dilation was present. Hyperechoic, shadowing foci present bilaterally in renal parenchyma and calyces consistent with nephrocalcinosis. Left kidney measures 4.18 cm. Right kidney measures 3.62 cm.

**Adrenal Glands**

Both adrenal glands were visualized and recognized as having normal shape, size, position and echogenicity for this breed and age. The visible phrenic vasculature was unremarkable. Left measures 1.52 cm in length x 0.49 cm at the caudal pole and 0.38 cm at the cranial pole. Right measures 1.81 cm in length x 0.48 cm at the caudal pole and 0.57 cm at the cranial pole.

**Spleen**

The spleen was normal with age appropriate homogeneous parenchyma and a smooth capsule with normal splenic vasculature with no signs of congestion or thrombosis. No sonographic evidence of acute or chronic inflammatory, neoplastic, or infarct changes were noted.

**Liver**

The liver is subjectively normal in size with normal contours and structure. There is age appropriate echogenicity and echotexture. No overt structural evidence of inflammatory, infiltrative or regenerative pathology is evident. Vascular and biliary tracts are of normal volume with no evidence of congestion.

Gall bladder is moderately distended with normal wall thickness and anechoic contents. Common bile duct is non-distended and tapers normally.

**Gastrointestinal**

The stomach contains minimal luminal contents. It measures at a normal thickness of with some variability due to the presence of rugal folds. The distinction of the gastric wall layers is adequate. No masses or focal lesions were observed.

The visualized areas of duodenum, jejunum and ileum have a relatively uniform diameter with minimal fluid distension. Wall thickness is normal. Bowel loops follow a curvilinear path with distinct wall layering maintaining the typical 1:3 muscularis:mucosa layer ratio. There were no focal lesions consistent with obstruction or a mass effect observed.

Sections of colon are visualized with formed fecal material and gas shadowing distally. There is no observed focal or generalized colon wall thickening or loss of layering.



**PATIENT**

Molly Haymaker

**SPECIES**

Canine

**BREED**

Havanese

**SEX**

Spayed Female

**AGE**

6 Years

**WEIGHT**

18.8 lbs

**INTERPRETED BY**

Dr Brittany Sinclair,  
BVSc(hons),  
DACVECC

**IMAGING PERFORMED BY**

Shari Reffi, CVT

**HOSPITAL NAME**

Pet Stat Animal Urgent  
Care

**REFERRING VET**

Dr. Clause

**INVOICE**

74732

**DATE**

4/23/26

**Pancreas**

The visible pancreas was observed to be largely isoechoic to surrounding omental fat.

**Free Abdomen**

No clinically significant lymphadenopathy or abnormalities noted. No free fluid noted.

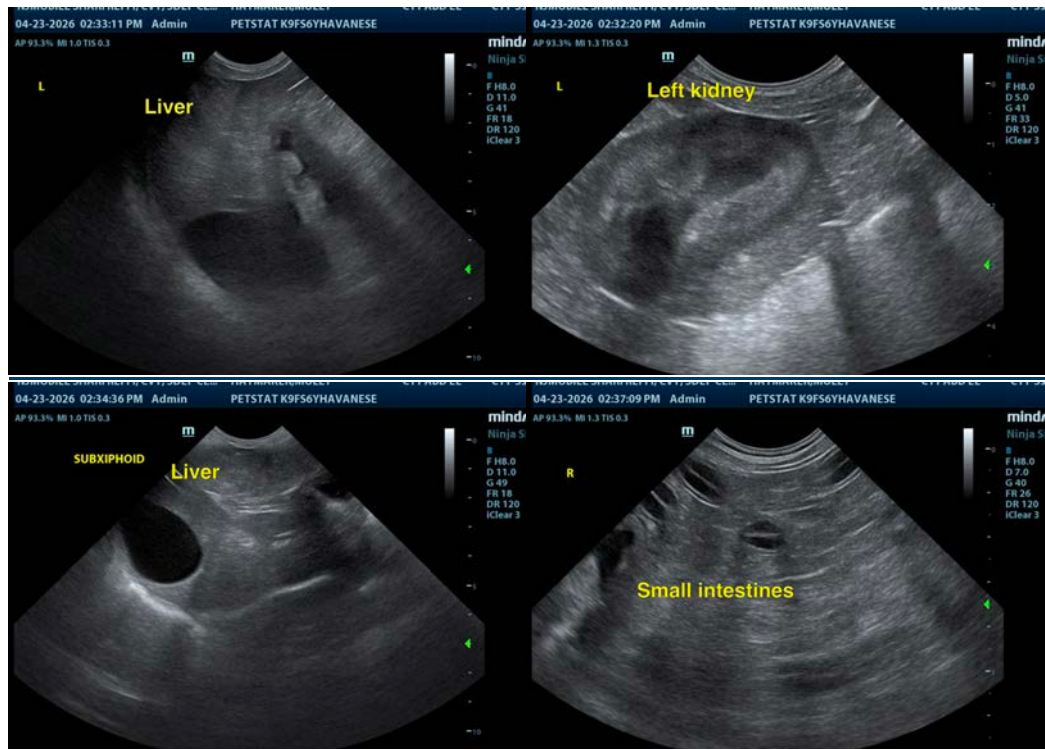
**ULTRASONOGRAPHIC FINDINGS**

- Normal liver and gallbladder.
- Aging renal changes with mild nephrocalcinosis.

**INTERPRETATION OF THE FINDINGS & FURTHER RECOMMENDATIONS**

The liver parenchyma appears normal and there is no ultrasonographic explanation for the elevated liver enzymes in this patient. There is no significant disruption of architecture noted to suggest significant pathology. Low grade inflammatory hepatopathy/reactive hepatopathy is a likely cause of LE elevations. Fine needle aspirate is recommended and bile acid profile to assess liver function. Ultimately liver biopsy is often required for more definitive diagnosis. Empiric treatments (SAM-E, milk thistle, Vitamin E, ursodiol if bilirubin elevated or gall bladder sludge) could be tried and liver enzymes re-evaluated, especially if liver FNA does not show significant pathology before more invasive liver sampling is pursued.

Renal changes are likely age related degeneration. Correlate clinical significance with semi-annual blood work/urinalysis findings and clinical signs.





**PATIENT**

Molly Haymaker

**SPECIES**

Canine

**BREED**

Havanese

**SEX**

Spayed Female

**AGE**

6 Years

**WEIGHT**

18.8 lbs

**INTERPRETED BY**

Dr Brittany Sinclair,  
 BVSc(hons),  
 DACVECC

**IMAGING PERFORMED BY**

Shari Reffi, CVT

**HOSPITAL NAME**

Pet Stat Animal Urgent  
 Care

**REFERRING VET**

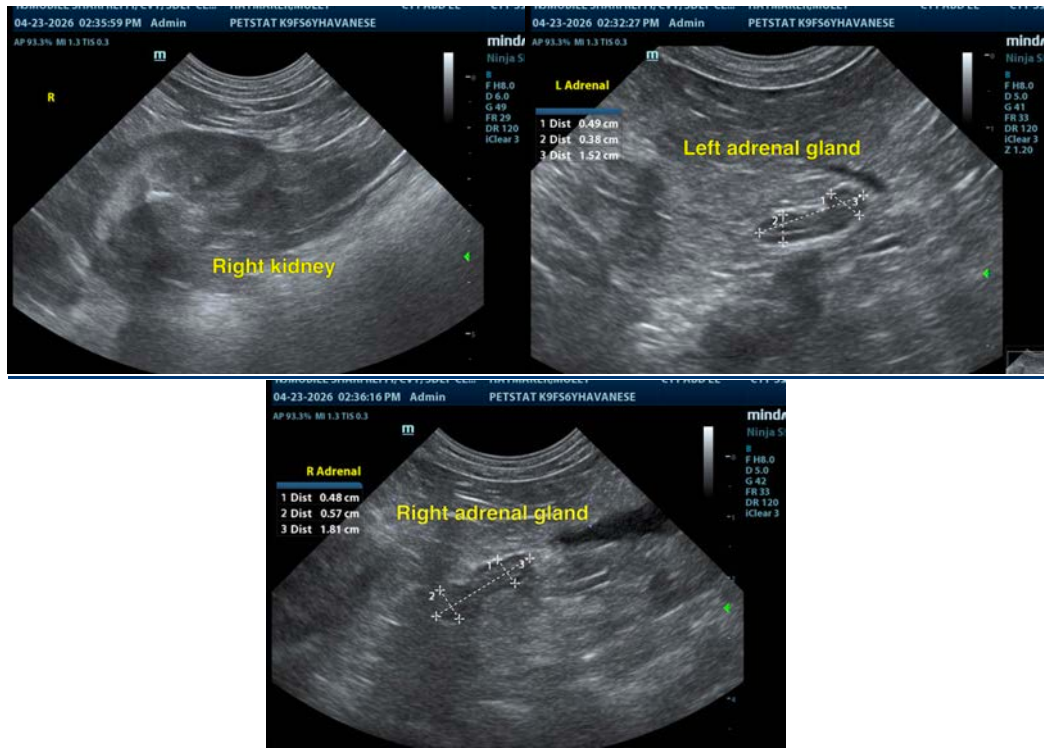
Dr. Clause

**INVOICE**

74732

**DATE**

4/23/26



The information and recommendations provided are based on the images presented by the referring veterinarian/sonographer. No evaluation can be communicated regarding pathology that was not visible in the image/video clips provided.

Thank you for this referral. If the clinical or image interpretation does not parallel your findings or if I can be of any further assistance please contact me.

Dr Brittany Sinclair, BVSc(hons), DACVECC  
 info@SonoPath.com