



**PATIENT**

Harley Burnett

**SPECIES**

Canine

**BREED**

German Shepherd

**SEX**

Neutered Male

**AGE**

7 Years

**WEIGHT**

48.3 kg

**INTERPRETED BY**

Dr Brittany Sinclair,  
 BVSc(hons), DACVECC

**IMAGING PERFORMED BY**

Amanda Stewart

**HOSPITAL NAME**

Wellington Animal  
 Hospital

**REFERRING VET**

Dr. Dennis

**INVOICE**

15256

**DATE**

04/20/26

**PRESENTING CLINICAL SIGNS**

Diarrhea for the past 3 weeks with decreased appetite. Muscle loss but up in weight (moderate muscle/fat loss all over body). Abdomen distended with fluid wave present. Pitting edema on both hind legs (worse on the right side) prominent popliteal lymph nodes. Unable to auscultate chest well as whining/panting throughout the exam but no overt arrhythmia appreciated.

Current Medications: Metronidazole 500 mg q 12 hours

Abnormal PE/Chem/CBC/UA Results: Low albumin (results emailed separately) Primary Question to Be Answered in This Exam Fluid in abdomen? Reason for fluid? Sampling done today of fluid.

**ULTRASONOGRAPHIC EXAMINATION OF THE ABDOMEN**

*Urinary System*

Urinary bladder lumen volume is small, and walls are diffusely thickened most consistent with pseudohypertrophy. The ureters were not visible which is normal. There was normal wall layering with no masses, uroliths or abnormal focal thickening visualized. Urine was anechoic. No evidence of inflammatory or neoplastic changes were noted.

The kidneys have a smooth capsule and with hazing of corticomedullary definition to the point of inability to determine cortical/medullary ratio. Hyperechoic, shadowing foci present in renal parenchyma and calyces consistent with nephrocalcinosis. The left kidney measured 7.39 cm in length. The right kidney measured 8.3 cm in length.

*Adrenal Glands*

Both adrenal glands are not distinctly visualized bilaterally. The area of the adrenal glands is visualized, and surrounding vasculature is unremarkable.

*Spleen*

The spleen is subjectively normal in size with a diffusely heterogeneous to micronodular echotexture. There are no specific masses visualized. Capsular margins are slightly irregular.

*Liver*

The liver is subjectively normal in size with normal contours and structure. There is age-appropriate echogenicity and echotexture. No overt structural evidence of inflammatory, infiltrative or regenerative pathology is evident. Vascular and biliary tracts are of normal volume with no evidence of congestion.

Gall bladder is moderately distended with normal wall thickness and anechoic contents. Common bile duct is non-distended and tapers normally.

*Gastrointestinal*

The stomach contains minimal luminal contents. It measures at a normal thickness of with some variability due to the presence of rugal folds. The distinction of the gastric wall layers is adequate. No masses or focal lesions were observed.

The visualized areas of duodenum, jejunum and ileum have a relatively uniform diameter with minimal fluid distension. Wall thickness is normal. Bowel loops follow a curvilinear path with distinct wall



**PATIENT**

Harley Burnett

**SPECIES**

Canine

**BREED**

German Shepherd

**SEX**

Neutered Male

**AGE**

7 Years

**WEIGHT**

48.3 kg

**INTERPRETED BY**

Dr Brittany Sinclair,  
 BVSc(hons), DACVECC

**IMAGING PERFORMED BY**

Amanda Stewart

**HOSPITAL NAME**

Wellington Animal  
 Hospital

**REFERRING VET**

Dr. Dennis

**INVOICE**

15256

**DATE**

04/20/26

layering maintaining the typical 1:3 muscularis: mucosa layer ratio. There were no focal lesions consistent with obstruction or a mass effect observed.

The ileocecal junction was not visualized. Sections of colon are visualized with formed fecal material and gas shadowing distally. There is no observed focal or generalized colon wall thickening or loss of layering.

***Pancreas***

The pancreas is not distinctly visualized.

***Lymph Nodes***

No clinically significant lymphadenopathy or abnormalities noted.

***Free Abdomen***

There is a large volume of anechoic fluid noted in every quadrant.

**ULTRASONOGRAPHIC FINDINGS**

- Large volume abdominal effusion.
- Diffusely mottled spleen with micronodular echotexture.
- Mild aging renal changes.

**INTERPRETATION OF THE FINDINGS & FURTHER RECOMMENDATIONS**

The definitive cause of hypoalbuminemia is not identified in this study. Urinalysis is recommended to evaluate for protein losing enteropathy. Hypoadrenocorticism should be ruled out with a baseline cortisol +/- ACTH stimulation test. This would be an unusual presentation of this disease. Liver function should be assessed with a bile acid profile - this would also be an unusual presentation of liver failure related hypoalbuminemia. For completeness thoracic radiographs and an echocardiogram to rule out right sided heart failure should be considered. This would generally cause a modified transudate effusion, rather than a pure transudate.

Given the patient's reported Gi signs, protein losing enteropathy is a top differential for the hypoalbuminemia, though no distinct GI lesions were seen on ultrasound. Abdominocentesis is recommended - if fluid is clear with a total solid of zero (pure transudate), this is consistent with a low oncotic pressure caused effusion - in this case due to protein loss through the GI tract. If the fluid is of any other nature, fluid analysis and cytology is recommended. Ultimately small intestinal biopsy is necessary to attempt to determine an underlying cause, though patients with low albumin levels often have trouble healing. Treatment involves diet modification (hydrolyzed or novel protein), GI support as needed and steroid therapy. Therapeutic abdominocentesis can be helpful in alleviating GI signs - goals of therapy are not to remove every drop of fluid, but to reduce the volume to decrease the pressure surrounding the organs and especially the GI tract which can decrease appetite, cause lethargy etc.

The splenic parenchymal changes are concerning for infiltrative disease but may represent a benign or reactive inflammatory change or could reflect extramedullary hematopoiesis. Fine needle aspirate is recommended to further characterize.



**PATIENT**

Harley Burnett

**SPECIES**

Canine

**BREED**

German Shepherd

**SEX**

Neutered Male

**AGE**

7 Years

**WEIGHT**

48.3 kg

**INTERPRETED BY**

Dr Brittany Sinclair,  
 BVSc(hons), DACVECC

**IMAGING PERFORMED BY**

Amanda Stewart

**HOSPITAL NAME**

Wellington Animal  
 Hospital

**REFERRING VET**

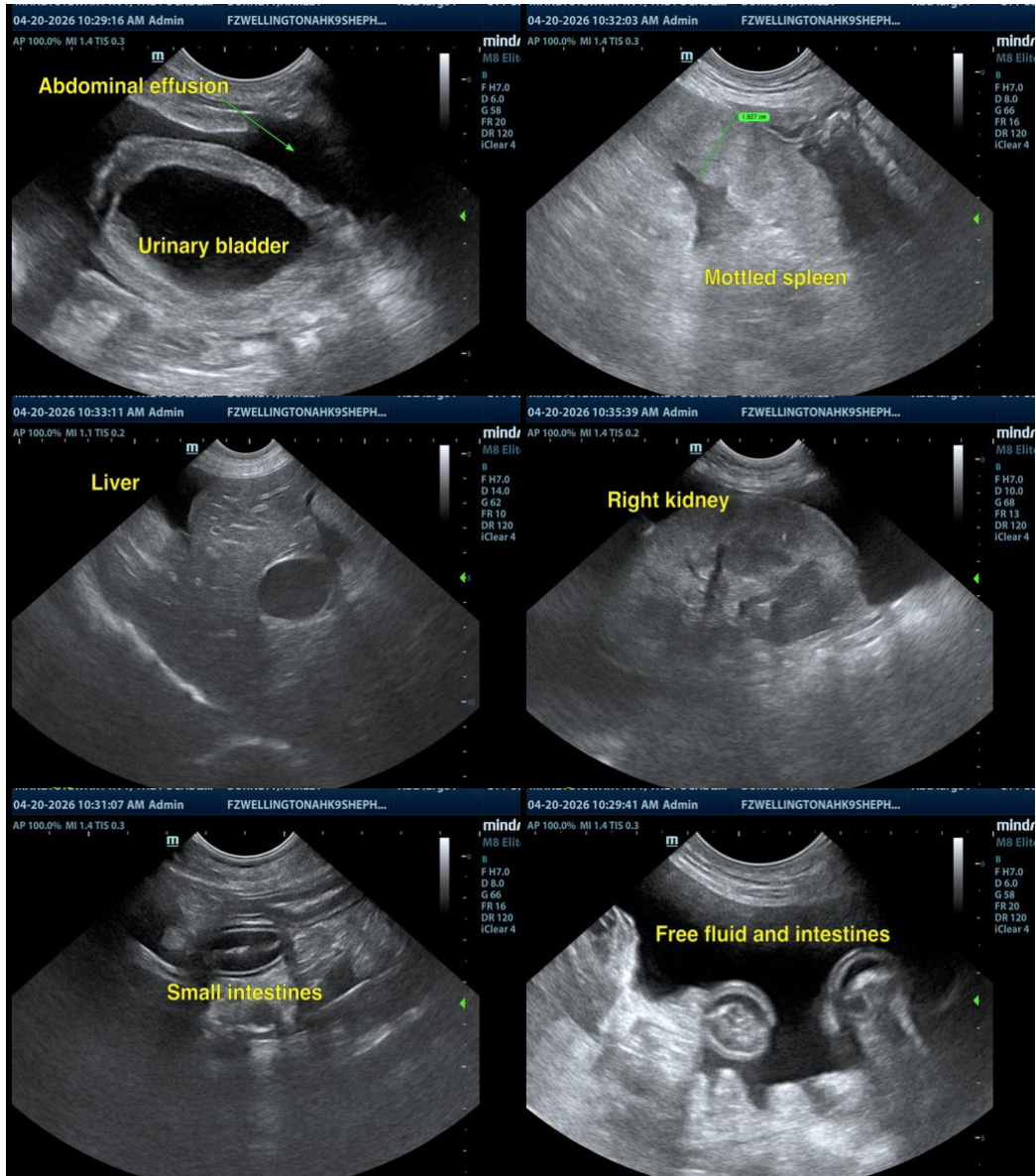
Dr. Dennis

**INVOICE**

15256

**DATE**

04/20/26



The information and recommendations provided are based on the images presented by the referring veterinarian/sonographer. No evaluation can be communicated regarding pathology that was not visible in the image/video clips provided.

Thank you for this referral. If the clinical or image interpretation does not parallel your findings or if I can be of any further assistance, please contact me.

Dr Brittany Sinclair, BVSc(hons), DACVECC

info@SonoPath.com