



PATIENT

Kirito Rodriguez

SPECIES

Canine

BREED

Mixed

SEX

Neutered Male

AGE

11 Years

WEIGHT

38.6 lbs

INTERPRETED BY

Dr Brittany Sinclair,
BVSc(hons),
DACVECC

IMAGING PERFORMED BY

Gabriel Ferrer, DVM

HOSPITAL NAME

Pulse: Pet Ultrasound

REFERRING VET

Dr. Michael Pabon

INVOICE

73333

DATE

3/3/26

PRESENTING CLINICAL SIGNS

Px presented as a referral for an abdominal ultrasound due to Hx of arrhythmias and elevated liver enzymes. rDVM wanted to rule out a hepatic mass causing the arrhythmias. Hx of Pancreatitis. Heart murmur was ausculted and Dx with Sinus Bradycardia. Had Sx for Pneumothorax and partial lung lobectomy 5/15/2024

Abnormal PE/Chem/CBC/UA Results: Bloodwork and rDVM records attached below for your reference

ULTRASONOGRAPHIC EXAMINATION OF THE ABDOMEN

Urinary System

The urinary bladder, trigone, and visible pelvic urethra were of normal thickness. The ureters were not visible which is normal. There was normal wall layering with no masses, uroliths or abnormal thickening visualized. Urine was anechoic. No evidence of inflammatory or neoplastic changes were noted.

The kidneys were both normal size and structure, with smooth capsule and normal corticomedullary definition and ratio. Medullary structure differed distinctly from that of the cortex. No evidence of pelvic dilation was present. Left measures 5.88 cm in length. Right measures 5.39 cm in length.

Adrenal Glands

Both adrenal glands were visualized and recognized as having normal shape, size, position and echogenicity for this breed and age. The visible phrenic vasculature was unremarkable. Right measures 2.02 cm in length x 0.60 cm at the caudal pole and 0.58 cm at the cranial pole. Left measures 2.01 cm in length x 0.49 cm at the caudal pole and 0.50 cm at the cranial pole.

Spleen

The spleen was normal with age appropriate homogeneous parenchyma and a smooth capsule with normal splenic vasculature with no signs of congestion or thrombosis. No sonographic evidence of acute or chronic inflammatory, neoplastic, or infarct changes were noted.

Liver

The liver is subjectively normal in size with normal contours and structure. There is age appropriate echogenicity and echotexture. No overt structural evidence of inflammatory, infiltrative or regenerative pathology is evident. Vascular and biliary tracts are of normal volume with no evidence of congestion.

Gall bladder is moderately distended with normal wall thickness and anechoic contents. Common bile duct is non-distended and tapers normally.

Gastrointestinal

The stomach contains a small amount of both anechoic and echogenic fluid material with a small amount of gas shadowing. It is not overtly distended. The gastric wall is diffusely thickened, with a prominent muscularis layer. There are no focal lesions consistent with a mass. There is an impression of decreased motility.

The visualized areas of duodenum, jejunum and ileum have a relatively uniform diameter with minimal fluid distension. Wall thickness is normal. Bowel loops follow a curvilinear path with distinct wall layering maintaining the typical 1:3 muscularis:mucosa layer ratio. There were no focal lesions consistent with obstruction or a mass effect observed.



PATIENT

Kirito Rodriguez

The ileocecal junction was visualized and exhibited normal intact wall layering and is subjectively of normal thickness. Sections of colon are visualized with formed fecal material and gas shadowing distally. There is no observed focal or generalized colon wall thickening or loss of layering.

SPECIES

Canine

Pancreas

The visible pancreas was observed to be largely isoechoic to surrounding omental fat.

BREED

Mixed

Free Abdomen

No clinically significant lymphadenopathy or abnormalities noted. No free fluid noted.

SEX

Neutered Male

ULTRASONOGRAPHIC FINDINGS

- Thickened gastric wall with prominent muscularis layer.

INTERPRETATION OF THE FINDINGS & FURTHER RECOMMENDATIONS

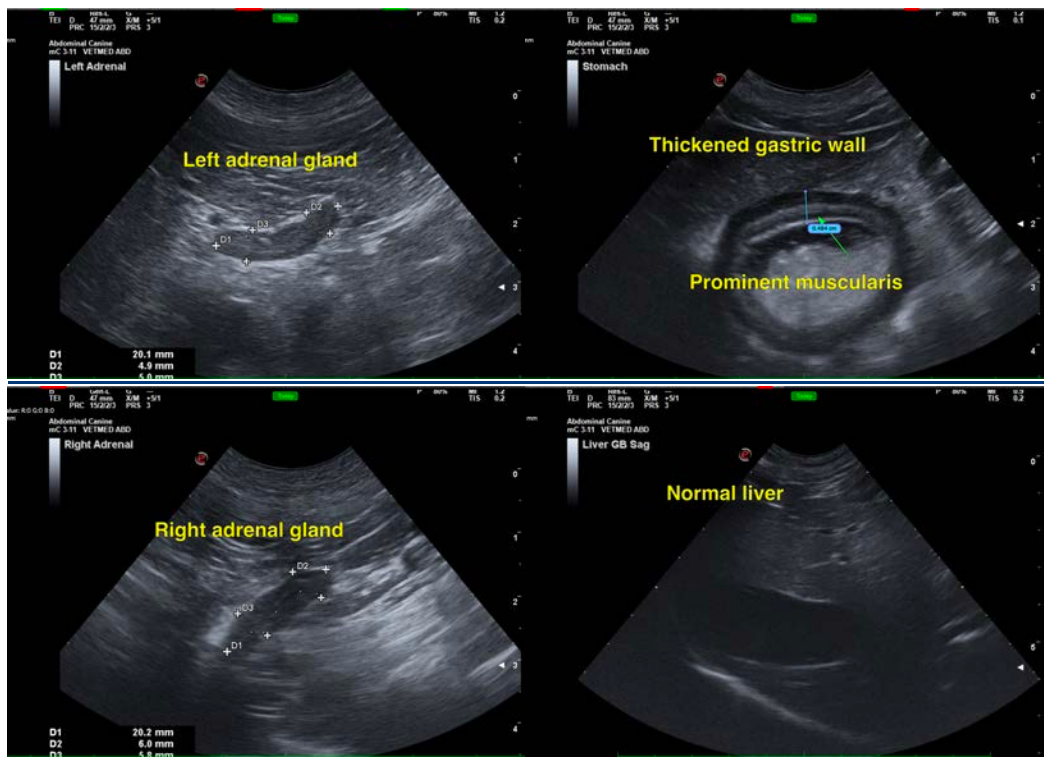
There is no overt abdominal cause of reported VPCs on abdominal ultrasound. No splenic, liver or other masses were seen. Gastric wall thickening is of uncertain clinical significance. Gastric biopsy should be considered to further define. GI disease can increase vagal tone, which can predispose to arrhythmias.

WEIGHT

38.6 lbs

INTERPRETED BY

Dr Brittany Sinclair,
BVSc(hons),
DACVECC



IMAGING PERFORMED BY

Gabriel Ferrer, DVM

HOSPITAL NAME

Pulse: Pet Ultrasound

REFERRING VET

Dr. Michael Pabon

INVOICE

73333

DATE

3/3/26



PATIENT

Kirito Rodriguez

SPECIES

Canine

BREED

Mixed

SEX

Neutered Male

AGE

11 Years

WEIGHT

38.6 lbs

INTERPRETED BY

Dr Brittany Sinclair,
BVSc(hons),
DACVECC

IMAGING PERFORMED BY

Gabriel Ferrer, DVM

HOSPITAL NAME

Pulse: Pet Ultrasound

REFERRING VET

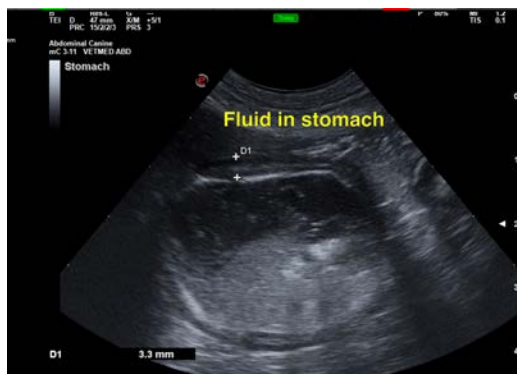Dr. Michael Pabon

INVOICE

73333

DATE

3/3/26



The information and recommendations provided are based on the images presented by the referring veterinarian/sonographer. No evaluation can be communicated regarding pathology that was not visible in the image/video clips provided.

Thank you for this referral. If the clinical or image interpretation does not parallel your findings or if I can be of any further assistance please contact me.

Dr Brittany Sinclair, BVSc(hons), DACVECC

info@SonoPath.com