



PATIENT

Lilly Scott

SPECIES

Canine

BREED

Pitbull Mix

SEX

Spayed Female

AGE

11 years

WEIGHT

50.8 lbs

INTERPRETED BY

Dr Brittany Sinclair,
BVSc(hons),
DACVECC

IMAGING PERFORMED BY

Meghan Morse, LVT,
CVT

HOSPITAL NAME

Newton Veterinary
Hospital

REFERRING VET

Dr. Timony

INVOICE

11347

DATE

2/20/2026

PRESENTING CLINICAL SIGNS

- Pancreatitis, cushings, v+, D+
- Obtunded distended abdomen, radiographs- cranial mass effect, hepatomegaly
- Current meds: Vetoryl, Thyrotabs

Abnormal PE/Chem/CBC/UA Results: Cortisol >30 WBC 27.7, Neuts 24.35, Mono 2.02 BUN 71.6, Creat 4.5, ALT 149, Na 140, K 2.6, Cl 78 Lepto snap negative U/A: protein 3+, 3+ bili, 2+ bld, RBC 21-50, USG 1.037.

ULTRASONOGRAPHIC EXAMINATION OF THE ABDOMEN

Urinary System

The urinary bladder, trigone, and visible pelvic urethra were of normal thickness. The ureters were not visible which is normal. There was normal wall layering with no masses, uroliths or abnormal thickening visualized. Urine was anechoic. No evidence of inflammatory or neoplastic changes were noted.

The kidneys were both normal size and structure, with smooth capsule and normal corticomedullary definition and ratio. Medullary structure differed distinctly from that of the cortex. No evidence of pelvic dilation was present.

Left kidney measures 6.40 cm in length, and the right kidney measures 6.46 cm in length.

Adrenal Glands

The cranial pole of the left adrenal gland is significantly enlarged and heterogenous. Consistent with a left adrenal mass. There is no obvious abnormalities with the phrenic vasculature. The right adrenal gland was not definitively visualized.

Left adrenal measures 4.33 cm, 2.26 cm at the cranial pole and 0.70 cm at the caudal pole.

Spleen

The spleen was normal with age appropriate homogeneous parenchyma and a smooth capsule with normal splenic vasculature with no signs of congestion or thrombosis. No sonographic evidence of acute or chronic inflammatory, neoplastic, or infarct changes were noted.

Liver

The liver is diffusely enlarged and coarse with multifocal variably size, somewhat poorly defined small nodules throughout. No specific masses were visualized.

Gall bladder is moderately distended with normal wall thickness and anechoic contents. Common bile duct is non-distended and tapers normally.

Gastrointestinal

Gastric wall is diffusely thickened and hypoechoic with maintenance of wall layering. There are no focal lesions consistent with mass effect. There are minimal luminal contents.



PATIENT

Lilly Scott

The visualized areas of duodenum, jejunum and ileum have a relatively uniform diameter with minimal fluid distension. Wall thickness is normal. Bowel loops follow a curvilinear path with distinct wall layering maintaining the typical 1:3 muscularis:mucosa layer ratio. There were no focal lesions consistent with obstruction or a mass effect observed.

SPECIES

Canine

Visible colonic wall appears thickened with normal wall layering. Contents are anechoic, fluid speckled with hyperechoic foci and gas shadowing consistent with diarrhea. Ileocecal junction is not visualized.

BREED

Pitbull Mix

Pancreas

The area of the pancreas is significantly hyperechoic, consistent with peripancreatic inflammation.

SEX

Spayed Female

Free Abdomen

There is a small volume of fluid visible in every quadrant. Omentum/mesentery is diffusely hyperechoic, consistent with peritonitis.

AGE

11 years

ULTRASONOGRAPHIC FINDINGS

- Left adrenal mass.
- Hepatomegaly with poorly defined nodules.
- Gastric and colonic wall thickening consistent with gastroenterocolitis.
- Small volume of free fluid and diffusely hyperechoic mesentery consistent with peritonitis – Likely secondary to pancreatitis.

WEIGHT

50.8 lbs

INTERPRETED BY

Dr Brittany Sinclair,
 BVSc(hons),
 DACVECC

INTERPRETATION OF THE FINDINGS & FURTHER RECOMMENDATIONS

There is significant intraabdominal inflammation causing peritonitis and scant free fluid. Abdominocentesis with fluid analysis should be attempted to further define the nature of the effusion. Pancreatic tissue was not distinctly visualized, however, peripancreatic inflammation was present and pancreatitis is a possible differential for clinical signs and peritonitis.

IMAGING PERFORMED BY

Meghan Morse, LVT,
 CVT

Treatment for pancreatitis is entirely supportive and involves fluid support, GI support - anti-nausea (ondansetron, cerenia 2mg/kg PO SID), appetite stimulation (mirtazapine, elura), analgesia (buprenorphine, gabapentin) and enteral nutrition as needed (syringe feeding, NG tube placement, etc). Panoquel could be considered if available and deemed clinically warranted. Antibiotics are generally not warranted for acute pancreatitis as it is usually sterile, however given the severity of inflammation I would use antibiotics (ex unasyn +/- fluoroquinolone) in this case. Intravenous antibiotics are preferred to ensure absorption and decrease GI side effects of oral antibiotics which can lower appetite compromising treatment and recovery. Anti-inflammatory steroids may be tried in an attempt to reduce inflammation if traditional supportive care is inadequate. Serial imaging is indicated to monitor response to treatment.

HOSPITAL NAME

Newton Veterinary
 Hospital

REFERRING VET

Dr. Timony

INVOICE

11347

If patient does not respond to supportive care, recheck imaging (ultrasound, abdominal CT) or abdominal explore should be considered. Repeat attempts at abdominocentesis should be tried if fluid cannot be obtained. Initially fluid may be more obtainable after rehydration.

DATE

2/20/2026

Adrenal gland changes are most consistent with an adrenal mass. This is a likely cause of hepatic changes. Liver FNA should be considered to investigate for other possibilities. Adrenal gland disease is



PATIENT

Lilly Scott

SPECIES

Canine

BREED

Pitbull Mix

SEX

Spayed Female

AGE

11 years

WEIGHT

50.8 lbs

INTERPRETED BY

Dr Brittany Sinclair,
 BVSc(hons),
 DACVECC

IMAGING PERFORMED BY

Meghan Morse, LVT,
 CVT

HOSPITAL NAME

Newton Veterinary
 Hospital

REFERRING VET

Dr. Timony

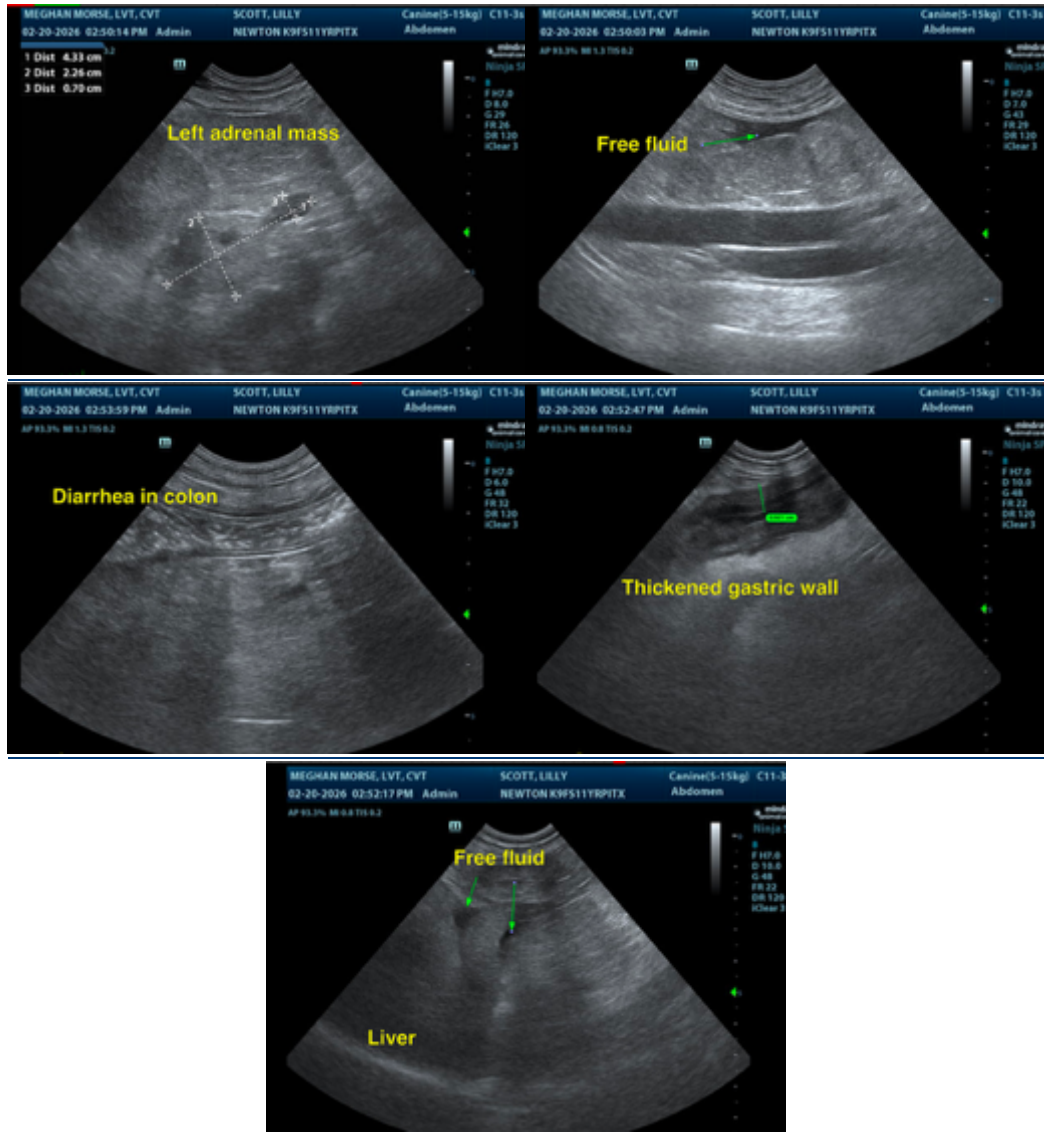
INVOICE

11347

DATE

2/20/2026

not a likely cause of current clinical signs. Further workup for adrenal gland disease should be considered when patient has recovered from current GI signs.



The information and recommendations provided are based on the images presented by the referring veterinarian/sonographer. No evaluation can be communicated regarding pathology that was not visible in the image/video clips provided.

Thank you for this referral. If the clinical or image interpretation does not parallel your findings or if I can be of any further assistance please contact me.

Dr Brittany Sinclair, BVSc(hons), DACVECC

info@SonoPath.com