



PATIENT

Atenea
Verna/Lavarone

SPECIES

Canine

BREED

Presa Canario

SEX

Spayed Female

AGE

8 Years

WEIGHT

56.5 kg

INTERPRETED BY

Dr Brittany Sinclair,
BVSc(hons),
DACVECC

IMAGING PERFORMED BY

Crystal Hill

HOSPITAL NAME

Grand River Veterinary
Hospital

REFERRING VET

Dr. Kenny-Foeldessy

INVOICE

73009

DATE

2/17/26

PRESENTING CLINICAL SIGNS

Two episodes of collapse 4 months apart, no known inciting factors, no loss of bladder or bowel control. Polydipsia noted. No c/s/v/d. PE TPR WNL, has lost weight bus has been working on weight loss, t4 well controlled in the last year, BCS 6/9, BAR on PE Feb 7, 26. BW showed mild non regenerative anemia, elevated SDMA and globulins

Abnormal PE/Chem/CBC/UA Results: Please see attached lab results.

ULTRASONOGRAPHIC EXAMINATION OF THE ABDOMEN

Urinary System

The urinary bladder, trigone, and visible pelvic urethra were of normal thickness. The ureters were not visible which is normal. There was normal wall layering with no masses, uroliths or abnormal thickening visualized. Urine was anechoic. No evidence of inflammatory or neoplastic changes were noted.

The left kidney has a smooth capsule and with hazing of corticomedullary definition to the point of inability to determine cortical/medullary ratio. No evidence of pelvic dilation was present. Hyperechoic, shadowing foci present in renal parenchyma and calyces consistent with nephrocalcinosis. Left kidney measures 7.39 cm. The measurement of the left kidney may be underestimated, as it is visualized and measured at a slightly oblique angle.

The right kidney is visualized on still image only. It appears to generally be of normal shape and echotexture. Right kidney measures 10.02 cm. Measurement of right kidney is likely overestimated due to angle of measurement.

Adrenal Glands

The left adrenal gland is visualized and recognized as having normal shape, size, position and echogenicity for this breed and age. The visible phrenic vasculature was unremarkable. Left measures 3.19 cm in length x 0.51 cm at the caudal pole and 0.49 cm at the cranial pole.

The right adrenal gland is not visualized.

Spleen

The spleen is not distinctly visualized.

Liver

The liver contains a multilobulated, complex, solid mass that spans multiple liver lobes, with areas of cavitation in the right liver lobe. There is some relatively normal liver parenchyma visible. There is free fluid noted between lobes. The actual size of the mass cannot be determined, as it is very large and does not fit on one imaging plane.

Gall bladder is moderately distended with normal wall thickness and anechoic contents. Common bile duct is non-distended and tapers normally.

Gastrointestinal

The stomach contains minimal luminal contents. It measures at a normal thickness of with some variability due to the presence of rugal folds. The distinction of the gastric wall layers is adequate. No masses or focal lesions were observed.



PATIENT

Atenea
Verna/Lavarone

SPECIES

Canine

BREED

Presa Canario

SEX

Spayed Female

AGE

8 Years

WEIGHT

56.5 kg

INTERPRETED BY

Dr Brittany Sinclair,
BVSc(hons),
DACVECC

IMAGING PERFORMED BY

Crystal Hill

HOSPITAL NAME

Grand River Veterinary
Hospital

REFERRING VET

Dr. Kenny-Foeldessy

INVOICE

73009

DATE

2/17/26

The visualized areas of duodenum, jejunum and ileum have a relatively uniform diameter with minimal fluid distension. Wall thickness is normal. Bowel loops follow a curvilinear path with distinct wall layering maintaining the typical 1:3 muscularis:mucosa layer ratio. There were no focal lesions consistent with obstruction or a mass effect observed.

Sections of colon are visualized with gas shadowing distally. There is no observed focal or generalized colon wall thickening or loss of layering.

Pancreas

The pancreas is not distinctly visualized.

Free Abdomen

No clinically significant lymphadenopathy or abnormalities noted.

There is scant free fluid, especially around liver lobes.

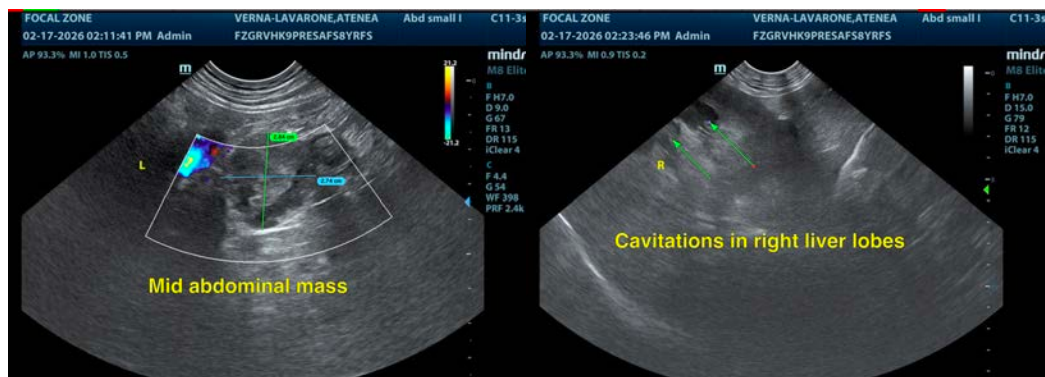
In the mid to left abdomen, there are multiple complex, heterogeneous, partially cavitated, spherical mass-like structures, one measuring 2.8 cm x 2.7 cm. A second mass measures 4.4 cm x 3.9 cm.

ULTRASONOGRAPHIC FINDINGS

- Complex, multilobulated, very large liver mass.
- Multiple mid abdominal masses – splenic vs omental vs other.
- Scant free fluid.

INTERPRETATION OF THE FINDINGS & FURTHER RECOMMENDATIONS

The mass in the liver is very large and not likely to be resectable. I am concerned about metastasis in other organs, given the presence of masses in the mid left abdomen. This may represent splenic masse vs other. Abdominal CT may be required to further differentiate the origin of the masses. Unfortunately, surgical resection is not a likely option in this patient, given extent of the lesions. Consultation with a veterinary surgeon could be considered if desired.





PATIENT

Atenea
 Verna/Lavarone

SPECIES

Canine

BREED

Presa Canario

SEX

Spayed Female

AGE

8 Years

WEIGHT

56.5 kg

INTERPRETED BY

Dr Brittany Sinclair,
 BVSc(hons),
 DACVECC

IMAGING PERFORMED BY

Crystal Hill

HOSPITAL NAME

Grand River Veterinary
 Hospital

REFERRING VET

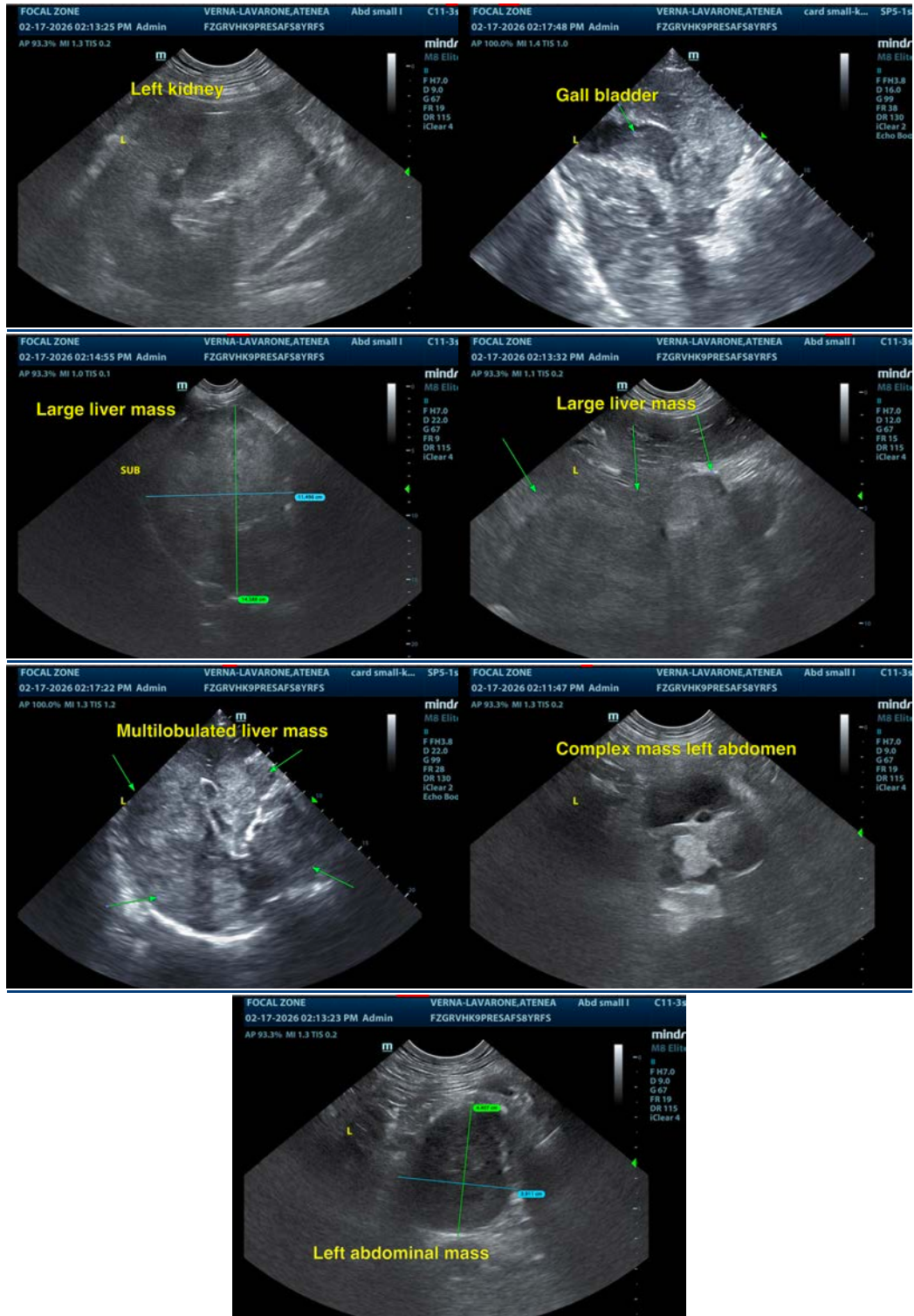
Dr. Kenny-Foeldessy

INVOICE

73009

DATE

2/17/26





PATIENT

Atenea
Verna/Lavarone

SPECIES

Canine

BREED

Presa Canario

SEX

Spayed Female

AGE

8 Years

WEIGHT

56.5 kg

INTERPRETED BY

Dr Brittany Sinclair,
BVSc(hons),
DACVECC

**IMAGING
PERFORMED BY**

Crystal Hill

HOSPITAL NAME

Grand River Veterinary
Hospital

REFERRING VET

Dr. Kenny-Foeldessy

INVOICE

73009

DATE

2/17/26

The information and recommendations provided are based on the images presented by the referring veterinarian/sonographer. No evaluation can be communicated regarding pathology that was not visible in the image/video clips provided.

Thank you for this referral. If the clinical or image interpretation does not parallel your findings or if I can be of any further assistance please contact me.

Dr Brittany Sinclair, BVSc(hons), DACVECC

info@SonoPath.com