



PATIENT

Bella Cartwright

SPECIES

Canine

BREED

Shepherd x

SEX

Spayed Female

AGE

10 Years

WEIGHT

28 kg

INTERPRETED BY

Dr Brittany Sinclair,
 BVSc(hons),
 DACVECC

IMAGING PERFORMED BY

Kelly Reschny

HOSPITAL NAME

Lynden Animal Clinic

REFERRING VET

Dr. Collins

INVOICE

72915

DATE

2/12/26

PRESENTING CLINICAL SIGNS

Large (15-20cm) lump on the right side of the body just behind the ribcage present for a few years. Difficult to tell on palpation if this is a deep SQ mass or actually organomegaly. Pt is not clinical for this mass, but it may have grown a bit and owner would like imaged.

ULTRASONOGRAPHIC EXAMINATION OF THE ABDOMEN

Urinary System

The urinary bladder, trigone, and visible pelvic urethra were of normal thickness. The ureters were not visible which is normal. There was normal wall layering with no masses, uroliths or abnormal thickening visualized. Urine was anechoic. No evidence of inflammatory or neoplastic changes were noted.

The kidneys were both normal size and structure, with smooth capsule and normal corticomedullary definition and ratio. Medullary structure differed distinctly from that of the cortex. No evidence of pelvic dilation was present. Left kidney measured 6.26 cm. Right kidney measured 6.7 cm.

Adrenal Glands

Both adrenal glands were visualized and recognized as having normal shape, size, position and echogenicity for this breed and age. The visible phrenic vasculature was unremarkable. Left measured 2.26 cm in length x 0.35 cm at the caudal pole and 0.36 cm at the cranial pole. Right measured 2.4 cm in length x 0.48 cm in thickness.

Spleen

The spleen was normal with age appropriate homogeneous parenchyma and a smooth capsule with normal splenic vasculature with no signs of congestion or thrombosis. No sonographic evidence of acute or chronic inflammatory, neoplastic, or infarct changes were noted.

Liver

The liver is subjectively normal in size with normal contours and structure. There is age appropriate echogenicity and echotexture. No overt structural evidence of inflammatory, infiltrative or regenerative pathology is evident. Vascular and biliary tracts are of normal volume with no evidence of congestion.

Gall bladder is moderately distended with normal wall thickness and anechoic contents. Common bile duct is non-distended and tapers normally.

Gastrointestinal

The stomach contains minimal luminal contents. It measures at a normal thickness of with some variability due to the presence of rugal folds. The distinction of the gastric wall layers is adequate. No masses or focal lesions were observed.

The visualized areas of duodenum, jejunum and ileum have a relatively uniform diameter with minimal fluid distension. Wall thickness is normal. Bowel loops follow a curvilinear path with distinct wall layering maintaining the typical 1:3 muscularis:mucosa layer ratio. There were no focal lesions consistent with obstruction or a mass effect observed.

Sections of colon are visualized with formed fecal material and gas shadowing distally. There is no observed focal or generalized colon wall thickening or loss of layering.



PATIENT

Bella Cartwright

SPECIES

Canine

BREED

Shepherd x

SEX

Spayed Female

AGE

10 Years

WEIGHT

28 kg

INTERPRETED BY

Dr Brittany Sinclair,
BVSc(hons),
DACVECC

IMAGING PERFORMED BY

Kelly Reschny

HOSPITAL NAME

Lynden Animal Clinic

REFERRING VET

Dr. Collins

INVOICE

72915

DATE

2/12/26

Pancreas

The area of the pancreas was isoechoic to surrounding tissue with no overt inflammation. Pancreatic tissue was not distinctly visualized which is common.

Free Abdomen

No clinically significant lymphadenopathy or abnormalities noted. No free fluid noted.

There is a still image provided of a homogeneous mass measuring approximately 6.0 cm x 7.0 cm. Echogenicity is most consistent with a lipoma.

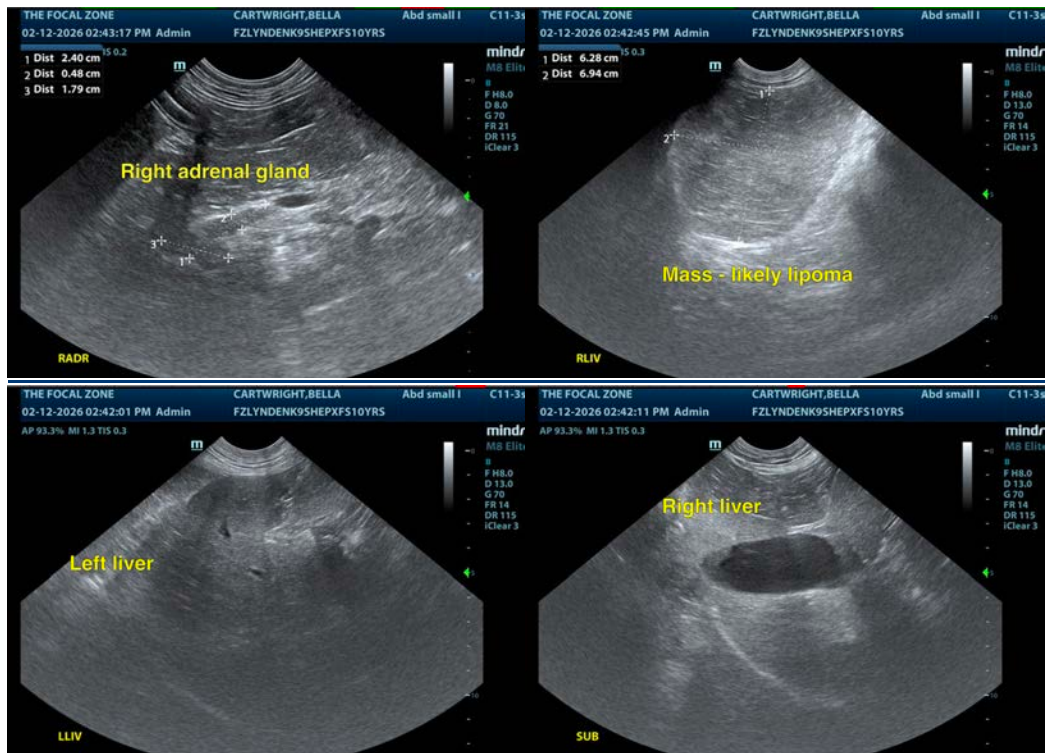
No masses visualized associated with intrabdominal organs.

ULTRASONOGRAPHIC FINDINGS

- The mass of concern has echogenicity most consistent with a benign lipoma.

INTERPRETATION OF THE FINDINGS & FURTHER RECOMMENDATIONS

FNA is recommended to further define the mass. It does not appear to be adherent to any intraabdominal organs, and a subcutaneous mass is suspected.





PATIENT

Bella Cartwright

SPECIES

Canine

BREED

Shepherd x

SEX

Spayed Female

AGE

10 Years

WEIGHT

28 kg

INTERPRETED BY

Dr Brittany Sinclair,
 BVSc(hons),
 DACVECC

IMAGING PERFORMED BY

Kelly Reschny

HOSPITAL NAME

Lynden Animal Clinic

REFERRING VET

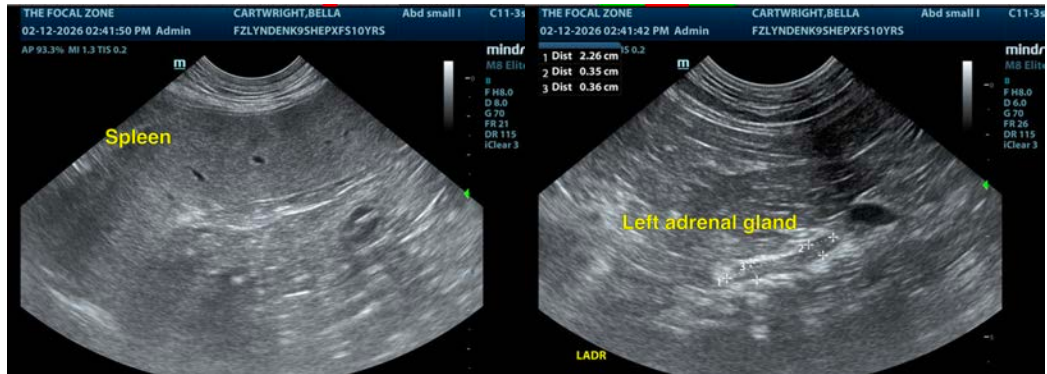
Dr. Collins

INVOICE

72915

DATE

2/12/26



The information and recommendations provided are based on the images presented by the referring veterinarian/sonographer. No evaluation can be communicated regarding pathology that was not visible in the image/video clips provided.

Thank you for this referral. If the clinical or image interpretation does not parallel your findings or if I can be of any further assistance please contact me.

Dr Brittany Sinclair, BVSc(hons), DACVECC

info@SonoPath.com