



PATIENT

Rickey MacDonald

SPECIES

Canine

BREED

Doodle

SEX

Neutered Male

AGE

4 Years

WEIGHT

34 kg

INTERPRETED BY

Dr Brittany Sinclair,
 BVSc(hons),
 DACVECC

IMAGING PERFORMED BY

Amanda Stewart

HOSPITAL NAME

Headon Forest

REFERRING VET

Dr. Martin

INVOICE

72344

DATE

12/5/25

PRESENTING CLINICAL SIGNS

HW positive since November 20th - no microfilaria seen vomiting daily the past 4 days, eating and drinking well but P is lethargic Current Medications Aventi Omega 3

Abnormal PE/Chem/CBC/UA Results: See attached lab results Primary Question to Be Answered in This Exam to evaluate the heart and abdomen

ULTRASONOGRAPHIC EXAMINATION OF THE ABDOMEN

Urinary System

The urinary bladder, trigone, and visible pelvic urethra were of normal thickness. The ureters were not visible which is normal. There was normal wall layering with no masses, uroliths or abnormal thickening visualized. Urine was anechoic. No evidence of inflammatory or neoplastic changes were noted.

The kidneys were both normal size and structure, with smooth capsule and normal corticomedullary definition and ratio. Medullary structure differed distinctly from that of the cortex. No evidence of pelvic dilation was present. Left kidney measured 6.68 cm in length. Right kidney measured 6.76 cm in length.

Adrenal Glands

Both adrenal glands were visualized and recognized as having normal shape, size, position and echogenicity for this breed and age. The visible phrenic vasculature was unremarkable. Left adrenal gland measures 2.82 cm in length x 0.56 cm at the caudal pole and 0.36 cm at the cranial pole. Right adrenal gland measures 2.36 cm in length x 0.68 cm at the caudal pole and 0.99 cm at the cranial pole.

Spleen

The spleen was normal with age appropriate homogeneous parenchyma and a smooth capsule with normal splenic vasculature with no signs of congestion or thrombosis. No sonographic evidence of acute or chronic inflammatory, neoplastic, or infarct changes were noted.

Liver

The liver is subjectively normal in size with normal contours and structure. There is age appropriate echogenicity and echotexture. No overt structural evidence of inflammatory, infiltrative or regenerative pathology is evident. Vascular and biliary tracts are of normal volume with no evidence of congestion.

Gall bladder is moderately distended with normal wall thickness and anechoic contents. Common bile duct is non-distended and tapers normally.

Gastrointestinal

The stomach contains minimal luminal contents. It measures at a normal thickness of with some variability due to the presence of rugal folds. The distinction of the gastric wall layers is adequate. No masses or focal lesions were observed.

The visualized areas of duodenum, jejunum and ileum have a relatively uniform diameter with minimal fluid distension. Wall thickness is normal. Bowel loops follow a curvilinear path with distinct wall layering maintaining the typical 1:3 muscularis:mucosa layer ratio. There were no focal lesions consistent with obstruction or a mass effect observed.



PATIENT

Rickey MacDonald

Sections of colon are visualized with formed fecal material and gas shadowing distally. There is no observed focal or generalized colon wall thickening or loss of layering.

Pancreas

SPECIES

Canine

The visible pancreas was observed to be largely isoechoic to surrounding omental fat.

Lymph Nodes

BREED

Doodle

No clinically significant lymphadenopathy or abnormalities noted.

Free Abdomen

SEX

Neutered Male

No masses or free fluid were noted.

ULTRASONOGRAPHIC FINDINGS

- Unremarkable abdomen.

AGE

4 Years

INTERPRETATION OF THE FINDINGS & FURTHER RECOMMENDATIONS

WEIGHT

34 kg

There is no ultrasonographically evident cause of reported GI signs in this abdominal study. Pancreas and GI tract are within normal limits. Consideration for dietary indiscretion, infectious etiologies (bacterial, viral, parasitic), food sensitivity/allergy or mild inflammatory bowel disease is reasonable. While not sonographically evident, pancreatitis cannot be completely ruled out. Empiric treatment for GI signs including anti-nausea, appetite stimulant and fluid support as clinically indicated is warranted. A diet trial with hydrolyzed protein or select protein diet could be considered if food sensitivity is suspected clinically. If signs are persistent or recurrent, additional diagnostics to be considered include baseline cortisol +/- ACTH stimulation test, GI panel (TLI/PLI/cobalamin/folate), fecal pathogen panel, thyroid testing, bile acid profile, and thoracic radiographs to rule out occult neoplasia, cardiac disease and esophageal disease as potential causes. Ultimately GI biopsy may be required for more definitive diagnosis if the patient is not responsive to medical treatment.

INTERPRETED BY

Dr Brittany Sinclair,
BVSc(hons),
DACVECC

IMAGING PERFORMED BY

Amanda Stewart

HOSPITAL NAME

Headon Forest

REFERRING VET

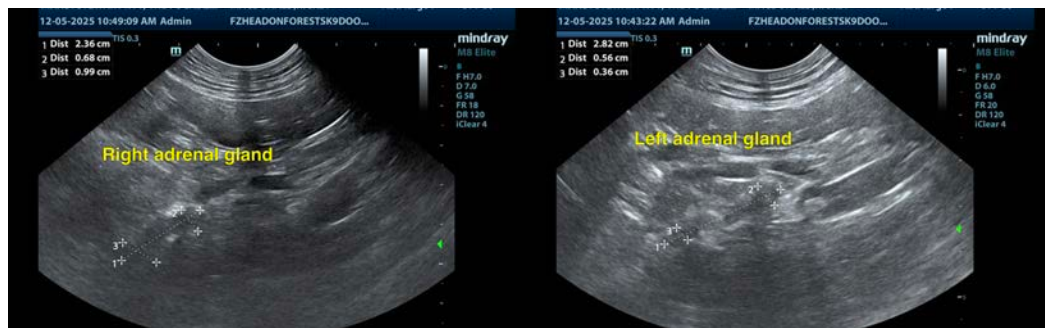
Dr. Martin

INVOICE

72344

DATE

12/5/25





PATIENT

Rickey MacDonald

SPECIES

Canine

BREED

Doodle

SEX

Neutered Male

AGE

4 Years

WEIGHT

34 kg

INTERPRETED BY

Dr Brittany Sinclair,
 BVSc(hons),
 DACVECC

IMAGING PERFORMED BY

Amanda Stewart

HOSPITAL NAME

Headon Forest

REFERRING VET

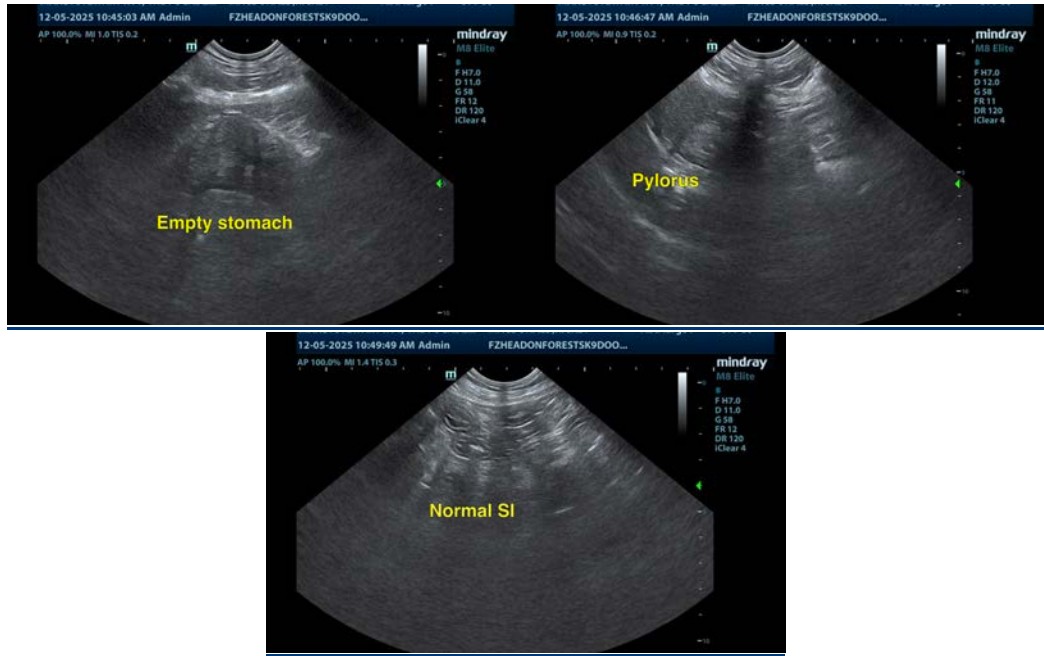
Dr. Martin

INVOICE

72344

DATE

12/5/25



The information and recommendations provided are based on the images presented by the referring veterinarian/sonographer. No evaluation can be communicated regarding pathology that was not visible in the image/video clips provided.

Thank you for this referral. If the clinical or image interpretation does not parallel your findings or if I can be of any further assistance please contact me.

Dr Brittany Sinclair, BVSc(hons), DACVECC

info@SonoPath.com