



PATIENT

Katie Murphy

SPECIES

Canine

BREED

Hound Mix

SEX

Spayed Female

AGE

4 Years

WEIGHT

69 Pounds

INTERPRETED BY

Dr Brittany Sinclair,
BVSc(hons), DACVECC

IMAGING PERFORMED BY

Meghan Morse, LVT,
CVT

HOSPITAL NAME

New Bridge VH

REFERRING VET

Dr. Glennon

INVOICE

35133

DATE

12/30/25

PRESENTING CLINICAL SIGNS

History: Increased BUN and Creat. Wt loss. Anorexia. O has been giving aspirin to dog to help with pain.

Abnormal PE/Chem/CBC/UA Results: CBC WNL CHEM: SDMA 25, Creat 8.4, BUN 130, Cystatin B 1171, Phosphorus 17.4, Calcium 13.8, Anion Gap 32, AMylase 1542 U/A: USG 1.012, protein 3+

ULTRASONOGRAPHIC EXAMINATION OF THE ABDOMEN

Urinary System

The urinary bladder, trigone, and visible pelvic urethra were of normal thickness. The ureters were not visible which is normal. There was normal wall layering with no masses, uroliths or abnormal thickening visualized. Urine was anechoic. No evidence of inflammatory or neoplastic changes was noted.

The kidneys were both normal in size, shape, and position. They have normal corticomedullary distinction. Cortices are bilaterally hyperechoic. The left kidney has a small anechoic fluid accumulation consistent with a small cortical cyst. The right kidney measured 6.19 cm in length. The left kidney measured 6.26 cm in length.

Adrenal Glands

Both adrenal glands were visualized and recognized as having normal shape, size, position and echogenicity for this breed. The phrenic vasculature, glandular echogenicity and detail were unremarkable. Capsule, cortex, and medullary definition were normal for this age patient. The left adrenal gland measured 2.27 cm in length and 0.47 cm at the cranial pole and 0.47 cm at the caudal pole. The right adrenal gland measured 2.02 cm in length and 0.99 cm at the cranial pole and 0.55 cm at the caudal pole. Resolution was somewhat limited.

Spleen

The spleen was normal with a smooth homogeneous parenchyma hyperechoic to liver and renal cortical parenchyma and smooth capsule, with normal splenic vasculature with no signs of congestion or thrombosis. No sonographic evidence of acute or chronic inflammatory, neoplastic, or infarct changes were noted.

Liver

The liver is subjectively normal in size with normal contours and structure. There are appropriate echogenicity and echotexture. No overt structural evidence of inflammatory, infiltrative or regenerative pathology is evident. Vascular and biliary tracts are of normal volume with no evidence of congestion. No pathological hepatic lymphadenopathy observed. Gallbladder is moderately distended with normal wall thickness and anechoic contents. Common bile duct is non-distended and tapers normally.

Gastrointestinal

The stomach contains minimal luminal contents. It measures at a normal thickness with some variability due to the presence of rugal folds. The distinction of the gastric wall layers is adequate and there is no impression of reduced peristaltic activity. No masses or focal lesions were observed.



PATIENT

Katie Murphy

SPECIES

Canine

BREED

Hound Mix

SEX

Spayed Female

AGE

4 Years

WEIGHT

69 Pounds

INTERPRETED BY

Dr Brittany Sinclair,
BVSc(hons), DACVECC

IMAGING PERFORMED BY

Meghan Morse, LVT,
CVT

HOSPITAL NAME

New Bridge VH

REFERRING VET

Dr. Glennon

INVOICE

35133

DATE

12/30/25

The visualized areas of duodenum, jejunum and ileum have a relatively uniform diameter with minimal fluid distension. Wall thickness is normal. Bowel loops follow a curvilinear path with distinct wall layering maintaining the typical 1:3 muscularis: mucosa layer ratio. Visualized peristalsis appears appropriate. There were no focal lesions consistent with obstruction or a mass effect observed.

Sections of colon are visualized with formed fecal material and gas shadowing distally. There is no observed focal or generalized colon wall thickening or loss of layering.

Pancreas

The area of the pancreas was isoechoic to surrounding tissue with no overt inflammation. Pancreatic tissue was not distinctly visualized which is common.

Lymph Nodes

No clinically significant lymphadenopathy or abnormalities noted.

ULTRASONOGRAPHIC FINDINGS

- Hyperechoic renal cortices bilaterally
- Small left renal cyst- likely incidental

INTERPRETATION OF THE FINDINGS & FURTHER RECOMMENDATIONS

Kidneys bilaterally show signs of nephritis with hyperechoic cortices. No definitive cause is visible on ultrasound. In light of the azotemia, an acute renal insult is likely. Progression of early onset renal degeneration, toxin exposure, leptospirosis, bacterial pyelonephritis, other infectious insults, recently resolved ureterolithiasis, among other things are possible. Hypoadrenocorticism should be screened for given the severity of azotemia.

Additional diagnostics to be considered include baseline cortisol +/- ACTH stimulation test, urine culture (even if no bacteria on UA), leptospirosis testing, and careful questioning for the possibility of exposure to renal toxins (NSAIDs, grapes/raisins, cream of tartar, tamarind, vitamin D, rodenticide, etc.). Doppler blood pressure measurement is recommended to screen for hypertension which can be present in both acute and chronic renal disease and worsens renal function.

Treatment with intravenous fluid therapy, GI support as needed including enteral nutrition and monitoring for improvement or resolution of azotemia every 24-48 hours is recommended. Antibiotics are reasonable while awaiting infectious disease testing.

If azotemia fails to resolve with fluid therapy, permanent renal dysfunction is likely. Management for any patient with chronic renal dysfunction includes renal specific diet (protein and phosphorus limited), encouraging increased water intake with canned food and providing clean, running water source, and management of proteinuria and hypertension with ACE-inhibitor with addition of more anti-hypertensives as required. Monitoring of bloodwork, urinalysis and blood pressure every 3-6 months, or sooner if feeling unwell, is recommended.



PATIENT

Katie Murphy

SPECIES

Canine

BREED

Hound Mix

SEX

Spayed Female

AGE

4 Years

WEIGHT

69 Pounds

INTERPRETED BY

Dr Brittany Sinclair,
 BVSc(hons), DACVECC

IMAGING PERFORMED BY

Meghan Morse, LVT,
 CVT

HOSPITAL NAME

New Bridge VH

REFERRING VET

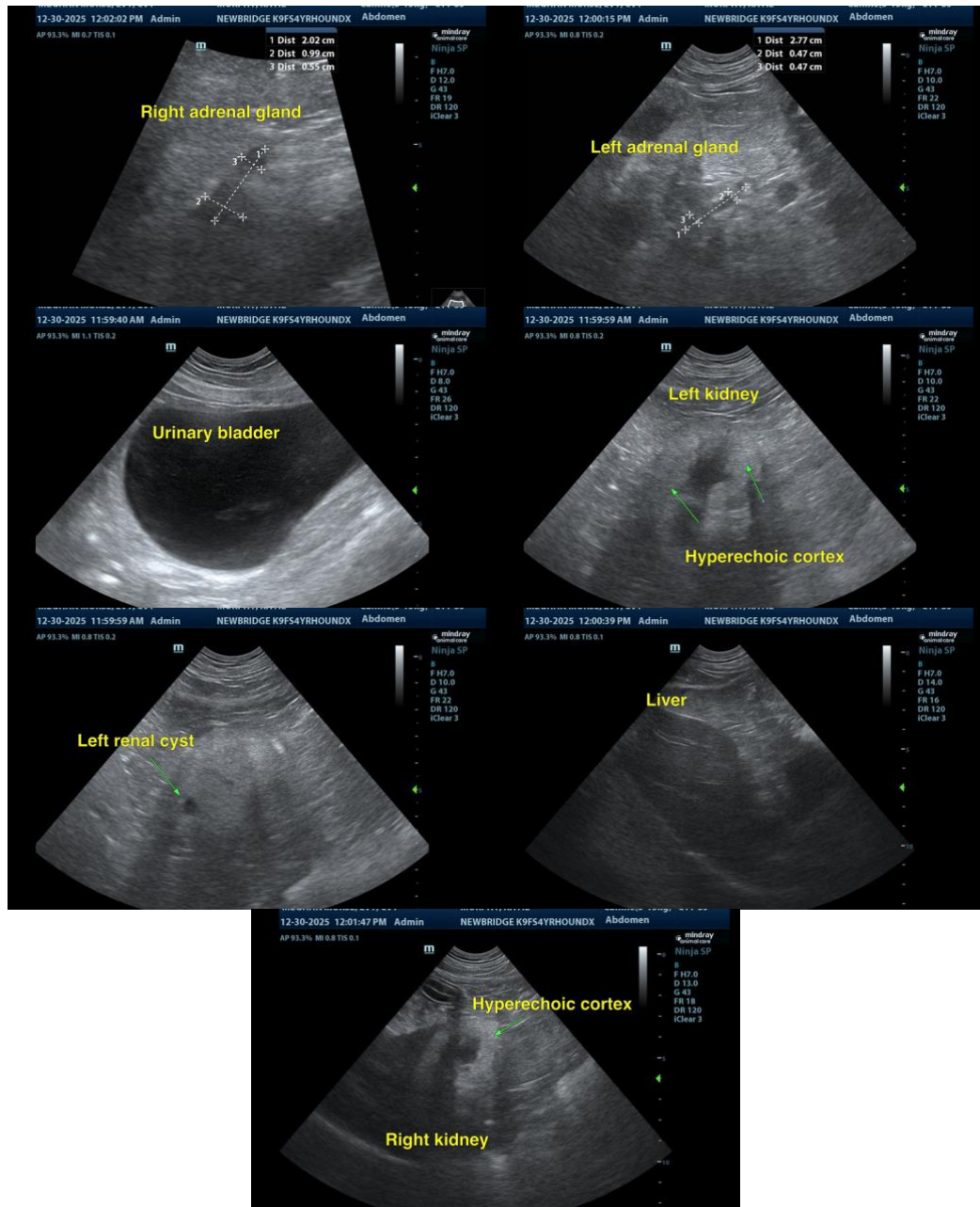
Dr. Glennon

INVOICE

35133

DATE

12/30/25





PATIENT

Katie Murphy

SPECIES

Canine

BREED

Hound Mix

SEX

Spayed Female

AGE

4 Years

WEIGHT

69 Pounds

INTERPRETED BY

Dr Brittany Sinclair,
BVSc(hons), DACVECC

**IMAGING
PERFORMED BY**

Meghan Morse, LVT,
CVT

HOSPITAL NAME

New Bridge VH

REFERRING VET

Dr. Glennon

INVOICE

35133

DATE

12/30/25

The information and recommendations provided are based on the images presented by the referring veterinarian/sonographer. No evaluation can be communicated regarding pathology that was not visible in the image/video clips provided.

Thank you for this referral. If the clinical or image interpretation does not parallel your findings or if I can be of any further assistance please contact me.

Dr Brittany Sinclair, BVSc(hons), DACVECC

info@SonoPath.com