

Clinical Sonography & Telecytology
Educational Teleconsultation Services™

PATIENT
Steeler Marabondo

SPECIES
Canine

BREED
Weimaraner

SEX
Neutered Male

AGE
6 Years 6 Months

WEIGHT
67 lbs

INTERPRETED BY
Dr Brittany Sinclair, BVSc(hons), DACVECC

IMAGING PERFORMED BY
Kerri Beccker

HOSPITAL NAME
All Creatures Great & Small Denville

REFERRING VET
Dr. Ashmore

INVOICE
72239

DATE
12/2/25

PRESENTING CLINICAL SIGNS

HX of IGA IBD, Elev. Kidney values. BAR NSF Meds- pred, tylan powder, azodyl, RC renal diet, bayrtil.

Abnormal PE/Chem/CBC/UA Results: BUN-50 crea-2.9 sdma-24.6 phos-6.8 alt-143 alp-904 alb-2.6 UA wbc-21-50 rbc-11-20 USG-1.018

ULTRASONOGRAPHIC EXAMINATION OF THE ABDOMEN

Urinary System

The urinary bladder, trigone, and visible pelvic urethra were of normal thickness. The ureters were not visible which is normal. There was normal wall layering with no masses, uroliths or abnormal thickening visualized. Urine was anechoic. No evidence of inflammatory or neoplastic changes were noted.

The kidneys have a smooth capsule and with complete loss of corticomedullary definition. Both renal pelvises are mildly dilated. Hyperechoic, shadowing foci present in left and right renal parenchyma and calyces consistent with nephrocalcinosis. Left kidney measured 6.31 cm. Right kidney measured 5.76 cm.

The prostate is not visible.

Adrenal Glands

Adrenal glands were visualized on still images only. They appear to have normal shape, size, position and echogenicity for this breed and age though this could not be confirmed on cine loops. Left measures 2.74 cm in length x 0.54 cm at the caudal pole and 0.53 cm at the cranial pole. Right measures 1.95 cm in length x 1.11 cm at the cranial pole and 0.47 cm at the caudal pole.

Spleen

The spleen was normal with age appropriate homogeneous parenchyma and a smooth capsule with normal splenic vasculature with no signs of congestion or thrombosis. No sonographic evidence of acute or chronic inflammatory, neoplastic, or infarct changes were noted.

Liver

The liver is subjectively normal in size with normal contours and structure. There is age appropriate echogenicity and echotexture. No overt structural evidence of inflammatory, infiltrative or regenerative pathology is evident. Vascular and biliary tracts are of normal volume with no evidence of congestion.

The gall bladder is moderately distended with anechoic fluid, with hyperechoic , partially organized non-shadowing debris present. There is no surrounding free fluid or signs of active inflammation.

Gastrointestinal

The stomach contains minimal luminal contents. It measures at a normal thickness of with some variability due to the presence of rugal folds. The distinction of the gastric wall layers is adequate. No masses or focal lesions were observed.

The visualized areas of duodenum, jejunum and ileum have a relatively uniform diameter with minimal fluid distension. Wall thickness is normal. Bowel loops follow a curvilinear path with distinct wall layering maintaining the typical 1:3 muscularis:mucosa layer ratio. There were no focal lesions consistent with obstruction or a mass effect observed.

PATIENT
Steeler Marabondo

SPECIES
Canine

BREED
Weimaraner

SEX
Neutered Male

AGE
6 Years 6 Months

WEIGHT
67 lbs

INTERPRETED BY
Dr Brittany Sinclair, BVSc(hons), DACVECC

IMAGING PERFORMED BY
Kerri Beccker

HOSPITAL NAME
All Creatures Great & Small Denville

REFERRING VET
Dr. Ashmore

INVOICE
72239

DATE
12/2/25

Sections of colon are visualized with formed fecal material and gas shadowing distally. There is no observed focal or generalized colon wall thickening or loss of layering.

Pancreas

The area of the pancreas was isoechoic to surrounding tissue with no overt inflammation. Pancreatic tissue was not distinctly visualized which is common.

Lymph Nodes

No clinically significant lymphadenopathy or abnormalities noted.

Free Abdomen

No masses or free fluid were noted.

ULTRASONOGRAPHIC FINDINGS

- Significant degenerative renal changes with nephrocalcinosis.
- Gallbladder debris.

INTERPRETATION OF THE FINDINGS & FURTHER RECOMMENDATIONS

The degenerative renal changes are very pronounced for a patient of this age. This may represent early onset age related renal degeneration and early renal insult with subsequent early progression of degeneration or congenital renal dysplasia, though the latter is less likely based on the appearance. Ultimately, renal biopsy may be necessary to further differentiate, though this is not generally done. Progression of chronic renal disease, toxin exposure, leptospirosis, bacterial pyelonephritis, other infectious insults, recently resolved ureterolithiasis, among other things are all possibilities.

Additional diagnostics to be considered include urine culture (even if no bacteria on UA), leptospirosis testing, and careful questioning for the possibility of exposure to renal toxins (NSAIDs, grapes/raisins, cream of tartar, tamarind, vitamin D, rodenticide, etc). Doppler blood pressure measurement is recommended to screen for hypertension which can be present in both acute and chronic renal disease and worsens renal function.

Treatment with intravenous fluid therapy, GI support as needed including enteral nutrition and monitoring for stabilization or resolution of azotemia every 24-48 hours is recommended. Antibiotics are reasonable while awaiting infectious disease testing.

Management for any patient with chronic renal dysfunction includes renal specific diet (protein and phosphorus limited), encouraging increased water intake with canned food and providing clean, running water source, and management of proteinuria and hypertension with ACE-inhibitor with addition of more anti-hypertensives as required. Monitoring of bloodwork, urinalysis and blood pressure every 3-6 months, or sooner if feeling unwell, is recommended.

Gall bladder debris may be an incidental finding given lack of surrounding inflammation. In the face of elevated ALKP ursodiol could be given as a choleretic and empiric treatments (SAM-E, milk thistle, Vitamin E) could be tried. If liver supportive medications do not improve liver enzymes, a course of empiric antibiotics (clavamox, enrofloxacin) could be considered to cover for infectious cholangiohepatitis, though the lack of surrounding inflammation makes this less likely. Imaging should be rechecked on a routine basis for monitoring (q3-6mo) or if further significant increase in liver enzymes and/or new clinical signs are noted. If otherwise clinically indicated, investigation for

PATIENT

Steeler Marabondo

SPECIES

Canine

BREED

Weimaraner

SEX

Neutered Male

AGE

6 Years 6 Months

WEIGHT

67 lbs

INTERPRETED BY

Dr Brittany Sinclair, BVSc(hons), DACVECC

IMAGING PERFORMED BY

Kerri Beccker

HOSPITAL NAME

All Creatures Great & Small Denville

REFERRING VET

Dr. Ashmore

INVOICE

72239

DATE

12/2/25

endocrinopathy such as hyperadrenocorticism or hypothyroidism could be considered as an underlying cause predisposing to gall bladder debris accumulation.

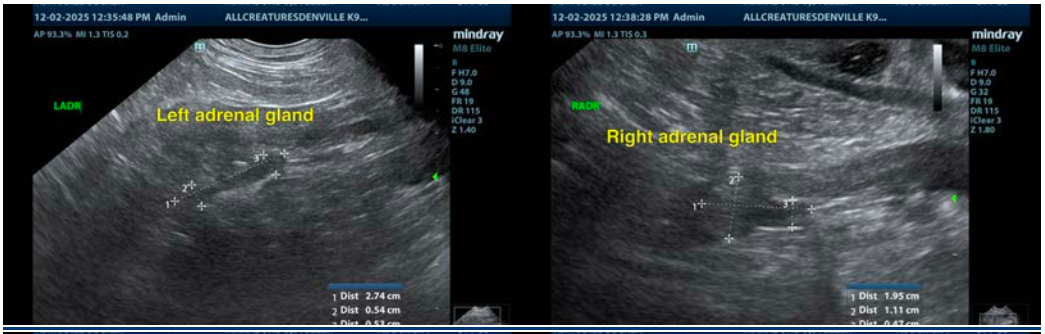

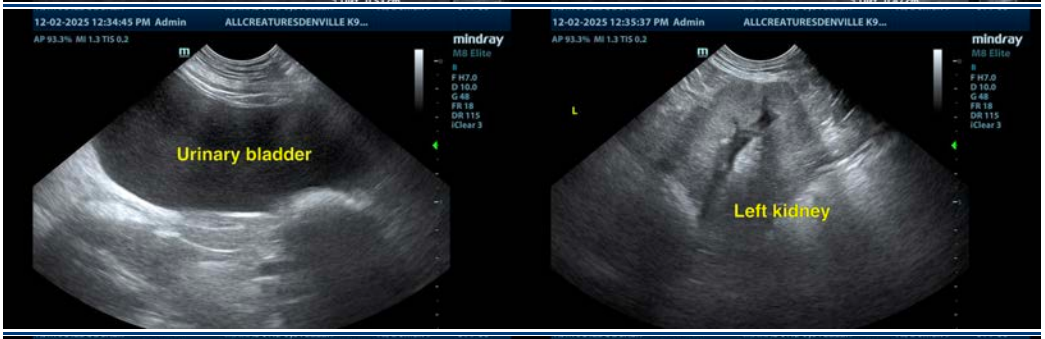



PATIENT

Steeler Marabondo

SPECIES

Canine

BREED

Weimaraner

SEX

Neutered Male

AGE

6 Years 6 Months

WEIGHT

67 lbs

INTERPRETED BY

Dr Brittany Sinclair, BVSc(hons), DACVECC

IMAGING PERFORMED BY

Kerri Beccker

HOSPITAL NAME

All Creatures Great & Small Denville

REFERRING VET

Dr. Ashmore

INVOICE

72239

DATE

12/2/25

The information and recommendations provided are based on the images presented by the referring veterinarian/sonographer. No evaluation can be communicated regarding pathology that was not visible in the image/video clips provided.

Thank you for this referral. If the clinical or image interpretation does not parallel your findings or if I can be of any further assistance please contact me.

Dr Brittany Sinclair, BVSc(hons), DACVECC

info@SonoPath.com