



PATIENT

Squeaky Moses King

SPECIES

Feline

BREED

DSH

SEX

Neutered Male

AGE

14 Years

WEIGHT

10 pounds

INTERPRETED BY

Dr Brittany Sinclair,
 BVSc(hons), DACVECC

IMAGING PERFORMED BY

Kelly Reschny

HOSPITAL NAME

Village Cat Clinic

REFERRING VET

Dr. Maxwell

INVOICE

12727

DATE

12/18/25

PRESENTING CLINICAL SIGNS

Anorexia past few days

ULTRASONOGRAPHIC EXAMINATION OF THE ABDOMEN

Urinary System

The urinary bladder, trigone, and visible pelvic urethra were of normal thickness. The ureters were not visible which is normal. There was normal wall layering with no masses, uroliths or abnormal thickening visualized. Urine was anechoic. No evidence of inflammatory or neoplastic changes were noted.

The kidneys were both normal size and structure, with smooth capsule and normal corticomedullary definition and ratio (cortex 1/3 of medulla). Medullary structure differed distinctly from that of the cortex. No evidence of pelvic dilation was present. The right kidney measured 4.07 cm in length. The left kidney measured 4.47 cm in length.

Adrenal Glands

Both adrenal glands were visualized and recognized as having normal shape, size, position and echogenicity for this breed. The phrenic vasculature, glandular echogenicity and detail were unremarkable. Capsule, cortex, and medullary definition were normal for this age patient. The left adrenal gland measured 0.36 cm in thickness. The right adrenal gland measured 0.31 cm in thickness.

Spleen

The spleen was normal with a smooth homogeneous parenchyma hyperechoic to liver and renal cortical parenchyma and smooth capsule, with normal splenic vasculature with no signs of congestion or thrombosis. No sonographic evidence of acute or chronic inflammatory, neoplastic, or infarct changes were noted.

Liver

The liver is subjectively normal in size with normal contours and structure. There is appropriate echogenicity and echotexture. No overt structural evidence of inflammatory, infiltrative or regenerative pathology is evident. Vascular and biliary tracts are of normal volume with no evidence of congestion. No pathological hepatic lymphadenopathy observed. Gallbladder is moderately distended with normal wall thickness and anechoic contents. Common bile duct is non-distended and tapers normally.

Gastrointestinal

The stomach contains gas shadowing obstructing full visualization of the contents with no overt distention. It measures at a normal thickness with some variability due to the presence of rugal folds. The distinction of the gastric wall layers is adequate and there is no impression of reduced peristaltic activity. No masses or focal lesions were observed.

The visualized areas of duodenum, jejunum and ileum have a relatively uniform diameter with minimal fluid distension. Wall thickness is normal. Bowel loops follow a curvilinear path with distinct wall layering maintaining the typical 1:3 muscularis: mucosa layer ratio. Visualized peristalsis appears appropriate. There were no focal lesions consistent with obstruction or a mass effect observed.



PATIENT
 Squeaky Moses King

The ileocecal junction was not visualized. Sections of colon are visualized with formed fecal material and gas shadowing distally. There is no observed focal or generalized colon wall thickening or loss of layering.

SPECIES

Pancreas

Feline

The area of the pancreas was isoechoic to surrounding tissue with no overt inflammation. Pancreatic tissue was not distinctly visualized which is common.

BREED

Lymph Nodes

DSH

No clinically significant lymphadenopathy or abnormalities noted.

SEX

ULTRASONOGRAPHIC FINDINGS

Neutered Male

- Unremarkable abdomen.

AGE

INTERPRETATION OF THE FINDINGS & FURTHER RECOMMENDATIONS

14 Years

There is no ultrasonographically evident cause of reported GI signs in this abdominal study. Pancreas and GI tract are within normal limits. Consideration for dietary indiscretion, food sensitivity/allergy or mild inflammatory bowel disease is reasonable. While not sonographically evident, pancreatitis cannot be completely ruled out. Empiric treatment for GI signs including anti-nausea, appetite stimulant and fluid support as clinically indicated is warranted. A diet trial with hydrolyzed protein or select protein diet could be considered if food sensitivity is suspected clinically. If signs are persistent or recurrent, additional diagnostics to be considered include GI panel (TLI/PLI/cobalamin/folate), fecal pathogen panel, thyroid testing, bile acid profile, and thoracic radiographs to rule out occult neoplasia, cardiac disease and esophageal disease as potential causes. Ultimately GI biopsy may be required for more definitive diagnosis if the patient is not responsive to medical treatment.

WEIGHT

10 pounds

INTERPRETED BY

Dr Brittany Sinclair,
 BVSc(hons), DACVECC

IMAGING PERFORMED BY

Kelly Reschny

HOSPITAL NAME

Village Cat Clinic

REFERRING VET

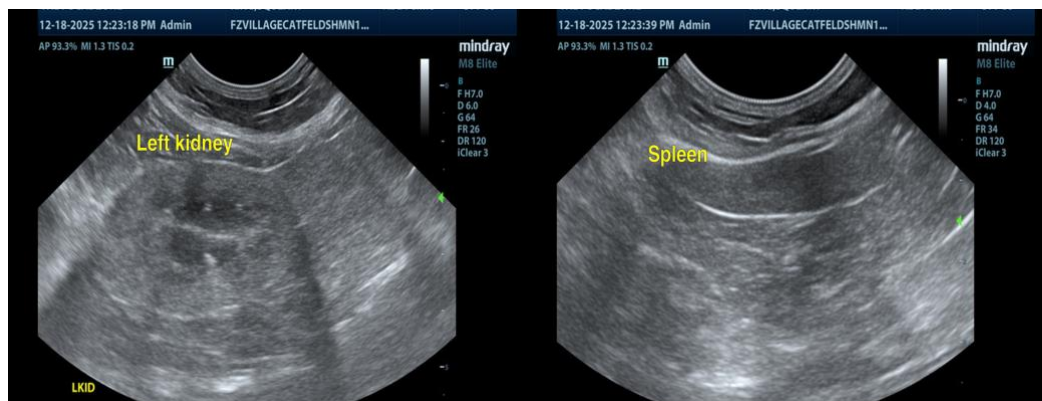
Dr. Maxwell

INVOICE

12727

DATE

12/18/25





PATIENT

Squeaky Moses King

SPECIES

Feline

BREED

DSH

SEX

Neutered Male

AGE

14 Years

WEIGHT

10 pounds

INTERPRETED BY

Dr Brittany Sinclair,
 BVSc(hons), DACVECC

IMAGING PERFORMED BY

Kelly Reschny

HOSPITAL NAME

Village Cat Clinic

REFERRING VET

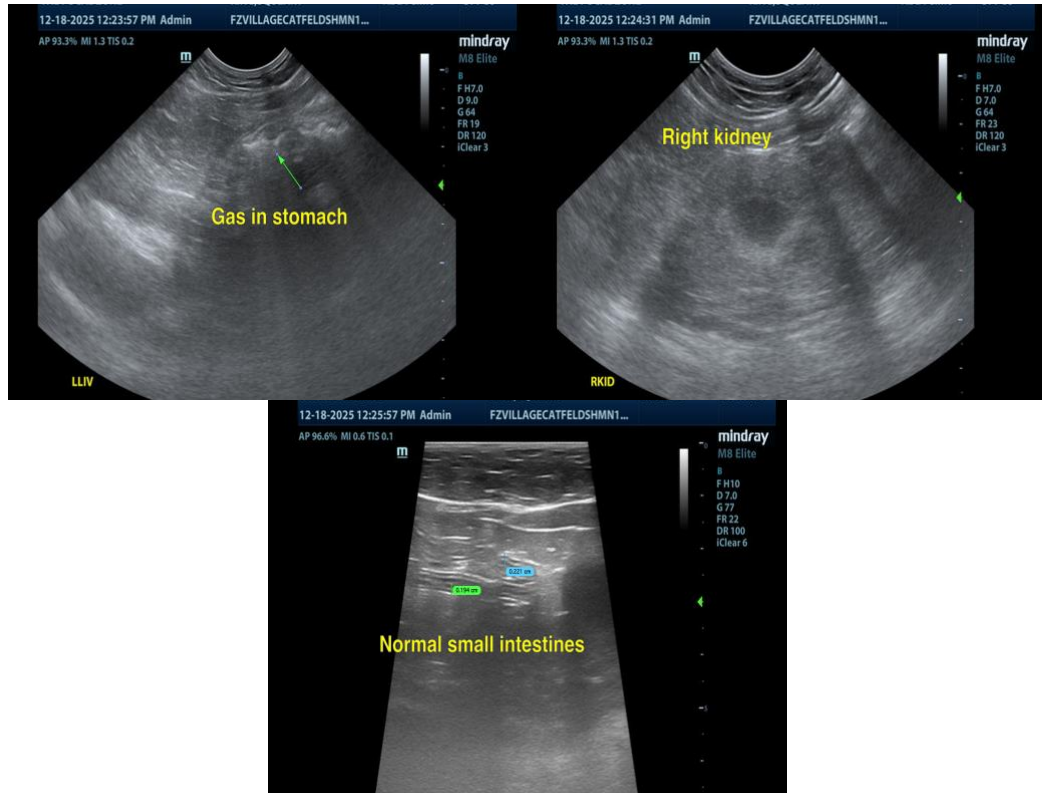
Dr. Maxwell

INVOICE

12727

DATE

12/18/25



The information and recommendations provided are based on the images presented by the referring veterinarian/sonographer. No evaluation can be communicated regarding pathology that was not visible in the image/video clips provided.

Thank you for this referral. If the clinical or image interpretation does not parallel your findings or if I can be of any further assistance, please contact me.

Dr Brittany Sinclair, BVSc(hons), DACVECC

info@SonoPath.com