PATIENT
Stevie Ruthes

SPECIES
Feline

BREED
DLH

SEX
Spayed Female

AGE
10 Years

WEIGHT
5.16 kg

INTERPRETED BY
Dr Brittany Sinclair, BVSc(hons), DACVECC

IMAGING PERFORMED BY
Amanda Stewart

HOSPITAL NAME
Oxford Animal Hospital

REFERRING VET
Dr. Rayala

INVOICE
72484

DATE
12/10/25

PRESENTING CLINICAL SIGNS

Mild erythematic peri anal skin, Anal glands full with thick contents Current Medications convenia injection and cortipro spray.

Abnormal PE/Chem/CBC/UA Results: BE attached Primary Question to Be Answered in This Exam Reason for chronic soft stool

ULTRASONOGRAPHIC EXAMINATION OF THE ABDOMEN

Urinary System

The urinary bladder, trigone, and visible pelvic urethra were of normal thickness. The ureters were not visible which is normal. There was normal wall layering with no masses, uroliths or abnormal thickening visualized. Urine was anechoic. No evidence of inflammatory or neoplastic changes were noted.

The kidneys were both normal size and structure, with smooth capsule and normal corticomedullary definition and ratio. Medullary structure differed distinctly from that of the cortex. No evidence of pelvic dilation was present Left kidney measures 3.9 cm. Right kidney measures 3.89 cm.

Adrenal Glands

Adrenal glands were visualized on still images only. They appear to have normal shape, size, position and echogenicity for this breed and age though this could not be confirmed on cine loops. Left measures 0.28 cm in thickness. Right measures 0.30 cm in thickness.

Spleen

The spleen was normal with age appropriate homogeneous parenchyma and a smooth capsule with normal splenic vasculature with no signs of congestion or thrombosis. No sonographic evidence of acute or chronic inflammatory, neoplastic, or infarct changes were noted.

Liver

The liver is subjectively normal in size with normal contours and structure. There is age appropriate echogenicity and echotexture. No overt structural evidence of inflammatory, infiltrative or regenerative pathology is evident. Vascular and biliary tracts are of normal volume with no evidence of congestion.

Gall bladder is moderately distended with normal wall thickness and anechoic contents. Common bile duct is non-distended and tapers normally.

Gastrointestinal

The stomach contains minimal luminal contents. It measures at a normal thickness of with some variability due to the presence of rugal folds. The distinction of the gastric wall layers is adequate. No masses or focal lesions were observed.

The visualized areas of duodenum, jejunum and ileum have a relatively uniform diameter with minimal fluid distension. Focal loops of jejunum have an increased wall thickness with a prominent muscularis layer. There were no focal lesions consistent with obstruction or a mass effect observed.

Sections of colon are visualized with formed fecal material and gas shadowing distally. There is no observed focal or generalized colon wall thickening or loss of layering.

PATIENT
Stevie Ruthes

SPECIES
Feline

BREED
DLH

SEX
Spayed Female

AGE
10 Years

WEIGHT
5.16 kg

INTERPRETED BY
Dr Brittany Sinclair, BVSc(hons), DACVECC

IMAGING PERFORMED BY
Amanda Stewart

HOSPITAL NAME
Oxford Animal Hospital

REFERRING VET
Dr. Rayala

INVOICE
72484

DATE
12/10/25

Pancreas

The area of the pancreas was isoechoic to surrounding tissue with no overt inflammation. Pancreatic tissue was not distinctly visualized which is common.

Lymph Nodes

No clinically significant lymphadenopathy or abnormalities noted.

Free Abdomen

No masses or free fluid were noted.

ULTRASONOGRAPHIC FINDINGS

- A few focal loops of thickened jejunum with normal wall layering, otherwise normal abdomen.

INTERPRETATION OF THE FINDINGS & FURTHER RECOMMENDATIONS

A few focal loops of jejunum are thickened but maintain normal wall layering with normal mucosa to muscularis ratios. This may represent a variation of normal for this patient or may indicate mild infiltrative disease. Ultrasound cannot differentiate between IBD versus small cell lymphoma, but there are no changes concerning for neoplasia, with changes being very mild with no disruption of normal wall layering and no lymphadenopathy.

There is no definitive cause for the patient's reported chronic soft stool. The colon is sonographically normal. Dietary modification may be of use with consideration for highly digestible GI specific diet such as GI biome. Hydrolyzed or select protein diets may also be considered if patient is non-responsive to GI diet.

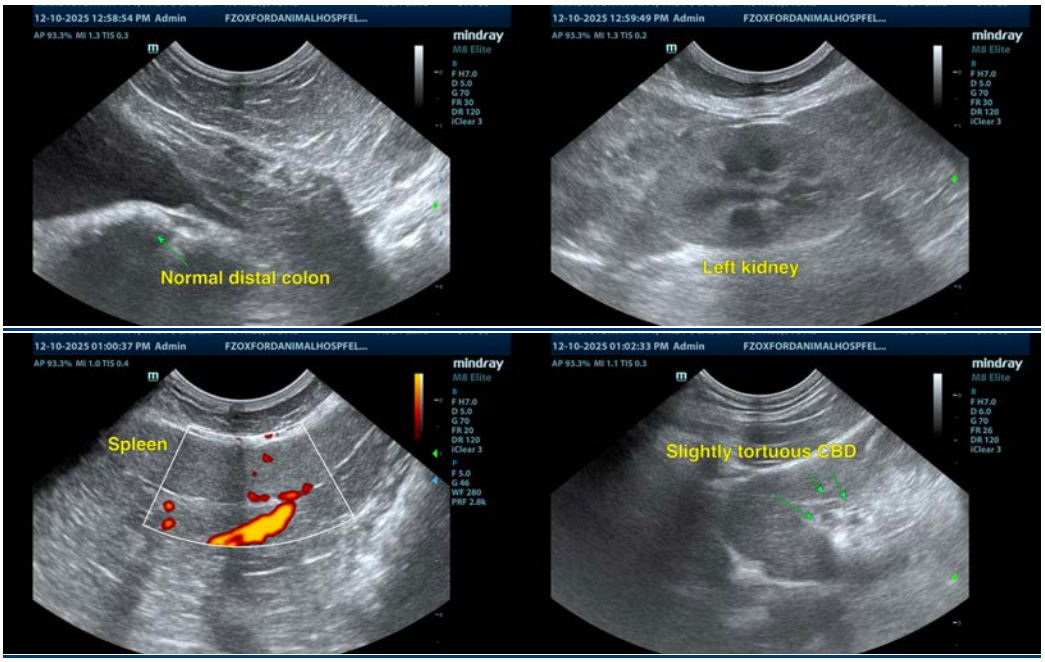

PATIENT

Stevie Ruthes

SPECIES

Feline

BREED

DLH

SEX

Spayed Female

AGE

10 Years

WEIGHT

5.16 kg

INTERPRETED BY

Dr Brittany Sinclair, BVSc(hons), DACVECC

IMAGING PERFORMED BY

Amanda Stewart

HOSPITAL NAME

Oxford Animal Hospital

REFERRING VET

Dr. Rayala

INVOICE

72484

DATE

12/10/25

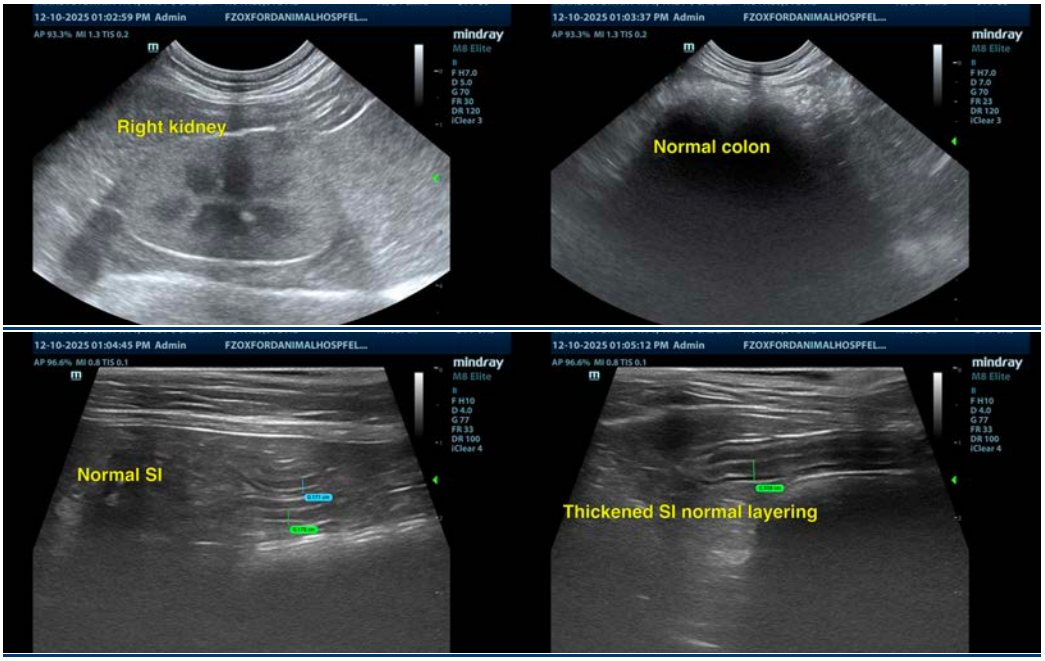

The information and recommendations provided are based on the images presented by the referring veterinarian/sonographer. No evaluation can be communicated regarding pathology that was not visible in the image/video clips provided.

Thank you for this referral. If the clinical or image interpretation does not parallel your findings or if I can be of any further assistance please contact me.

Dr Brittany Sinclair, BVSc(hons), DACVECC

info@SonoPath.com