



PATIENT

Bello Cotto

SPECIES

Feline

BREED

DSH

SEX

Neutered Male

AGE

9 Years

WEIGHT

12.3 Pounds

INTERPRETED BY

Dr Brittany Sinclair,
BVSc(hons),
DACVECC

IMAGING PERFORMED BY

Dr. Gabriel Ferrer,
DVM

HOSPITAL NAME

Pulse Pet Ultrasound
Services

REFERRING VET

Dra. Katherine
Catrinchi

INVOICE

35719

DATE

12/1/25

PRESENTING CLINICAL SIGNS

History: Pt presented as a referral for an abdominal ultrasound to evaluate significant weight loss and increased appetite. In one year, pt went from 17lbs down to 11.8lbs, however wants to eat constantly and is always looking for food. Pt has also has hx of vomiting for a couple years (bili, digested/undigested food). Water intake is normal. T4 test was performed by rDVM using Bionote and came back normal. Abnormal PE/Chem/CBC/UA Results: Bloodwork and radiographs attached as supporting documents.

ULTRASONOGRAPHIC EXAMINATION OF THE ABDOMEN

Urinary System

The urinary bladder, trigone, and visible pelvic urethra were of normal thickness. The ureters were not visible which is normal. There was normal wall layering with no masses, uroliths or abnormal thickening visualized. Urine was anechoic. No evidence of inflammatory or neoplastic changes was noted.

The kidneys were both normal size and structure, with smooth capsule and normal corticomedullary definition and ratio (cortex 1/3 of medulla). Medullary structure differed distinctly from that of the cortex. No evidence of pelvic dilation was present. The right kidney measured 3.91 cm in length. The left kidney measured 3.74 cm in length.

Adrenal Glands

Both adrenal glands were visualized and recognized as having normal shape, size, position and echogenicity for this breed. The phrenic vasculature, glandular echogenicity and detail were unremarkable. Capsule, cortex, and medullary definition were normal for this age patient. The left adrenal gland measured 0.31 cm in thickness. The right adrenal gland measured 0.42 cm in thickness.

Spleen

The spleen was normal with a smooth homogeneous parenchyma hyperechoic to liver and renal cortical parenchyma and smooth capsule, with normal splenic vasculature with no signs of congestion or thrombosis. No sonographic evidence of acute or chronic inflammatory, neoplastic, or infarct changes were noted.

Liver

The liver is subjectively normal in size with normal contours and structure. There is appropriate echogenicity and echotexture. No overt structural evidence of inflammatory, infiltrative or regenerative pathology is evident. Vascular and biliary tracts are of normal volume with no evidence of congestion. No pathological hepatic lymphadenopathy observed. Gallbladder is moderately distended with normal wall thickness and anechoic contents. Common bile duct is non-distended and tapers normally.

Gastrointestinal

The stomach contains a small volume of fluid. It measures at a normal thickness with some variability due to the presence of rugal folds. The distinction of the gastric wall layers is adequate and there is no impression of reduced peristaltic activity. No masses or focal lesions were observed.



PATIENT

Bello Cotto

SPECIES

Feline

BREED

DSH

SEX

Neutered Male

AGE

9 Years

WEIGHT

12.3 Pounds

INTERPRETED BY

Dr Brittany Sinclair,
BVSc(hons),
DACVECC

IMAGING PERFORMED BY

Dr. Gabriel Ferrer,
DVM

HOSPITAL NAME

Pulse Pet Ultrasound
Services

REFERRING VET

Dra. Katherine
Catrinchi

INVOICE

35719

DATE

12/1/25

The visualized areas of duodenum, jejunum and ileum have a relatively uniform diameter with minimal fluid distension. Wall is mildly thickened, and wall layering is distinct with a prominent muscularis layer. There were no focal lesions consistent with obstruction or a mass effect observed.

The ileocecal junction was visualized and exhibited normal intact wall layering and is subjectively of normal thickness. Sections of colon are visualized with formed fecal material and gas shadowing distally. There is no observed focal or generalized colon wall thickening or loss of layering.

Pancreas

The base and limbs of the pancreas were observed to be largely isoechoic to surrounding omental fat. Pancreatic duct and capsular contour and parenchyma were normal. No overt evidence of active inflammatory or neoplastic disease was noted.

Lymph Nodes

No clinically significant lymphadenopathy or abnormalities noted.

ULTRASONOGRAPHIC FINDINGS

- Mildly thickened small intestines with diffusely prominent muscularis layer

INTERPRETATION OF THE FINDINGS & FURTHER RECOMMENDATIONS

Small intestinal changes are most consistent with infiltrative disease of the small intestine with inflammatory bowel disease or GI lymphoma being the top differentials. No overt neoplastic criteria present in the bowel given that curvilinear layering is still intact. Ultrasound cannot differentiate between small cell lymphoma and inflammatory bowel disease, and GI biopsies are recommended for definitive diagnosis, especially if there is a poor response to empirical efforts or recurrence of clinical signs after initial control. Endoscopic biopsy is less invasive but may miss lesions due to inability to obtain samples from all sections of the GI tract, especially the jejunum which is the most common site of development of disease. Surgical biopsies are more likely to be diagnostic but are more invasive. A GI panel (PLI/cobalamin/folate) will help determine the severity of SI dysfunction, and need for vitamin supplementation.

Empiric treatment for IBD includes diet trial with either hydrolyzed or select protein diet, vitamin b-12 supplementation, GI support as needed (anti-nausea, appetite stimulant). Treatment with steroids (budesonide vs prednisolone) is often required – biopsies should be acquired prior to treatment with steroids. Steroids may ultimately be tapered to the lowest effective dose or discontinued in some cases.



PATIENT

Bello Cotto

SPECIES

Feline

BREED

DSH

SEX

Neutered Male

AGE

9 Years

WEIGHT

12.3 Pounds

INTERPRETED BY

Dr Brittany Sinclair,
BVSc(hons),
DACVECC

IMAGING PERFORMED BY

Dr. Gabriel Ferrer,
DVM

HOSPITAL NAME

Pulse Pet Ultrasound
Services

REFERRING VET

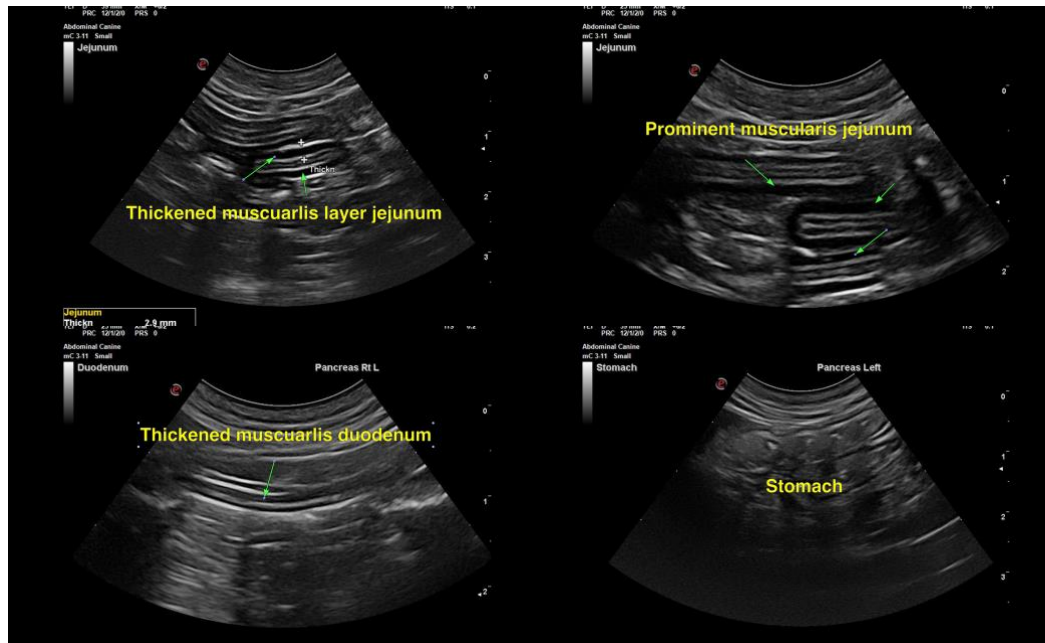
Dra. Katherine
Catrinchi

INVOICE

35719

DATE

12/1/25



The information and recommendations provided are based on the images presented by the referring veterinarian/sonographer. No evaluation can be communicated regarding pathology that was not visible in the image/video clips provided.

Thank you for this referral. If the clinical or image interpretation does not parallel your findings or if I can be of any further assistance please contact me.

Dr Brittany Sinclair, BVSc(hons), DACVECC

info@SonoPath.com