



PATIENT

Thor Nicolucci

SPECIES

Canine

BREED

Doodle

SEX

Neutered Male

AGE

1.5 Years

WEIGHT

17.3 kg

INTERPRETED BY

Dr Brittany Sinclair,
 BVSc(hons),
 DACVECC

IMAGING PERFORMED BY

Kelly Reschny

HOSPITAL NAME

East Credit Veterinary
 Hospital

REFERRING VET

Dr. Jerabek

INVOICE

71648

DATE

11/6/25

PRESENTING CLINICAL SIGNS

Dumpy / anorexic x 2 days No BM x 2 days Vomited twice since Wednesday, last vomit was last night (orangey brown liquid) Not himself. Didn't get into anything that owner was aware of Abdomen soft on palpation. No obvious FB palpable. Disemboweled a stuffy toy on Monday Current Medications Nexgard spectra, Famotidine 0.5mg/kg IV

Abnormal PE/Chem/CBC/UA Results: labs and rads attached

ULTRASONOGRAPHIC EXAMINATION OF THE ABDOMEN

Urinary System

The urinary bladder, trigone, and visible pelvic urethra were of normal thickness. The ureters were not visible which is normal. There was normal wall layering with no masses, uroliths or abnormal thickening visualized. Urine was anechoic. No evidence of inflammatory or neoplastic changes were noted.

The left kidney was both normal size and structure, with smooth capsule and normal corticomedullary definition and ratio. Medullary structure differed distinctly from that of the cortex. No evidence of pelvic dilation was present. Visualization and resolution of the right kidney was severely limited making assessment and measurement inaccurate. This is commonly related to breed related anatomical positioning, and patient compliance. Left kidney measures 5.86 cm. Right kidney measures 5.13 cm.

Adrenal Glands

The left adrenal gland is visualized and recognized as having normal shape, size, position and echogenicity for this breed and age. The visible phrenic vasculature was unremarkable. Left adrenal gland measures 2.31 cm in length x 0.45 cm at the caudal pole and 0.70 cm at the cranial pole.

The right adrenal gland is visualized and measured on still images only. Resolution is inadequate to assess glandular detail or confirm measurement. Right adrenal gland measures 2.13 cm in length x 0.54 cm in thickness.

Spleen

The spleen was normal with age appropriate homogeneous parenchyma and a smooth capsule with normal splenic vasculature with no signs of congestion or thrombosis. No sonographic evidence of acute or chronic inflammatory, neoplastic, or infarct changes were noted.

Liver

The liver is subjectively normal in size with normal contours and structure. There is age appropriate echogenicity and echotexture. No overt structural evidence of inflammatory, infiltrative or regenerative pathology is evident. Vascular and biliary tracts are of normal volume with no evidence of congestion.

Gall bladder is moderately distended with normal wall thickness and anechoic contents. Common bile duct is non-distended and tapers normally.

Gastrointestinal

The stomach contains minimal luminal contents. It measures at a normal thickness of with some variability due to the presence of rugal folds. The distinction of the gastric wall layers is adequate. No masses or focal lesions were observed.



PATIENT

Thor Nicolucci

SPECIES

Canine

BREED

Doodle

SEX

Neutered Male

AGE

1.5 Years

WEIGHT

17.3 kg

INTERPRETED BY

Dr Brittany Sinclair,
BVSc(hons),
DACVECC

IMAGING PERFORMED BY

Kelly Reschny

HOSPITAL NAME

East Credit Veterinary
Hospital

REFERRING VET

Dr. Jerabek

INVOICE

71648

DATE

11/6/25

The visualized areas of duodenum, jejunum and ileum have a relatively uniform diameter with gas throughout with no overt distention. Wall thickness is normal. Bowel loops follow a curvilinear path with distinct wall layering maintaining the typical 1:3 muscularis:mucosa layer ratio. There were no focal lesions consistent with obstruction or a mass effect observed.

The ileocecal junction was not visualized. Sections of colon are visualized with formed fecal material and gas shadowing distally. There is no observed focal or generalized colon wall thickening or loss of layering.

Pancreas

The area of the pancreas was isoechoic to surrounding tissue with no overt inflammation. Pancreatic tissue was not distinctly visualized which is common.

Lymph Nodes

No clinically significant lymphadenopathy or abnormalities noted.

Free Abdomen

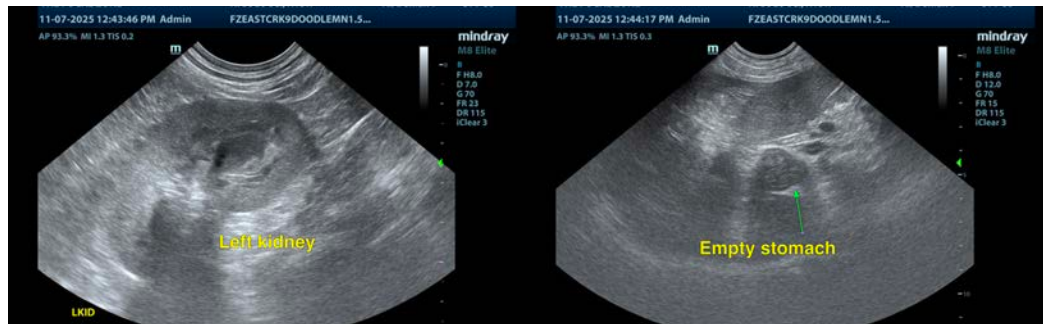No masses or free fluid were noted.

ULTRASONOGRAPHIC FINDINGS

- Gassy small intestinal tract.
- Normal abdomen.

INTERPRETATION OF THE FINDINGS & FURTHER RECOMMENDATIONS

There is no ultrasonographically evident cause of reported GI signs in this abdominal study. Pancreas and GI tract are within normal limits. Consideration for dietary indiscretion, infectious etiologies (bacterial, viral, parasitic), food sensitivity/allergy or mild inflammatory bowel disease is reasonable. While not sonographically evident, pancreatitis cannot be completely ruled out. Empiric treatment for GI signs including anti-nausea, appetite stimulant and fluid support as clinically indicated is warranted. A diet trial with hydrolyzed protein or select protein diet could be considered if food sensitivity is suspected clinically. If signs are persistent or recurrent, additional diagnostics to be considered include baseline cortisol +/- ACTH stimulation test, GI panel (TLI/PLI/cobalamin/folate), fecal pathogen panel, thyroid testing, bile acid profile, and thoracic radiographs to rule out occult neoplasia, cardiac disease and esophageal disease as potential causes. Ultimately GI biopsy may be required for more definitive diagnosis if the patient is not responsive to medical treatment.





PATIENT

Thor Nicolucci

SPECIES

Canine

BREED

Doodle

SEX

Neutered Male

AGE

1.5 Years

WEIGHT

17.3 kg

INTERPRETED BY

Dr Brittany Sinclair,
 BVSc(hons),
 DACVECC

IMAGING PERFORMED BY

Kelly Reschny

HOSPITAL NAME

East Credit Veterinary
 Hospital

REFERRING VET

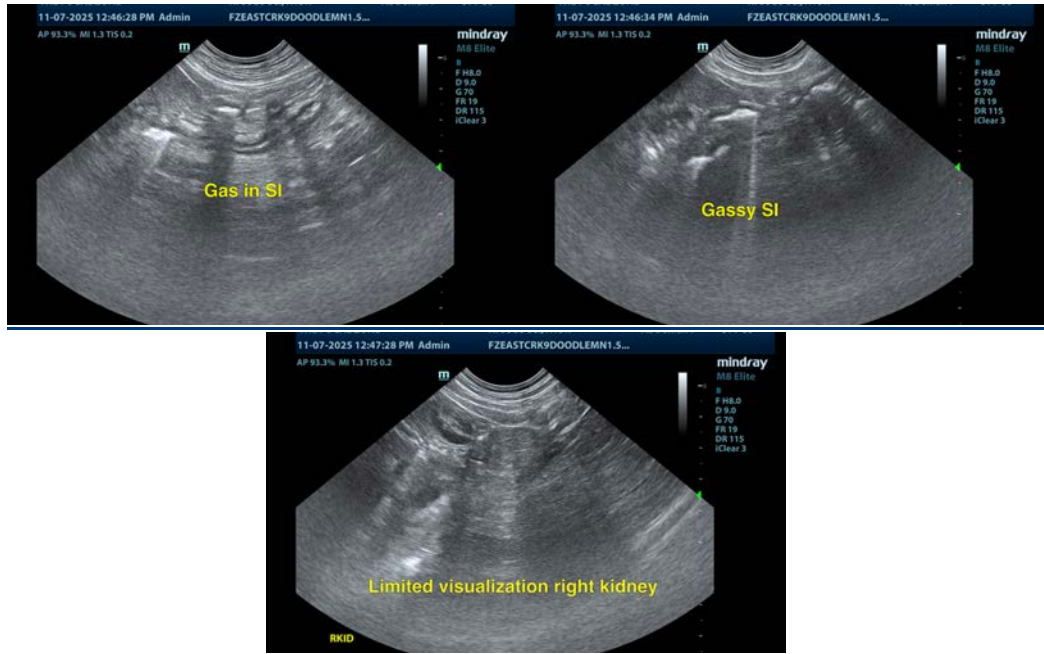
Dr. Jerabek

INVOICE

71648

DATE

11/6/25



The information and recommendations provided are based on the images presented by the referring veterinarian/sonographer. No evaluation can be communicated regarding pathology that was not visible in the image/video clips provided.

Thank you for this referral. If the clinical or image interpretation does not parallel your findings or if I can be of any further assistance please contact me.

Dr Brittany Sinclair, BVSc(hons), DACVECC

info@SonoPath.com